

First Report of the Wild Tibetan Macaque (*Macaca thibetana*) as a New Primate Host of *Gongylonema pulchrum* with High Incidence in China

¹Yong Zhu, ¹Huan Ji, ^{1,2}Jin-Hua Li, ¹Dong-Po Xia, ¹Bing-Hua Sun,
¹Yu-Rui Xu and ³Randall C. Kyes

¹School of Resource and Environmental Engineering, Anhui University, 230601 Hefei, China

²School of Life Science, Anhui Normal University, 241000 Wuhu, China

³Departments of Psychology and Global Health,
Center for Global Field Study and Washington National Primate Research Center,
University of Washington, 98195 Seattle, WA, USA

Abstract: The gullet worm, *Gongylonema pulchrum* Molin, 1857, a genus of nematodes belonging to the Superfamily Spiruroidea is a zoonosis that occurs in the upper digestive tract of various mammals around the world. The hosts of this nematode are only reported in few non-human primates and infestation has not previously been reported in non-human primates in China. Researchers collected 76 fresh fecal samples of Tibetan macaques during Nov. 2009 to Dec. 2009 and March 2010 to April 2010 using washing precipitation and saturated saline flotation method for detection and identification of intestinal parasites in macaques. The incidence of *G. pulchrum* infection was high to 31.58% which was the highest incidence rate among the 9 species intestinal parasites detected in Tibetan macaques. This research provides the first data concerning high incidence of *G. pulchrum* in wild Tibetan macaques in China which means enriched the host of the *G. pulchrum* in non-human primates. The data would serve as a baseline for comparative assessments of disease risks, especially in this well-known ecotourism site at Mt. Huangshan, China.

Key words: Tibetan macaque (*Macaca thibetana*), primate host, *Gongylonema pulchrum*, high incidence, China

INTRODUCTION

The gullet worm, *Gongylonema pulchrum* Molin, 1857, a genus of nematodes belonging to the Superfamily spiruroidea is a zoonosis spirurid nematode that occurs in the upper digestive tract of various mammals around the world (Jelinek and Loscher, 1994; Kudo *et al.*, 2003). The hosts of this worldwide thread-like intestinal parasite are many species of mammals such as cattle, sheep, goats, camels, pigs, equines, cervids, rodents, bears and primates including humans (Anderson, 1992; Sato *et al.*, 2005). The vector and intermediate host for *Gongylonema pulchrum* infections are coprophagous insects (dung beetles and cockroaches) (Anderson, 1992; Kudo *et al.*, 1996).

Gongylonemiasis in ruminants is considered a latent infection and is generally regarded as being nonpathogenic or relatively harmless whereas in primates, the disease seems to have more significant effects on health for example the fatal case in Goeldi's monkeys (*Callimico goeldii*) (Duncan *et al.*, 1995; Brack, 1996). In primates including humans, the parasite preferentially is

localized in the buccal cavity including the lips, gums, tongue and palate causing sometimes serious complaints (Yamashita, 1963; Illescas-Gomez *et al.*, 1988; Sato *et al.*, 2005; Molavi *et al.*, 2006). The infections of *G. pulchrum* have been widespread in humans and countries reporting human infections include the United States (Stiles and Baker, 1928; Eberhard and Busillo, 1999), Europe (Sakovich, 1970), Australia (Kelly, 1974), New Zealand (Jonston, 1936), Spain (Illescas-Gomez *et al.*, 1988), Iran (Molavi *et al.*, 2006), China (Feng *et al.*, 1955; Weng, 1985; Shang, 1985), Japan (Haruki *et al.*, 2005), Southeast Asia (Wilde *et al.*, 2001), among others. When the worms move freely in the esophageal mucosa where this parasite commonly lives, the hosts can cause itching, local irritation in buccal mucosa and worse, expectoration of blood, tarry stools, numbness of tongue, pain in chest and abdomen, vomiting, bloating, pharyngitis and stomatitis (Jelinek and Loscher, 1994; Eberhard and Busillo, 1999; Haruki *et al.*, 2005; Urch *et al.*, 2005).

However, the hosts of this nematode are only found in few non-human primates which only been detected in *Callimico goeldii*, *Callithrix jacchus*, *Cebus capucinus*,

Ateles sp., *Macaca mulatta*, *Macaca fuscata* (Yamashita, 1963; Uni *et al.*, 1992, 1994; Duncan *et al.*, 1995; Brack, 1996). The latest reported on incidence of *G. pulchrum* in non-human primate was detected in Bolivian squirrel monkeys (*Saimiri boliviensis*) colony in a zoological garden in Japan in 2005 (Sato *et al.*, 2005). This infestation has not earlier been reported in non-human primates in China, especially wild ones. As the wild animals are known to be a potential source of human infection in some ecotourism places, researchers investigated the intestinal parasites of wild Tibetan macaques (*Macaca thibetana*) at Mt. Huangshan in China. The aim was to assess the intestinal parasites infection status and further more to detect incidence of *G. pulchrum* in Tibetan macaques.

MATERIALS AND METHODS

Studying site and animals: This study was conducted at the Valley of the Wild Monkeys Mt. Huangshan National Reserve (30°07'09"N, 118°09'41"E; elevation 1,841 m) located in Anhui province, China. The reserve is a UNESCO World Natural and Cultural Heritage site that is well-known as a tourist destination and is home to several groups of Tibetan macaques. Two of these groups are part of an ecotourism program that provides tourists with the opportunity to see the monkeys from human constructed viewing platforms. The matrilineal relationships are known from the history and demographic data collected on a daily basis since 1987. All animals are readily recognized on an individual basis using physical features (i.e., facial/body characteristics) (Li, 1999).

Feces samples and detection: After individuals defecated and left the defecation sites, researchers collected fresh feces and then stored in 10% formalin solution at 4°C. All 76 samples from different individuals were collected during Nov. 2009 to Dec. 2009 and March 2010 to April 2010. The samples were sent to Department of Parasitology in Bengbu Medical College and Department of Parasitology in Anhui Medical University within 1 month after field work. By using washing precipitation and saturated saline flotation method, researchers finished detection and identification of intestinal parasites in macaques.

Washing precipitation: Take 20-30 g stool from the sample and then put into water to make water suspension. Using a metal sieve (40-60 holes) or 2-3 layers of wet gauze filter to rinse the residue. Put filtered liquid manure in the container alone for 25 min and dispose the upper fluid and refill water. Change the water every 15-20 min

once until the top liquid clear up (in a total of 3-4 times). Tossed away the upper fluid finally and sediment taken for smear microscopy.

Saturated saline flotation: Weigh 1 g fecal samples and add a little salt water to mix saturated salt water thoroughly. Add the saturated salt water to 3/4 of tube, place it for 3-4 min and then pick up the crude residue. Add saturated salt water above the micro-nozzle alitter, take a cover slide gently pressed on the surface, put it alone for 20 min. Then raise the coverslip vertically, put the slide in the microscope examination. Stirring liquid manure again and add saturated salt water above the nozzle slightly, press the 2 coverslip, place it for 20 min and then observe it in the endoscopic examination and repeat it until there has no egg present. Using the 10×10 times under the microscope, detect the species of intestinal parasites.

RESULTS AND DISCUSSION

Parasite infection rate: Analyses of these samples detected nine species of intestinal parasites. Eggs of *G. pulchrum* occurred in 24 samples in the total of 76 samples (31.58%) which was the highest rate among the 9 species intestinal parasites detected in the collected feces (Table 1).

Identification and high incidence of *G. pulchrum*: The eggs of *G. pulchrum* were ellipsoidal, thick-shelled eggs, rounded at both ends and smooth on the surface. They measured 56~73×38~43 μm in size and 3.0~3.4 μm thick. And there were larvae in growth period in transparent and mature eggs (Fig. 1). The incidence of *G. pulchrum* infection in Tibetan macaques was high to 31.58% which was much higher than that in Japanese macaques (*Macaca fuscata fuscata* and *Macaca fuscata yakui*, 4.5 and 18.3%) and Bolivian squirrel monkeys (*Saimiri boliviensis*, 25.5%) (Uni *et al.*, 1992, 1994; Sato *et al.*, 2005) and it's also the highest rate among the 9 species intestinal parasites detected in Tibetan macaques. The egg shape and size were similar to that in Bolivian squirrel monkeys in Japan (60±2×35±3 μm) (Sato *et al.*, 2005). Since, the record on hosts of *G. pulchrum* are few, especially in wild primate species. This is the first report that *G. pulchrum* was found infected in wild Tibetan macaques in China which means enriched the primate host of the *G. pulchrum*.

Risk to Tibetan macaques and public health: In contrast with the other detected zoonosis parasites of this study,

Table 1: Parasite infection rate of wild Tibetan macaques at Mt. Huangshan

Parasite species	Total prevalence (%)	Adult male	Female adult	Immature
<i>Oesophagostomum apiostomum</i>	23.68% (18/76)	26.47% (9/34)	16.67% (5/30)	33.33% (4/12)
<i>Ancylostoma duodenale</i>	14.47% (11/76)	14.71% (5/34)	20.00% (6/30)	0% (0/12)
<i>Strongyloides stercoralis</i>	3.95% (3/76)	5.88% (2/34)	0% (0/30)	8.33% (1/12)
<i>Rhabditis</i> sp.	1.31% (1/76)	0% (0/34)	3.33% (1/30)	0% (0/12)
<i>Trichuris trichura</i>	25.00% (19/76)	20.59% (7/34)	30.00% (9/30)	25.00% (3/12)
<i>Gongylonema</i> sp.	31.58% (24/76)	35.29% (12/34)	23.33% (7/30)	41.67% (5/12)
<i>Trichostrongylus</i> sp.	13.16% (10/76)	20.59% (7/34)	3.33% (1/30)	16.67% (2/12)
<i>Copillaria hepatica</i>	3.95% (3/76)	2.94% (1/34)	6.67% (2/30)	0% (0/12)
<i>Ascaris lumbricoides</i>	1.32% (1/76)	0% (0/34)	0% (0/30)	8.33% (1/12)

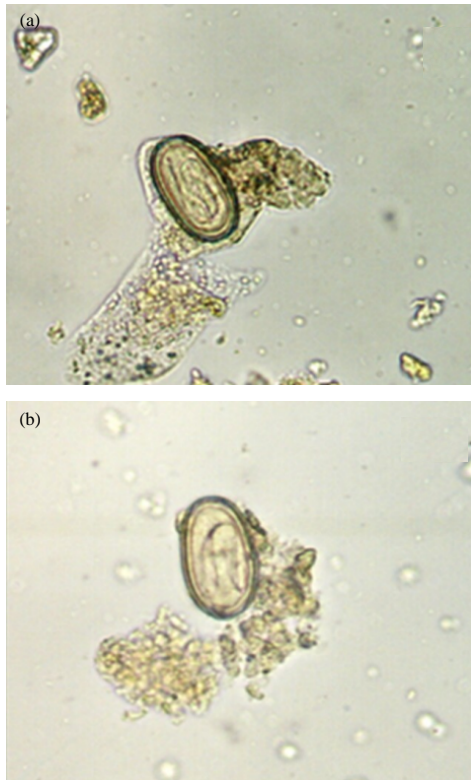


Fig. 1: a) Transparent and mature eggs with larvae in growth period and b) eggs of *G. pulchrum* in feces by microscope technique (x100 original magnification)

G. pulchrum in highest infection rate which means it has the most potential danger to Tibetan macaques. Insect intermediate hosts are required for *Gongylonema* to ingest the eggs in which the larvae become encysted. Xiong has reported that Tibetan macaques at Mt. Huangshan eat *Eumeces elegans*, bird eggs and some other insects (Xiong, 1984). Higher probability of coming into contact with these intermediate hosts is probably the reasons why this heteroxenous parasite was only detected in the free-living autochthonous animals. Also, the infection has some relationships with the environment that the life cycle

of *Gongylonema* can be completed only in endemic population, adapted to the warm and humid environment (Gotoh, 2000).

As wildlife are now recognized as an important source of emerging human pathogens including parasites (Polley, 2005), human which contact with this non-human primate also have a potential risk to infect in regards to the human-macaque interactions there. Human infections result from accidental or intentional ingestion of food contaminated with whole or parts of infected insects. Water containing larvae released from dead, disintegrating insects may be another source of infection (Dismuke and Routh, 1963; Beaver *et al.*, 1984; Molavi *et al.*, 2006).

The studying site, Huangshan Valley of the Wild Monkeys is a wild Tibetan macaque ecotourism place. The tourists are restricted to viewing pavilions and rules prohibit them from feeding the monkeys but these rules were inconsistently enforced. Many tourists use food to entice the macaques to come closer, perhaps for photo opportunities. Some tourists place food items directly into the macaque's hand or even mouth. The monkeys usually climb up on the handrail of viewing pavilions licking or excreting on it and then the tourists will press their arms or hands on the handrail (McCarthy *et al.*, 2009; Ji *et al.*, 2010). In such settings, body or indirectly contact between humans and macaques cannot be safety controlled and then if the tourists touch or eat the food with the contaminated hands directly thus also possibly subject to zoonotic disease transmission. In addition, there are some local residents live around the habitat of Tibetan macaques and drinking the same water source. In this situation, both the staff and visitors, even the local residents are at risk.

CONCLUSION

This research provides the first data to the knowledge, concerning high incidence of *G. pulchrum* in wild Tibetan macaques in China and the data would serve as a baseline for comparative assessments of disease risks, especially in this ecotourism site at Mt. Huangshan.

ACKNOWLEDGEMENTS

The researchers thank Dr. X.L. Wang, Dr. Y. Yao in Department of Parasitology, Anhui Medical University, Dr. Q. Fang, H.Z. Wu in Department of Parasitology, Bengbu Medical College for their help of detecting the nematode species. The researchers also gratefully acknowledge the staff and Mr. H.B. Cheng's family for their outstanding logistic support of the study at Huangshan. This study was supported in part by grants from the National Natural Science Foundation of China (No. 30970414; 31172106), Program of University Innovation Team of Anhui province (TD200703), Project Financed by the International Science and Technology Cooperation Plan of Anhui province (10080703034) and Specialized Research Fund for the Doctoral Program of Higher Education (200803570005).

REFERENCES

- Anderson, R.C., 1992. Nematode Parasites of Vertebrates: Their Development and Transmission. 2nd Edn., CAB International University Press, Cambridge, UK.
- Beaver, P.C., R.C. Jung and E.W. Cupp, 1984. Clinical Parasitology. 9th Edn., Lea and Febiger, Philadelphia.
- Brack, M., 1996. Gongylonematiasis in the common marmoset (*Callithrix jacchus*). Lab. Anim. Sci., 46: 266-270.
- Dismuke, J.C. and C.F. Routh, 1963. Human infection with *Gongylonema* in Georgia. Am. J. Trop. Med. Hyg., 12: 73-74.
- Duncan, M., L. Tell, C.H. Gardiner and R.J. Montali, 1995. Lingual gongylonemiasis and pasteurellosis in Goeldi's monkeys (*Callimico goeldii*). J. Zoo Wildl. Med., 26: 102-108.
- Eberhard, M.L. and C. Busillo, 1999. Human *Gongylonema* infection in a resident of New York City. Am. J. Trop. Med. Hyg., 61: 51-52.
- Feng, L.C., M.S. Tung and S.C. Su, 1955. Two Chinese cases of *Gongylonema* infection: A morphological study of the parasite and clinical study of the cases. Chin. Med. J., 73: 149-162.
- Gotoh, S., 2000. Regional differences in the infection of wild Japanese macaques by gastrointestinal helminth parasites. Primates, 41: 291-298.
- Haruki, K., H. Furuya, S. Saito and N. Kagei, 2005. *Gongylonema* infection in man: A first case of gongylonemiasis in Japan. Helminthologia, 42: 63-66.
- Illescas-Gomez, M.P., M.R. Osorio, V.G. Garcia and M.A.G. Morales, 1988. Human *Gongylonema* infection in Spain. Am. J. Trop. Med. Hyg., 38: 363-365.
- Jelinek, T. and T. Loscher, 1994. Human infection with *Gongylonema pulchrum*: A case report. J. Trop. Med. Parasitol., 45: 329-330.
- Ji, H., J.H. Li, B.H. Sun and Y. Zhu, 2010. Comparisons of aggressive behavior for tibetan macaques (*Macaca thibetana*) to tourists from Mt. Huangshan, China. Zool. Res., 31: 428-434 (In Chinese).
- Jonston, T.H., 1936. A note on the occurrence of the nematode *Gongylonema pulchrum* in man in New Zealand. N. Z. Med. J., 35: 172-176.
- Kelly, J., 1974. Antropozoonotic helminthiasis in Australia. II. Antropozoonosis associated with domesticated animals and domiciliated vertebrates. Int. J. Zoonosis, 1: 13-24.
- Kudo, N., T. Koneguchi, H. Ikadai and T. Oyamada, 2003. Experimental infection of laboratory animals and sheep with *Gongylonema pulchrum* in Japan. J. Vet. Med. Sci., 65: 921-925.
- Kudo, N., T. Oyamada, M. Okutsu and M. Kinoshita, 1996. Intermediate hosts of *Gongylonema pulchrum* Molin, 1857, in Aomori Prefecture, Japan. Jpn. J. Parasitol., 45: 222-229.
- Li, J.H., 1999. The Tibetan Macaque Society: A Field Study. Anhui University Press, Hefei, China.
- McCarthy, M.S., M.D. Matheson, J.D. Lester, L.K. Sheeran, J.H. Li and R.S. Wagner, 2009. Sequences of tibetan macaque (*Macaca thibetana*) and tourist behaviors at Mt. Huangshan, China. Primate Conserv., 24: 145-151.
- Molavi, G.H., J. Massoud and Y. Gutierrez, 2006. Human *Gongylonema* infection in Iran. J. Helminthol., 80: 425-428.
- Polley, L., 2005. Navigating parasite webs and parasite flow: Emerging and re-emerging parasitic zoonoses of wildlife origin. Int. J. Parasitol., 35: 1279-1294.
- Sakovich, A., 1970. A case of human gongylonemiasis with affection of tissue of the peritoneal region. Stomatologia, 49: 80-80.
- Sato, H., Y. Une and M. Takada, 2005. High incidence of the gullet worm, *Gongylonema pulchrum*, in a squirrel monkey colony in a zoological garden in Japan. Vet. Parasitol., 127: 131-137.
- Shang, X., 1985. Two cases of gongylonemiasis. J. Parasitol. Parasit. Dis., 3: 258-258.
- Stiles, C.W. and C.E. Baker, 1928. A fifth case of gongylonema hominis in man in the United States. J. Parasitol., 91: 1891-1892.
- Uni, S., N.M. Abdelmaksoud, M. Abe, K. Harada and M. Iseki *et al.*, 1992. New record of *Gongylonema pulchrum* Molin, 1857 from a new host, *Macaca fuscata*, in Japan. Ann. Parasitol. Hum. Comp., 67: 221-223.

- Uni, S., S. Kobayashi, M. Miyashita, N. Kimura and A. Kato *et al.*, 1994. Geographic distribution of *Gongylonema pulchrum* and *Gongylonema macrogubernaculum* from *Macaca fuscata* in Japan. *Parasite*, 1: 127-130.
- Urch, T., B.C. Albrecht, D.W. Buttner and E. Tannich, 2005. Human infection with *Gongylonema pulchrum*. *Deut. Med. Wochenschr.*, 130: 2566-2568.
- Weng, G., 1985. A case of gongylonemiasis. *J. Parasitol. Parasit. Dis.*, 3: 177-177.
- Wilde, H., C. Suankratay, C. Thongkam, N. Chaiyabutr and N. Chaiyabutr, 2001. Human gongylonema infection in Southeast Asia. *J. Travel Med.*, 8: 204-206.
- Xiong, C.P., 1984. Ecological studies of the stump-tailed macaque. *Acta Theriol. Sin.*, 4: 1-9.
- Yamashita J., 1963. Ecological relationships between parasites and primates I. Helminth parasites and primates. *Primates*, 4: 1-96.