

ANF in the Parotid Gland in Rabbits

¹F. Carini, ²G.A. Scardina, ⁴C. Lo Piccolo, ¹L. Lipari, ³S. Ferrara, ²P. Messina and ¹V. Valenza

¹Department of Biomedicine Experimental and Clinical Neuroscience,

²Department of Oral Science, ³Department of Special Surgery (ORL), University of Palermo, Italy

⁴Head and Neck Surgery Division, European Institute of Oncology, Milano, Italy

Abstract: It is well known that the presence of a particular type of granule population has been discovered in the atrial cardiocytes which represent the major site of synthesis of atrial natriuretic factor. The ANF has potent natriuretic, diuretic and vasoactive functions. However, ANF evidence occurs in extracardiac tissues such as the brain, intestine, lymphoid organs and in various glands involved in water and salt regulation adrenals, pancreas, lacrimal and salivary glands with respect to salivary glands the literature reports that ANF presence was found in the acinar cells and on the contrary in the ductal cells. In order to eliminate these discordances researchers conducted a previous study on rabbit parotid gland. The observations evidenced that the acinar cells were immunonegative while the ductal intraparenchymal cells were immunopositive in the present research we have extended the study on the main excretory duct of rabbit parotid gland.

Key words: Atrial natriuretic factor, submandibular gland, immunohistochemistry, excretory duct, parotid gland, Italy

INTRODUCTION

The Atrial Natriuretic Factor (ANF) is a polypeptide and is termed pre-pro ANF. It is constituted by 151 amino acid peptide in humans and 152 amino acid peptide are contained in rats as well as in mice. It is possible to obtain pro-ANF from pre-pro-ANF, atriopeptin. This is a polypeptide constituted by 126 amino acids. This peptide is the major molecular form of ANF stored in atrial granules. In addition it is possible to obtain ANF from the pro-ANF which is a peptide of 28 amino acids (Cys 105-121) joined with a disulfur-bridge (S-S). This is necessary for its biological activity as it is released in the plasma at low levels.

In 1956 and 1964, Kish and Jamiesone Palade analysed atrial myocardiocyte in secretory granules which were probably proteinic. Afterwards, there was a large quantity of granules and sodium-water pump therefore, those atrial granule acted as to regulate the water (Bold *et al.*, 1981; Bold, 2011). Recently, atrial natriuretic peptides, named atrial natriuretic factors causes diuresis, natriuresis and vasodilation with consequent lowering of the pressure in the arteries (Cantin and Genest, 1985).

A number of studies have been conducted with autoradiography and immunohistochemical technology has shown that the atrial granules are not only present in atrial myocytes but also in ventricular myocytes even

though they are present in lesser quantities (Yamada *et al.*, 1988; Bruneau, 2011). Immunopositivity is also present in the inner ventricle walls of the heart, Purkinje fibers and atrioventricular bundle. At this point, the information is diverse because some show immunonegativity (Toshimori *et al.*, 1988) whereas others prove there is immunopositivity. The difference of information could also be attributed to different physiological points in the cardiac cycle. Recently, ANF was present in the atrioventricular bicuspid and tricuspid valve (Valentino *et al.*, 1995).

Studies of the atrial natriuretic factors have been extended to the circulatory, urinary, respiratory, nervous, digestive system as well as the glands.

As far as the circulatory system is concerned, the secretory atrial granules of ANF are present in the muscular cells near the pulmonary veins (Mittag *et al.*, 1987) in the superior vena cava (Asar *et al.*, 1987; Larsen, 1988) and the inferior vena cava (Larsen, 1988). ANF was identified in the aorta and the muscular layer of the vascular walls in rats (Nemer *et al.*, 1988). It is predominate in the aortic bifurcation near the baroreceptors. ANF was also present in the human aortic arch.

The role of the ANF in the aorta is still unknown. However, the low level of synthesis and its modulation in cardiovascular disease suggests that ANF may have autocrine and paracrine effects as well as involve the

modulation of the reflex of baroreceptors. In conclusion, ANF in blood vessels could have an important hemodynamic role on the diameter. ANF is widely distributed in the preoptic area and the hypothalamus (Jacobowitz *et al.*, 1985; Skofitsch *et al.*, 1985), hypothalamic nuclei, the periventricular region and the arcuate nuclei. The dislocation of ANF in the hypothalamic region suggests a significant role in regulating the salt and water balance. In addition, the periventricular region may imply a role on the modulation of the cardiac centers. In dogs, the ANF contains a different distribution. Infusion of a synthetic atrial natriuretic factor into encephalic ventricles produced striking increases in natriuresis, diuresis and kaliuresis with consequent increase in renal blood flow. The speed of glomerular filtration is decreased whereas there are no effects on the blood pressure or of the heart with the administration in the systemic circle.

ANF can act as a neurotransmitter and have an inhibitory effect on the neuron. This would explain the fundamental inhibitory action on the peptide. Finally, it is important to point out that the quantity of encephalic ANF is controlled in a different way compared to the cardiac ANF. It also has a different origin because it does not go through the encephalic barrier and it is not transported by a cephalorachidian liquid. The ANF is probably synthesized to the hypothalamic level and transported to the other encephalic areas. Furthermore, ANF was also present in olfactory bulbs as well as the spinal cord and it is not distributed in a homogeneously since there is a high concentration in the lumbo sacral region and a low amount in the cervicothoracic region.

The eye also contains ANF. A form of ANF which corresponds to the circulating peptide of 28 amino acids is present anterior uvea and the retina in rats. Where the ANF in the eye actually comes from is still unknown. However, it is assumed that there is a role of ANF in regulating the pressure of aqueous humor.

In the kidney, the early studies of immunohistochemistry has shown the presence of ANF in the cortical collection tubules as well as medullaris in different species such as rats, horses, pigs, monkeys as humans (Kenzie *et al.*, 1985; Sakamoto *et al.*, 1985).

An increase of glomerular blood flow with a consequent increase of filtration was demonstrated in several studies through the administration of ANF Burnet, Maak and Huang have assumed a vasodilation in pre-glomerular and intraglomerular vessels. On the other hand, others have proved to show that an increase of ANF cannot be associated with an increase in glomerular filtration (Bold *et al.*, 1981).

Both the prohormone and the circulating hormone were present in the pulmonary apparatus and in the parenchyma (Sirois and Gutkowska, 1988) in rats and pigs (Asar *et al.*, 1987). The ANF should be synthesized and excreted from the lungs. ANF was also detected in a few alveolar cells as well as bronchial cells and bronchioli cells and they may involve the regulation of the mucous fluid (Valentino *et al.*, 1995). ANF in the pulmonary apparatus could also contribute at ANF plasmatic levels in particular physiopathology conditions in which plasma ANF levels increased whereas ANF which is of atrial origin is diminished this is caused by a cardiac attack.

Alternatively, ANF in the lungs could have an autocrine and paracrine role. In fact, some receptors have been found there (Kuno *et al.*, 1986). It has been demonstrated that it is responsible for different effects such as the reduction of the vasoconstriction which develops in hypoxia and the bronchodilation.

ANF holds an important role in preventing pulmonary edema (Imamura *et al.*, 1988; Inomata *et al.*, 1987). ANF is also present in the exocrine gland in the pancreas as well as the salivary glands. ANF was present in cellule acinose and centroacinose in the pancreas. In acinar and centroacinar cells which is associated to the membrane and the cytoplasm of the cells. The concentration of ANF is rather low compared to the others (Chabot *et al.*, 1987).

ANF probably stimulates the pancreatic secretion which actually increases the dose of secretin. Similar results took place in the stomach which stimulates the gastric secretion (Purunen and Ruskoaho, 1987).

Cytotypes of ducts are a result of constant immunonegativity in all of the major salivary glands thanks to immunofluorescence and immunoperoxidase techniques (Cantin *et al.*, 1984). However, intense immunoreactivity at the levels of acinar cells as well as levels of the peribasal and perinuclear space were present in the paratoid in rats. Immunopositivity was also identified in serous cells in the sublingual glands. These cells in rats contain cytoplasm which are full of granules of reaction. The reaction in submandibular glands is less intense.

Nemer *et al.* (1985) have found positivity in the cells of the striated ductus of the submandibular gland. A immunohistochemical study of the parotid gland in rabbits was performed in order to clarify recent differences which regard the specific site of ANF in salivary glands.

MATERIALS AND METHODS

Ten rabbits underwent anaesthesia with ether and sacrificed with injection. Parotid glands were withdrawn through dissection which were then placed in Bovin liquid. Afterwards, the pieces were included in paraffin

and 6 μ were dissected by using Zeiss microtome micron. The dissected parts were treated with anti-ANF monoclonal antibodies (dilution 1:1000). The Avidina-Biotina systems was used as a developer system so that the dissected parts were analysed with a Zeiss axis microscope at various enlargements.

RESULTS AND DISCUSSION

Results have demonstrated that the dissected parts which were treated with anti-ANF monoclonal antibodies in the parotid gland in rabbits present immunonegativity at the level of the acinar cells. On the other hand, immunopositivity was found at the level of ducts. The intralobular cells or intercalary ducts and striated ducts as well as the extralobular duct resulted immunopositive. (Fig. 1 and 2).

The results obtained are in contrast with those of Cantin *et al.* (1984). He identified immunopositivity in the saliva parotid glands and submandinular glands at the level of acinar cells in rats. This difference could be attributed to the diverse species in animals such as rats or rabbits or a different physiological condition.

Receptors of ANF is present in acinar cells of the submandibular gland and the parotid glands in rats according to researchers (Yabe *et al.*, 1993). Moreover, it has been demonstrated that ANF reduces the secretion of

amylase induced by isoproterenol (Nashida *et al.*, 1994). Synthesised ANF of the intralobular duct cells could have a special effect on acinar cells thanks to a paracrine mechanism with consequent accumulation of amp ciclic and secretion of amylase.

CONCLUSION

The presence of ANF at the level of extralobular duct could have a different role. For example, it could act on periductal vessels with consequent water regulation of the saliva. In fact, ANF is a factor which does not induce salivation itself but it increases the serologic factors (noradrenalyn, substance P) (Bianciotti *et al.*, 1994).

REFERENCES

- Asar, J., M. Nakazato, H. Toshimori, S. Matsukura, K. Kangawa and M. Matsuo, 1987. Presence of atrial natriuretic polypeptide in the pulmonary vein. *Biochem. Biophys. Res. Commun.*, 146: 1465-1470.
- Bianciotti, L.G., J.C. Elverdin, M.S. Vatta, C. Colatrella and B.E. Fernandez, 1994. Atrial natriuretic factor enhances induced salivary secretion in the rat. *Regul. Pept.*, 49: 195-202.
- Bold, de A.J., 2011. Thirty years of research on atrial natriuretic factor: Historical background and emerging concepts. *Can. J. Physiol. Pharmacol.*, 89: 527-531.
- Bold, de A.J., H.B. Borenstein, A.T. Veress and G.H. Sonnenberg, 1981. A rapid and potent natriuretic response to intravenous injection of atrial myocardial extract in rats. *Life Sci.*, 28: 89-94.
- Bruneau, B.G., 2011. Atrial natriuretic factor in the developing heart: A signpost for cardiac morphogenesis. *Can. J. Physiol. Pharmacol.*, 89: 533-537.
- Cantin, M. and J. Genest, 1985. The heart and atrial natriuretic factor. *Endoc. Rev.*, 6: 107-127.
- Cantin, M., J. Gutkowska, G. Thibault, R.W. Milne, S. Ledoux, S. Minli and C. Chapeau, 1984. Immunocytochemical localization of atrial natriuretic factor in the heart and salivary glands. *Histochem.*, 80: 113-127.
- Chabot, J.G., G. Morel, H. Kopelman, M. Belles and S. Heisler, 1987. Atrial natriuretic factor and exocrine pancreas: Autoradiographic localization of binding sites and ultrastructural evidence for internalization of endogenolts ANF. *Pancreas*, 2: 404-404.
- Imamura, T., N.F. OhnumaIwasa, M. Furuya, Y. Hayashi, N. Inomata, T. Shihara and T. Noguchi, 1988. Protective effect of a human atrial natriuretic polypeptide (alfa-hANP) on chemical induced pulmonary edema. *Life Sci.*, 42: 403-403.



Fig. 1: Immunopositive basal cells 25X

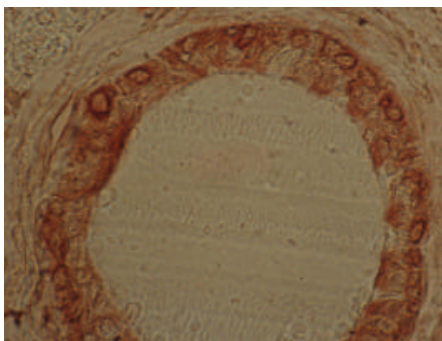


Fig. 2: Immunopositive basal cells 40X

- Inomata, N., N. Ohnuma, M. Furuya, Y. Hayashi and Y. Kanai *et al.*, 1987. Alpha-humana atrial natriuretic peptide (afa-hANP) prevents pulmonary edema induced by arachidonic acid treatment in isolated perfused lung from guinea pig. *Jpn. J. Pharmacol.*, 44: 211-211.
- Jacobowitz, D.M., G. Skofitsch, H.R. Keiser, R.L. Eskay and N. Zamir, 1985. Evidence of the existence of atrial natriuretic factor-containing neurons in the rat brain. *Neuroendocrinol.*, 40: 92-94.
- Kenzie, J.C., I. Tanaka, K.S. Misono and T. Inagami, 1985. Immunocytochemical localization of atrial natriuretic factor in the kidney, adrenal medulla, pituitary and atrium of rat. *J. Histochem. Cytochem.*, 33: 828-832.
- Kuno, T., J.W. Andresen, Y. Kamisaki, S.A. Waldman and L.Y. Chang *et al.*, 1986. Co-purification of an atrial natriuretic factor receptor and particulate guanylate cyclase from rat lung. *J. Biol. Chem.*, 261: 5817-5817.
- Larsen, T.H., 1988. Immunocytochemical localization of atrial natriuretic peptide in the venae cavae and the pulmonary veins of the rat. *Histochem. J.*, 20: 69-74.
- Mittag, T.W., A. Tormay, M. Ortega and C. Severin, 1987. Atrial natriuretic peptide (ANP), guanylate cyclase, and intraocular pressure in the rabbit eye. *Curt. Eye Res.*, 6: 1189-1196.
- Nashida, T., A. Imai, H. Shimomura, 1994. Influence of atrial natriuretic peptide on cyclic nucleotides and amylase release in rat parotid salivary gland *in vitro*. *Archs. Oral. Biol.*, 39: 129-132.
- Nemer, M., T. Antakly, A. Sarrieau, J.P. Lavigne and J. Drouin, 1985. High atrial content of glucocorticoid receptor and glucocorticoid induction of ANF mRNA. *J. Steroid. Biochem.*, 25: 106-106.
- Nemer, M., T. Antakly, S. Argentin, J.P. Lavigne and J. Drouin, 1988. Cloning and expression of the atrial natriuretic factor gene. *Clin. Phys. Biochem.*, 6: 163-170.
- Purunen, J. and H. Ruskoaho, 1987. Vagal-dependent stimulation of gastric acid secretion by intracerebroventricularly administered atrial natriuretic peptide in anaesthetized rats. *Eur. J. Pharmacol.*, 141: 493-495.
- Sakamoto, M., K. Nakao, M. Kihara, N. Morii and A. Sugawara *et al.*, 1985. Existence of atrial natriuretic polypeptide in kidney. *Biochem. Biophys. Res. Commun.*, 128: 1281-1287.
- Sirois, P. and J. Gutkowska, 1988. Atrial Natriuretic Factor (ANF) immunoreactivity in human fetal lung tissue and perfusates. *Hypertension*, 11: 162-165.
- Skofitsch, G., D.M. Jacobowitz, R.L. Eskay and N. Zamir, 1985. Distribution of atrial natriuretic factor-like immunoreactive neurons in the rat brain. *Neurosci.*, 16: 917-948.
- Toshimori, H., M. Nakazato, K. Toshimori, J. Asai, S. Matsukura, C. Oura and H. Matsuo, 1988. Distribution of Atrial Natriuretic Polypeptide (ANP)-containing cells in the rat heart and pulmonary vein. *Cell. Tissue. Res.*, 251: 541-546.
- Valentino, B., E. Farina, F. Carini and V. Valenza, 1995. ANF distribution in the airways. *Ital. J. Anat. Embryol.*, 100: 211-211.
- Yabe, T., A. Imai, T. Nashida and H. Shimamura, 1993. A study of atrial natriuretic peptide receptor of the rat salivary gland. *Odontol.*, 80: 1441-1449.
- Yamada, H., Y. Saito, M. Mukoyama, K. Nakao and H. Yasue *et al.*, 1988. Immunohistochemical localization of Atrial Natriuretic Polypeptide (ANP) in human atrial and ventricular myocytes. *Histochem.*, 89: 411-413.