

## Mammary Gland Adenocarcinoma in Three Small Indian Mongooses (*Herpestes javanicus*)

Kaiser Dawood

Department of Veterinary Pathology, Faculty of Veterinary Medicine,  
Basra University, Basra, Iraq

**Abstract:** Mammary gland neoplasms of all types in wildlife are considered rare and underreported. Three female mongooses of unknown age were presented with lethargy, limping and poor body condition. On examination, the mongooses were anaemic, dehydrated and anorexic with palpable subcutaneous masses in the mammary gland region, overlain by ulcerated skin. At postmortem examination the masses were firm, multinodular and nonencapsulated. Microscopically, the normal mammary gland architecture was disrupted by neoplastic epithelial cells arranged in tubules, acini and fewer anaplastic solid sheets. Metastatic cells were found in other organs. The tumors were classified as simple adenocarcinoma, grade II. This is the first report of mammary gland neoplasia in mongooses.

**Key words:** Mammary carcinoma, Indian mongoose, pathology, wild animals, solid sheets, Iraq

---

### INTRODUCTION

While mammary neoplasms are well described and documented in dogs and cats, they are rarely reported in wildlife. Wild animals are sometimes only examined for their potential to carry specific disease such as rabies in wild carnivores and are not otherwise studied (Nel *et al.*, 2005). However, mammary neoplasia has been reported in diverse species of wild animal such as red fox, deer, hedgehogs, jaguar, tiger, lion, ferret, Californian sea lion, kangaroo, koala, possums and bandicoots (Ladds, 2009). The mongoose in the *Herpestes* genus is a carnivorous mammal that inhabits Southern Europe, Asia and Africa. Small Indian mongooses (*Herpestes javanicus*) are the predominant population of mongooses in Iraq and extend as far as China (Gilchrist *et al.*, 2009). There are a small number of published studies on the population size, distribution and physiology of this genus; however, its diseases have not been adequately investigated. Researchers believe that this is the 1st case report of mammary gland adenocarcinoma in the small Indian mongoose.

### MATERIALS AND METHODS

From 2000-2003, three female small Indian mongooses were captured in rural locations in Basra province, South Iraq after showing variable clinical signs including lethargy, mild ataxia and limping. The mongooses were numbered 1-3 for identification and were put into suitable

wire mesh pet cages and sent to the Teaching Veterinary Hospital, Basra University. On examination, the mongooses were pale and emaciated with marked cutaneous abrasions over the head. Multiple, ulcerated, firm, subcutaneous masses (1-1.5 cm in diameter) were present in the mammary gland region under the right hind limb of mongooses 1 and 2 and under the left hind limb of mongoose 3. The mongooses were euthanized humanely by injection of phenobarbital into the peritoneal cavity and transferred to the Pathology Department, Veterinary Science Faculty at Basra University.

On postmortem examination, the masses were located subcutaneously within inactive glandular tissue and were smooth, firm and white to tan. On cut surface, they were unencapsulated and comprised of variably sized nodules. Mongoose 1 had a raised 5 mm diameter, subcutaneous nodule present on the anterolateral border of the right thigh, over the biceps femoris and cranial sartorius muscles. Mongooses 2 and 3 had lymph nodes close to the mammary gland which were enlarged about 4 times normal.

The tumour masses, liver, two regional lymph nodes, spleen, lung, kidney and brain from each mongoose were fixed in 10% neutral buffered formalin, embedded in paraffin and routinely processed for histopathology. All the sections were stained with haematoxylin and eosin. The masse sections were also stained with alcian blue and masson's trichrome for more histology details. An impression smear from the masses was made and stained with diff-quick.

## RESULTS AND DISCUSSION

Histologically, the mammary tumors revealed proliferative, multi-nodular, well-demarcated, unencapsulated and infiltrative masses composed of neoplastic epithelial cells. The neoplastic cells were arranged mainly in tubules, acini, scattered nests, fewer lobules, solid sheets and rare branching trabeculae supported on very scant fibrovascular stroma (Fig. 1 and 2). The tubules were lined by up to 6 layers of cuboidal to low columnar epithelial cells with indistinct borders and moderate eosinophilic to amphophilic cytoplasm.

The nuclei were round to irregular with finely stippled chromatin and up to 5 prominent, round to angular, magenta nucleoli. There was marked anisocytosis and anisokaryosis. The mitotic rate was high ( $7 \text{ hpf}^{-1}$ ) with occasional bizarre mitoses. Large numbers of neoplastic cells invaded the basement membranes and surrounding

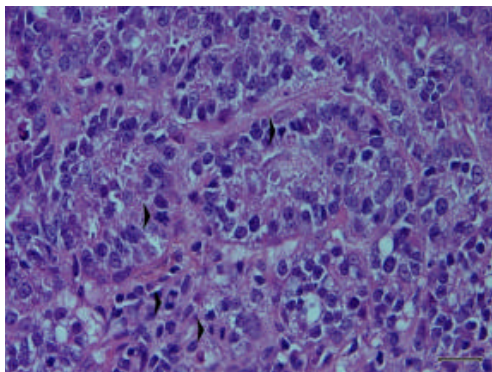


Fig. 1: Mongoose, mammary gland adenocarcinoma: Neoplastic cells form tubules and acini. There are several mitotic cells (Arrow head). H and E. Bar = 20  $\mu\text{m}$

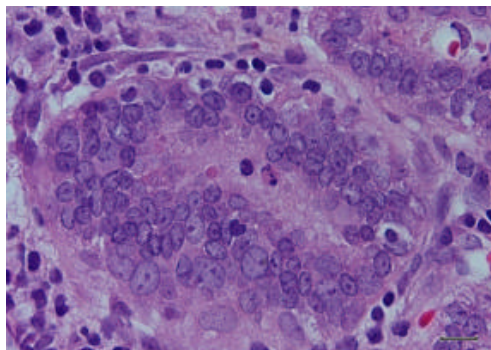


Fig. 2: Mongoose, mammary gland: Proliferative epithelial cells expanding a tubule forming lobular carcinoma. H and E. Bar = 10  $\mu\text{m}$

tissues. Multi-focal, random, moderate necrosis and haemorrhage were observed. Lymphatic and blood vessel invasion was found in mongoose 2. The nodule in the thigh of mongoose 1 comprised epithelial cells forming acini between the fibrocytes. The enlarged lymph nodes in mongooses 2 and 3 displayed severe depletion of the lymphoid germinal centres with a marked increase in connective tissue in the cortex and medulla. Tubular and acinar structures are found in the cortex and medulla (Fig. 3). Low numbers of necrotic foci were present at the corticomedullary junction. No metastases were observed in liver, lung, kidney, spleen and brain. The impression smears revealed clusters of round, epithelial cells with basophilic cytoplasm and a moderate increase in the nucleus: Cytoplasm ratio. Many epithelial cells were binucleate and had vacuolated cytoplasm.

Neoplastic diseases in wild mammals are difficult to report more than those with the known infectious diseases due to compromising of activities and surviving for a limited time (Ladds, 2009). The presence of marked anisocytosis, anisokaryosis, high mitotic rate, local and vascular invasion and metastasis in the described tumours strongly indicate that they are highly malignant (Hampe and Misdorp, 1974; Ginn *et al.*, 2007).

Moreover, the histological changes are very similar if not identical to mammary gland carcinoma in dog. Since, the predominant neoplastic pattern was tubular, the tumours were classified as tubular adenocarcinoma grade II using criteria established for dogs and cats by Hampe and Misdorp (1974) and Misdorp (2002). All mongooses showed multiorgan metastasis but no metastases were found in the lungs which are the common site of metastasis of mammary tumors in most species. Cytological examination provided a tentative diagnosis of carcinoma based on the presence of malignant features such as cluster-forming epithelial cells, binucleation, anisocytosis, anisokaryosis and increased

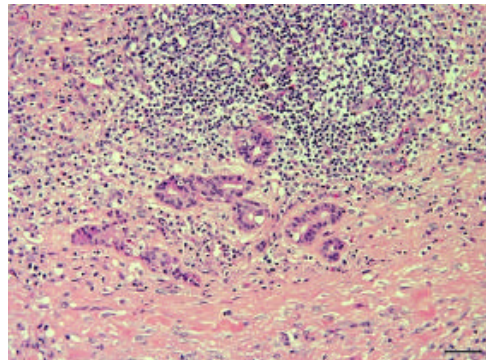


Fig. 3: Mongoose, lymph node: Metastatic neoplastic epithelial cells in a lymph node forming small tubules and acini

nucleus: Cytoplasm ratio. Therefore, cytology of a mammary gland tumor could provide a reasonably accurate, preliminary diagnosis (DeHeer *et al.*, 2002). In domestic and captive carnivores, e.g., bitches and queens, hormones have an influence on mammary gland tumours. This is demonstrated by ovariectomy in queens which reduces the incidence of mammary tumour development after ovariectomy (Misdorp, 2002).

Conversely, the use of progestagen contraceptives in zoos may increase the incidence of mammary neoplasia in felids (McAloose *et al.*, 2007). In free-ranging carnivores it is unknown whether hormones affect the incidence of mammary carcinoma.

The role of viruses in producing neoplasia in mammals has become more recognized in recent years since, the detection of retroviruses in mammary neoplasms of cats, mice and the spotted-tailed quoll (Percy and Barthold, 2007; Ladds, 2009). However, the relationship of viruses to mammary gland neoplasia is still unclear, particularly in wild and captive animals.

Therefore, viral involvement can not be excluded in the pathogenesis of the tumours described in this report. It is difficult to assess whether aging was a predisposing factor to tumour development because the age of the mongooses was unknown. However, they were estimated to be young adults by assessing the hair, teeth and lenses.

Stress has not been convincingly documented to cause mammary neoplasia in domestic and non-domestic carnivores. Since, the mongooses were non-captive. The researchers consider that dietary carcinogens, other chemicals and radiation are unlikely causes. Carcinogenic therapeutic agents can also be excluded.

Although, this report documents mammary neoplasia in only three mongooses, it raises a question about the susceptibility of this species to this type of neoplasia and encourages more investigation. Mammary neoplasia should be considered in the differential diagnosis of masses in the mammary region of mongooses.

### CONCLUSION

The study shows that the small Indian mongooses can develop metastatic and highly malignant mammary gland carcinoma. To the researchers knowledge, this study describes the 1st case of mammary neoplasia in mongooses.

### ACKNOWLEDGEMENTS

Many thanks to the staff at Department of Veterinary Pathology, College of Veterinary Medicine, Basra University, Iraq. I would also like to thank Mr. Chris Butt, Ultimo College, Sydney, Australia, for the efforts in reviewing the manuscript linguistically.

### REFERENCES

- DeHeer, H.L., B.W. Parry and C.B. Grindem, 2002. Pleural Fluid. In: Diagnostic Cytology and Hematology of the Horse, 2nd Edn., Cowell, R.L. and R.D. Tyier (Eds.). Mosby Inc., Missouri, USA., ISBN-13: 9780323013178, pp: 99-126.
- Gilchrist, J.S., A.P. Jennings, G. Veron and P. Cavallini, 2009. Family Herpestidae. In: Handbook of the Mammals of the World, Wilson, D.E. and R.A. Mittermeier (Eds.). Lynx Editions Publisher, Barcelona, Spain, ISBN: 9788496553491, pp: 262-328.
- Gim, P.E., J.E.K.L. Mansell and P.M. Pakich, 2007. Skin and Appendages. In: Jubb, Kennedy and Palmer's Pathology of Domestic Animals, 5th Edn., Maxie, M.G. (Ed.). Elsevier Saunders, China, ISBN: 9780702027840, pp: 2770-2781.
- Hampe, J.F. and W. Misdorp, 1974. Tumors and dysplasia of the mammary gland. Bull. World Health Organiz., 50: 111-133.
- Ladds, P.W., 2009. Pathology of Australian Native Wildlife. 1010 Printing International Ltd., China, Pages: 484.
- McAloose, D., L. Munson and D.K. Naydan, 2007. Histologic features of mammary carcinomas in zoo felids treated with Melengestrol Acetate (MGA) contraceptives. Vet. Pathol., 44: 320-326.
- Misdorp, W., 2002. Mammary Gland Tumors. In: Tumor in Domestic Animals, 4th Edn., Meuten, D.J. (Ed.). Wiley-Blackell Co. Ltd., Iowa, USA., ISBN: 9780813826523, pp: 575-606.
- Nel, L.H., C.T. Sabeta, B. von Teichman, J.B. Jaftha, C.E. Rupprecht and J. Bingham, 2005. Mongoose rabies in Southern Africa: A re-evaluation based on molecular epidemiology. Virus Res., 109: 165-173.
- Percy, D.H. and S.W. Barthold, 2007. Pathology of Laboratory Rodents and Rabbits. 3rd Edn., John Wiley and Sons, Iowa, USA., ISBN: 9780813821016, Pages: 124.