

The Luminal Diameters of Trachea and Bronchi in Small Breed Dogs with and Without Chronic Degenerative Mitral Valvular Disease

¹Tzu-Chi Tai and ²Hui-Pi Huang

¹Azu Clinic for Animals, 100 Taipei City, Taiwan

²Institute of Veterinary Clinical Science, Veterinary School,
National Taiwan University, 106 Taipei, Taiwan

Abstract: This study aimed to estimate the prevalence of tracheobronchial collapse in dogs with Chronic Degenerative Mitral valvular Disease (CDMD) and to clarify the relationship between left atrial enlargement and airway collapse in clinically healthy small-breed dogs and dogs with CDMD at various stages of heart failure. 54 clinically healthy dogs and 133 CDMD dogs were evaluated. The angle of Tracheal Bifurcation (TB angle), luminal diameters of the trachea and bronchi, ratio of the tracheal or bronchial diameters to the thoracic inlet distance (TD/TI), diameters at 6 locations (i.e., cervical, thoracic inlet, thoracic, carina and right and left cranial lobar bronchi) and vertebral heart scale were measured on digital thoracic radiographs. The prevalence of collapsed trachea prior to carina in clinically healthy dogs and those with CDMD were 28 and 29%, respectively. Compared to healthy controls, the TB angle, TD/TI at the carina and left cranial Lobar Bronchus (LB) of the CDMD dogs that were categorized in the modified New York Heart Association functional classification 3 and 4 were significantly different. VHS in CDMD was negatively correlated to carina/TI, right cranial LB/TI and left cranial LB/TI. The left atrial diameter/aortic root diameter was negatively correlated to carina/TI, right cranial LB and left cranial LB/TI. The results indicated that a collapsed trachea was not associated with CDMD in dogs. The narrowing of the trachea and bronchus in CDMD dogs developed where the anatomical regions were in direct contact with the left atrium. The degree of tracheobronchial compression was associated with the severity of CDMD.

Key words: Bronchial diameter, chronic degenerative mitral valvular disease, dogs, tracheal diameter, root diameter

INTRODUCTION

Chronic Degenerative Mitral valvular Disease (CDMD) and Tracheal Collapse (TC)/Tracheobronchial Collapse (TBC) are 2 of the most highly prevalent cardiopulmonary diseases in small-breed dogs. The high rate of coexistence of these 2 syndromes and their similar clinical signs such as coughing and panting, contribute to the diagnostic and therapeutic difficulty (Ettinger, 2010; Olsen *et al.*, 2010). In dogs, CDMD is the most common acquired cardiovascular disease (Atkins *et al.*, 2009). The prevalence of CDMD is strongly age and breed-dependent, occurring in approximately 75% of dogs older than 16 years (Atkins *et al.*, 2009; Olsen *et al.*, 2010). CDMD is characterized by chronic myxomatous mitral valve degeneration resulting in thickening and incomplete apposition of the valve leaflets during systole with secondary Mitral valve Regurgitation (MR) (Atkins *et al.*, 2009). Several complications can occur concomitantly with

MR worsening including left and then right-sided congestive heart failure secondary to elevated pulmonary artery pressure (Chiavegato *et al.*, 2009; Lord *et al.*, 2010; Serres *et al.*, 2006). The diagnosis and stage for CDMD is based on thoracic radiography and echocardiography (Atkins *et al.*, 2009; Borgarelli and Buchanan, 2012). In dogs with CDMD, a compressed Left cranial Lobar Bronchus (LLB) and associated clinical signs have been anecdotally attributed to the presence of severe left atrial enlargement (Ettinger, 2010; Olsen *et al.*, 2010). The Tracheal Bifurcation angle (TB angle) is an additional quantitative measurement to evaluate the enlargement of the left atrium, providing information on the severity of heart failure in dogs with CDMD (Le Roux *et al.*, 2012). Significant differences of the TB angle have been observed among dogs with normal and increased left atrial size (Le Roux *et al.*, 2012).

Tracheobronchial collapse is defined either by narrowing the lumen of the trachea and bronchi, prolapse

of the dorsal tracheal membrane or a combination of these abnormalities (Johnson, 2000). Tracheobronchial narrowing is a multifactorial process that results from weakening of the tracheobronchial cartilage (Dallman *et al.*, 1985, 1988). Many dogs with Tracheal Collapse (TC) suffer the collapse of both the cervical and intrathoracic trachea (Dabanoglu *et al.*, 2001). When bronchial collapse occurs in conjunction with tracheal collapse, this is termed tracheobronchial collapse (Ettinger, 2010; Johnson and Pollard, 2010). In some dogs, the principal bronchi are collapsed with the left cranial lobar bronchi affected most frequently (Johnson and Pollard, 2010). The diagnosis of TBC is made by the visual identification of a >25% reduction in the luminal diameter of the airway during a tracheobronchoscopy for dogs (Johnson and Pollard, 2010). Tracheobronchoscopy is the reference gold standard method for diagnosing and staging TBC and must be performed under general anesthesia (Tangner and Hobson, 1982). Thoracic radiographic examination is a routine and essential diagnostic tool for evaluating tracheobronchial diameters and cardiac silhouettes (Macready *et al.*, 2007). The ratio of the tracheal or bronchial diameters to thoracic inlet distance (TD/TI) in thoracic radiographs is a quantitative value for the objective estimation of tracheal diameters. Determination of the TD/TI is a convenient and simple measurement for tracheobronchial narrowing and compression by the heart in dogs (Harvey and Fink, 1982).

Although, high comorbidity was observed between CDMD and TBC in small geriatric dogs, only a few studies have focused on the cardiac manifestations of respiratory disorders or their inverse relationship in veterinary studies and these studies only included a limited population of TBC dogs (Johnson *et al.*, 1999; Pyle *et al.*, 2004). This study aimed to estimate the prevalence of TBC in small-breed dogs with CDMD and to clarify whether there is a relationship between left atrial enlargement and airway collapse by comparing the angle of tracheal bifurcation and TD/TI ratio in clinically healthy small-breed dogs and dogs with CDMD in various stages of heart failure.

MATERIALS AND METHODS

Case selection: The medical records of small-breed dogs (BW <10 kg) that were presented to National Taiwan University Veterinary Hospital between April 2009 and November 2011 were screened for this study.

Medical records review: The data obtained from the records included breed, sex, body weight, clinical signs, systolic blood pressure measurements, chest radiography, Electrocardiography (ECG) and

echocardiography (2D, M-mode and Doppler). All of the cases were required to have thoracic radiographs (both lateral and ventrodorsal views) and echocardiography (2D, M-mode and Doppler) to make diagnosis of TBC and/or CDMD.

Diagnostic criteria: The diagnosis of TBC was based on the measurement of the tracheal and bronchial diameters to the thoracic inlet distance ratio (TD/TI) from a lateral chest radiograph: TI was measured from the ventral aspect of the midpoint of the first thoracic vertebra to the dorsal surface of the manubrium at its minimal distance whereas the tracheal and bronchial intraluminal diameters (TD) were measured at 6 locations of the trachea and bronchi (i.e., cervical, thoracic inlet, thoracic, carina, right and left cranial lobar bronchi (RLB and LLB, respectively) and perpendicularly to the long axis of the trachea (Fig. 1) (Harvey and Fink, 1982). The ratio of TD/TI <0.16 at the thoracic inlet or the narrowest diameter of the trachea prior to the carina showing TD/TI<0.16 was considered a collapsed trachea (Harvey and Fink, 1982; Tangner and Hobson, 1982).

The Vertebral Heart Scale (VHS) was obtained from the right lateral thoracic radiographs using the method described by Buchanan and Bucheler. The reference range in this study was 9.2-10.2 vertebrae (Buchanan and Bucheler, 1995). The Tracheal Bifurcation angle (TB angle) was determined by the intersection of the lines positioned along the central axis of both of the stem bronchi in the left and right caudal lung lobes over their lengths (Fig. 2)

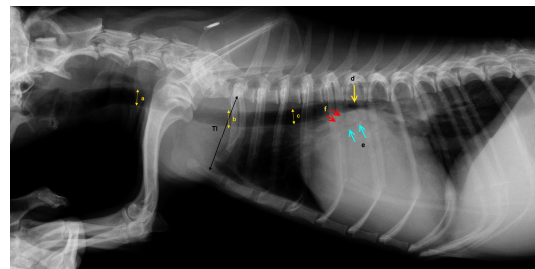


Fig. 1: The ratio of tracheal or bronchial diameters to thoracic inlet distance (TD/TI obtained from a dog with severe chronic degenerative mitral valvular disease classified as having heart failure based on the classification of the modified New York Heart Association group 4. The vertebral heart scale was 12.7 and the left atrium/aorta was 2.6. The tracheal or bronchial lumen diameters (TD) were measured at 6 locations of the trachea and bronchi: a) cervical; b) thoracic inlet; c) thoracic; d) carina; e) right cranial mainstem bronchus and f) left cranial mainstem bronchus

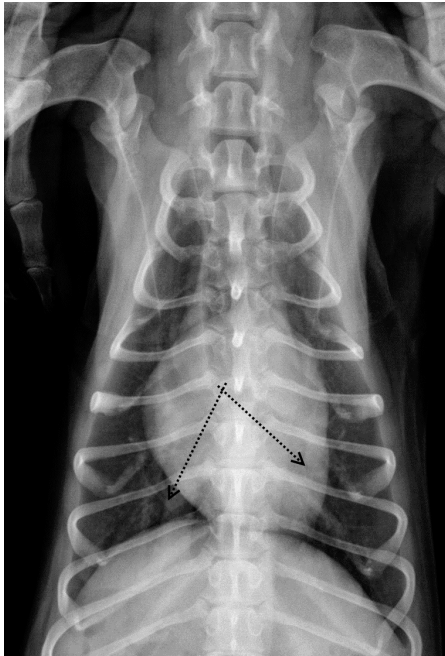


Fig. 2: An example of the tracheal bifurcation angle obtained from a dog with mild chronic degenerative mitral valvular disease classified as heart failure based on the classification of the modified New York Heart Association group 1. The vertebral heart scale was 9.5 and the left atrium/aorta was 1.38. The tracheal bifurcation angle of the dog was 75°

(Alavi *et al.*, 1970). All radiographic measurements were performed using the electronic calipers of the digital thoracic radiographic system.

The diagnosis of CDMD was based on the echocardiographic findings: club-like mitral leaflets with or without protrusion of the leaflets into the atrium according to the right parasternal long-axis view, Left Atrial/Aortic root ratio (LA/Ao) >1.6 and increased end-systolic dimension of LV with normal LV wall thickness (Olsen *et al.*, 2010). Echocardiography examinations were performed in a conscious status. All of the dogs were gently restrained in lateral recumbent positions using the 2D-guided M mode with ultrasound units equipped with 2-5 and 5-7.5 MHz transducers (MyLab™ 50 Family, Esaote, Genova, Italy). The echocardiographic indices including the Left Ventricular Dimension at the End-Diastole (LVEDD) and End-Systole (LVESD), thicknesses of the Left Ventricular Free Wall (LVFW) and Interventricular Septum (IVS) at the end-diastole, LA/Ao, Ejection Fraction (EF) and Fractional Shortening (FS) were measured from standard views

obtained from right parasternal images. The inflows of the trans-mitral and trans-tricuspid and flows of the pulmonary artery and aortic flow were measured from the left apical location. The mitral and tricuspid regurgitations were evaluated by a Doppler-derived echocardiography from the left apical location.

The owner's consent for each dog was obtained before all examinations were performed in the study. Based on the clinical signs and findings of the physical examinations and chest radiographs, the condition of heart failure was further classified based on a modified New York Heart Association (NYHA) functional classification system (Atkins *et al.*, 2009) (Table 1).

Statistical analysis: The data were expressed as the means±Standard Deviations (SDs). The Kolmogorov-Smirnov and Shapiro-Wilk tests were used for testing the normal distribution of all data with Commercial Computer Statistical Software (SPSS Version 12.0.1, Lead Technologies Inc., Charlotte, North Carolina, USA). The differences in the continuous variables between groups were evaluated by one-way Analysis of Variance (ANOVA) followed if necessary by a student's t-test with a Bonferroni correction. Where the data were not normally distributed, a Kruskal-Wallis test was used for analysis followed by a post hoc Mann-Whitney U-test. The comparison of frequencies was performed using a pearson χ^2 or Fisher's exact test. The pearson product moment and spearman rank order correlation coefficients (r) were used to assess the relationships between the variables. All tests were two-tailed. Significance was defined as a p<0.05.

RESULTS

Animals: The records of the small-breed dogs (BW<10 kg) that were presented to National Taiwan University Veterinary Hospital between April 2009 and November 2011 were screened for this study. One hundred and thirty three of these records including radiographic measurements of TD/TI, VHS and TB angle and echocardiographic evidence of CDMD were included in this study (CDMD group, Table 1). In this CDMD groups, the dogs were further categorized into 4 sub-groups based on the modified NYHA functional classification system (Table 2). The 54 records without a history of cardiopulmonary diseases included the radiographic measurements of TD/TI, VHS and TB angle and the CDMD cases that were excluded by echocardiographic evidence were included as healthy controls (Table 1). The age of the dogs was between

1 and 8 years. Their physical conditions were evaluated by annual wellness checkups and they were deemed clinically healthy.

No significant differences in sex distribution and body weight were found between the CDMD groups and healthy controls although the age of the healthy controls was significantly lower compared with the CDMD groups in the various modified NYHA classes ($p < 0.001$; Table 2).

Thoracic radiographic measurements: The prevalence of collapsed trachea defined at the thoracic inlet in the healthy controls and the dogs affected with CDMD was 22 and 28%, respectively ($p = 0.47$) whereas the prevalence of collapsed trachea defined at the location

prior to carina with TD/TI < 0.16 in the healthy controls and dogs affected with CDMD was 28 and 29%, respectively ($p = 0.52$). No significant differences in the TD/TI of the cervical, thoracic inlet, thoracic, carina and RLB and LLB were found among the healthy controls or the dogs with CDMD categorized in NYHA groups 1 and 2 whereas the TD/TI prior to carina and LMB of CDMD/NYHA groups 3 (carina/TI: 0.164 ± 0.051 ; LMB/TI: 0.078 ± 0.027) and 4 (carina/TI: 0.152 ± 0.043 ; LMB/TI: 0.069 ± 0.022) were significantly different ($p = 0.001$, $p < 0.001$, $p = 0.001$, $p < 0.001$, respectively) compared to those of the healthy control group (Table 3).

No significant differences at the 6 locations of TD/TI of the trachea and bronchi were found among the breeds of Chihuahuas, Maltese terriers, Miniature Poodles, Pomeranians or Yorkshire terriers of the healthy control group ($p > 0.20$). No significant correlation between the age of the healthy controls and the TD/TI at the 6 locations of the trachea and bronchi was found ($p > 0.30$).

In the right lateral radiographs, the VHS of CDMD/NYHA 4 (VHS: 12.0 ± 1.2) was significantly higher than for the healthy controls and CDMD/NYHA groups 1, 2 and 3 ($p < 0.001$) and the VHS of CDMD/NYHA groups 2 and 3 were significantly higher than those of the healthy controls ($p = 0.008$ and 0.002 , respectively; Table 3).

The TB angle in CDMD/NYHA group 4 ($93.2 \pm 6.4^\circ$) was significantly larger than in other the CDMD subgroups ($p < 0.001$) and the TB angle of CDMD/NYHA group 3 ($79.0 \pm 10.8^\circ$) was significantly larger than in the healthy controls ($65.7 \pm 8.7^\circ$, $p < 0.001$) and CDMD/NYHA group 1 ($66.7 \pm 7.9^\circ$, $p = 0.005$; Table 3).

In the dogs with CDMD, VHS was negatively correlated to carina/TI, RMB/TI and LMB/TI ($r = -0.29$, -0.31 and -0.24 , respectively; $p < 0.001$, $p < 0.001$ and $p = 0.002$, respectively) and LA/Ao was negatively correlated to carina/TI, RMB and LMB/TI ($r = -0.39$, -0.48 and -0.45 , respectively; $p = 0.003$, 0.001 and 0.001 , respectively). The TB angle was positively correlated to VHS and LA/Ao ($r = 0.26$ and 0.37 , respectively; $p = 0.002$ and 0.009 , respectively).

Table 1: Distribution of the breeds in clinically healthy small-breed dogs and dogs with Chronic Degenerative Mitral valvular Disease (CDMD) in various stages of heart failure based on the classification of the modified New York Heart Association (NYHA) System

Breeds	Healthy	NYHA 1	NYHA 2	NYHA 3	NYHA 4
Beagle	0	0	1	1	0
Chihuahua	6	0	3	4	4
French bulldog	1	0	0	0	0
Maltese terrier	18	9	10	20	5
Miniature Dachshund	1	0	1	2	0
Miniature pinscher	0	0	1	0	0
Miniature poodle	6	0	1	4	3
Miniature schnauzer	2	0	1	1	1
Mongrel	1	1	1	2	0
Pomeranian	8	8	5	6	2
Pug	1	0	0	1	0
Shih tzu	1	1	12	3	2
Yorkshire terrier	9	2	5	6	4
Total	54	21	41	50	21

Table 2: Patient characteristics of clinically healthy dogs and dogs with chronic degenerative mitral valvular disease in various stages of heart failure based on classification of the modified New York Heart Association (NYHA) System

Indices	Healthy (n = 54)	NYHA 1 (n = 21)	NYHA 2 (n = 41)	NYHA 3 (n = 50)	NYHA 4 (n = 21)
Age (years)	4.8 ± 2.3	$8.9 \pm 3.4^{\dagger}$	$11.8 \pm 3.4^{\dagger}$	$11.4 \pm 3.9^{\dagger}$	$11.2 \pm 3.0^{\dagger}$
Sex (female/male, %)	48	43	46	46	38
BW (kg)	3.8 ± 2.4	3.6 ± 2.4	3.9 ± 2.0	4.2 ± 2.5	4.3 ± 2.0
HR (beat per minute)	123 ± 35	122 ± 16	128 ± 25	134 ± 25	134 ± 18

Measurements are presented as mean \pm SD. $^{\dagger}p < 0.05$ relative to the healthy group

Table 3: Results of the ratio of tracheal or bronchial diameters to thoracic inlet distance (TD/TI) of the 6 locations (cervical, thoracic inlet, thoracic, carina and right and left main stem bronchi), Vertebral Heart Scale (VHS) and tracheal bifurcation angle and of clinically healthy small-breed dogs (the healthy controls) and dogs with chronic degenerative mitral valvular disease in different stages of heart failure based on the classification of the modified New York Heart Association (NYHA) System

Indices	Healthy (n = 54)	NYHA 1 (n = 21)	NYHA 2 (n = 41)	NYHA 3 (n = 50)	NYHA 4 (n = 21)
Cervical/TI	0.239 ± 0.063	0.247 ± 0.045	0.252 ± 0.067	0.247 ± 0.062	0.234 ± 0.052
Thoracic inlet/TI	0.197 ± 0.052	0.197 ± 0.043	0.200 ± 0.083	0.204 ± 0.049	0.198 ± 0.034
Thoracic/TI	0.205 ± 0.043	0.193 ± 0.030	0.186 ± 0.053	0.192 ± 0.032	0.182 ± 0.045
Carina/TI	0.196 ± 0.057	0.194 ± 0.037	0.180 ± 0.056	$0.164 \pm 0.051^{\dagger}$	$0.152 \pm 0.043^{\dagger}$
Left lobar bronchi/TI	0.098 ± 0.024	0.097 ± 0.027	0.087 ± 0.027	$0.078 \pm 0.027^{\dagger}$	$0.069 \pm 0.022^{\dagger}$
Right lobar bronchi/TI	0.099 ± 0.030	0.097 ± 0.036	0.094 ± 0.027	0.093 ± 0.032	0.073 ± 0.026
VHS	9.700 ± 0.800	10.200 ± 0.800	$10.500 \pm 1.100^{\dagger}$	$10.600 \pm 1.000^{\dagger}$	$12.000 \pm 1.200^{\dagger}$
Tracheal bifurcation (angle $^{\circ}$)	65.700 ± 8.700	66.700 ± 7.900	71.500 ± 11.30	$79.000 \pm 10.80^{\dagger}$	$93.200 \pm 12.35^{\dagger}$

Measurements are presented as mean \pm SD. $^{\dagger}p < 0.05$ versus the corresponding healthy group

Table 4: Echocardiographic indices in clinically healthy small breed dogs and dogs with Chronic Degenerative Mitral valvular Disease (CDMD in various stages of heart failure based on the classification of the modified New York Heart Association (NYHA) System

Indices	Healthy (n = 54)	NYHA 1 (n = 21)	NYHA 2 (n = 41)	NYHA 3 (n = 50)	NYHA 4 (n = 21)
LVEDD (mm)	19.1±4.300	19.8±3.800	21.8±3.900	23.3±2.700	30.2±5.700
LVEDD/Ao	1.41±0.98	1.70±0.33	1.99±0.27	2.02±0.24	2.83±0.43 [†]
LFWd (mm)	5.4±1.300	6.2±0.700	5.7±1.000	6.1±0.900	5.7±1.100
IVSd (mm)	4.7±0.800	5.7±0.600	6.2±0.800	5.8±0.800	5.8±0.700
EF (%)	74.7±9.400	79.0±6.000	77.8±7.800	79.1±6.100	77.6±6.200
FS (%)	43.1±9.500	45.0±6.000	45.2±7.600	47.3±6.200	47.8±5.500
LA/Ao	1.27±0.25	1.44±0.20	1.53±0.51	1.86±0.18 [†]	2.54±0.37 [†]
Mitral E/A	1.13±0.12	1.08±0.33	1.22±0.31	1.35±0.64	1.56±0.54
Tricuspid E/A	1.03±0.30	1.09±0.46	1.10±0.30	1.16±0.33	1.26±0.52
Aortic flow (m sec ⁻¹)	0.94±0.22	0.83±0.39	0.88±0.34	0.90±0.16	0.98±0.23
Pulmonary artery flow (m sec ⁻¹)	0.77±0.10	0.82±0.32	0.84±0.23	0.81±0.27	0.78±0.10
MR (m sec ⁻¹)	-	1.71±0.98	2.64±1.88	3.35±1.65	4.26±1.37
TR (m sec ⁻¹)	-	1.09±0.50	1.29±1.64	1.39±0.77	2.39±1.13

Indices values are presented as mean±SD. EF = Ejection Fraction; FS = Fractional Shortening; IVSd = Thickness of Interventricular Septum at end-diastole; LA/Ao = Left Atrial/Aortic root ratio; LVEDD = Left Ventricular dimension at End-Diastole; LVEDD/Ao = Left Ventricular Dimension at End-Diastole to aortic root ratio; LFWd = Thickness of Left Ventricular Free Wall at end-diastole; Mitral E/A = Mitral Early diastolic velocity/late diastolic velocity ratio; MR = Mitral Regurgitation; Tricuspid E/A = Tricuspid early diastolic velocity/late diastolic velocity ratio; TR = Tricuspid Regurgitation; [†]p<0.05 versus the corresponding healthy group

Echocardiography: The results of the 2D echocardiographic indices are presented in Table 4. The left ventricular diameter and wall thickness, EF and FS were not significantly different among the healthy controls and groups of the 4 stages of NYHA classification. However, the Left Ventricular Diameter to aortic root Diameter ratio (LVEDD/Ao) of CDMD/NYHA group 4 was significantly higher compared with the dogs in the other groups (p<0.003). The LA/Ao of CDMD/NYHA group 4 was significantly higher than in the other groups (LA/Ao = 2.54±0.37, p<0.001). In CDMD/NYHA group 3, the LA/Ao was significantly higher than in CDMD/NYHA group 1 and the healthy controls (p = 0.041 and p = 0.026, respectively).

In the Doppler hemodynamic assessment, no statistical significance of the mitral E/A, tricuspid E/A or aortic and pulmonary artery flow velocities was found among the healthy controls and dogs in the CDMD/NYHA groups 1-4. The mitral and tricuspid regurgitation velocity was not significantly different among the CDMD subgroups.

DISCUSSION

Chronic airflow limitation and reduced lung function have been demonstrated as independent causal factors for cardiovascular diseases in numerous large-scale epidemiological studies of human patients (Georgiopoulou *et al.*, 2011; Sin *et al.*, 2005). In this study, although, the prevalence of TBC was slightly higher in dogs with various severities of CDMD, no significant difference was found between the healthy controls and dogs with CDMD.

The prevalence of TC in small-breed dogs has been reported to be between 0.5-2.9% (Lund *et al.*, 2006;

Marolf *et al.*, 2007). In dogs with respiratory illness, the bronchoscopic prevalence of TBC and bronchial collapse is higher and the rates are 21 and 30%, respectively (Johnson and Pollard, 2010). Radiography has been reported as a diagnostic modality for dogs with TC and collapsed main bronchi but the sensitivity and specificity varied with the position of the collapsed trachea and the degree to which the dynamic tracheal luminal changed during tidal respiration and even underestimate the prevalence of TC (Leonard *et al.*, 2009; Macready *et al.*, 2007). In this study, TC was defined using carina TD/TI <0.16 radiographically (Harvey and Fink, 1982; Tangner and Hobson, 1982). Cases with a mild degree of tracheal luminal changes that are affected by a respiratory pattern during the radiographs can be underestimated. Nonetheless, the prevalence of TC in clinically healthy dogs and dogs affected with CDMD was higher than the results reported by previous studies. The high prevalence of TC in both groups might simply reflect the popularity of the breeds included in this area and Maltese terriers, Pomeranians, Yorkshire terriers, Shih Tzu, Chihuahuas and miniature poodles, accounted for 89% of the cases in this study (Macready *et al.*, 2007; Marolf *et al.*, 2007).

In this study, the TD/TI of the cervical, thoracic inlet and thoracic levels was not significantly different between the healthy controls and dogs with CDMD for all 4 NYHA classifications. No statistical correlation was found between the left ventricular echocardiographic indices and the TD/TI at the cervical, thoracic inlet and thoracic levels. These findings suggest that TC was not associated with the high prevalence and severity of CDMD in small-breed dogs. However, TD/TI prior to carina and LLB in CDMD/ NYHA groups 3 and 4 was significantly reduced compared to those of the healthy controls. Both VHS and echocardiographic LA/Ao had

significantly negative correlations with the prior to carina TD/TI, RLB/TI and LLB/TI. The TB angle in CDMD/NYHA groups 3 and 4 was significantly higher than those in the healthy controls. The TB angle was positively correlated to VHS and LA/Ao. The dorsal elevation of the trachea and carina and the dorsal displacement of the left lobar bronchus by the enlarged left atrium and left ventricle on the lateral radiographs have been widely applied as indicators of CDMD (Poteet, 2008). The compression of the bronchus in dogs with CDMD was believed to be associated with the enlarged left atrium and the degree of the compression was related to the severity of CDMD in this study.

Bronchoscopic evidence suggested that the left cranial bronchus was the most frequently affected location of bronchomalacia (i.e., bronchial collapse) (Adamama-Moraitou *et al.*, 2012; De Lorenzi *et al.*, 2009; Johnson and Pollard, 2010). The investigation on the development and location of bronchomalacia in dogs with no/mild and moderate/severe left atrial enlargement caused by CDMD indicated that the dorsal and ventral segments of the left cranial lobar bronchus were affected most frequently followed by the left caudal and right middle lobar bronchi. However, there were no significant differences in the sites or severity of the airway collapses between dogs that were affected with no/mild and moderate/severe left atrial enlargement (Singh *et al.*, 2012). These findings do not support that the left and right bronchi are compressed by the subjacent dilated left atrium secondary to the progression of CDMD. Conversely, bronchomalacia has been reported to occur in 87.5% of brachycephalic dogs with respiratory distress and noisy breathing, generally at an age of <3 years. The prevalence of TC in brachycephalic breeds has been found to be higher than the prevalence in other breeds (30%) (De Lorenzi *et al.*, 2009; Johnson and Pollard, 2010). Narrowing or compressed left cranial bronchi may also be contributed to other factors such as age, body weight and inflammatory conditions (Adamama-Moraitou *et al.*, 2012; De Lorenzi *et al.*, 2009). In this study, there were no significant differences in the TD/TI of the trachea and bronchi among the 5 predisposed breeds in the group of healthy controls and there were no significant correlations regarding age in the healthy controls. The results in this study indicated that the anatomical link to the heart might be related to the compression of the carina and bronchus.

CONCLUSION

This study failed to identify increased prevalence of TBC in dogs with CDMD and did not find significant differences in the trachea diameters among the healthy

controls and dogs with CDMD/NYHA in groups 1-4, despite high comorbidity being subjectively observed between CDMD and TBC in the small-breed dogs. These results implied that CDMD is not associated with preexisting TC in dogs. The compression of the carina and bronchus in dogs with CDMD only developed where the anatomical regions were related to the left atrium. The degree of carinal and bronchial compression was associated with the severity of CDMD.

LIMITATION

There were limitations to the study. No bronchoscopic determinations of tracheobronchial diameters were applied to the dogs in this study and all the dogs were client-owned. The influence of TBC on heart functions may not be entirely elucidated using the conventional assessments of echocardiography and future studies regarding the evaluation of cardiac function should use various echocardiographic analyses for dogs with respiratory disorders.

ACKNOWLEDGEMENTS

The researchers thank the Consulting Center for Statistics and Bioinformatics, College of Bio-Resources and Agriculture, National Taiwan University for assistance with the statistical analyses.

REFERENCES

- Adamama-Moraitou, K.K., D. Pardali, M.J. Day, N.N. Prassinou and M. Kritsepi-Konstantinou *et al.*, 2012. Canine bronchomalacia: A clinicopathological study of 18 cases diagnosed by endoscopy. *Vet. J.*, 191: 261-266.
- Alavi, S.M., T.E. Keats and W.M. O'Brien, 1970. The angle of tracheal bifurcation: its normal mensuration. *Am. J. Roentgenol.*, 108: 546-549.
- Atkins, C., J. Bonagura, S. Ettinger, P. Fox and S. Gordon *et al.*, 2009. Guidelines for the diagnosis and treatment of canine chronic valvular heart disease. *J. Vet. Internal Med.*, 23: 1142-1150.
- Borgarelli, M. and J.W. Buchanan, 2012. Historical review, epidemiology and natural history of degenerative mitral valve disease. *J. Vet. Cardiol.*, 14: 93-101.
- Buchanan, J. and J. Bucheler, 1995. Vertebral scale system to measure canine heart size in radiographs. *J. Am. Vet. Med. Assoc.*, 206: 194-199.
- Chiavegato, D., M. Borgarelli, G. D'Agnolo and R.A. Santilli, 2009. Pulmonary hypertension in dogs with mitral regurgitation attributable to myxomatous valve disease. *Vet. Radiol. Ultrasound*, 50: 253-258.

- Dabanoglu, I., M. Ocal and M. Kara, 2001. A quantitative study on the trachea of the dog. *Anat. Histol. Embryol.*, 30: 57-59.
- Dallman, M., R. McClure and E. Brown, 1985. Normal and collapsed trachea in the dog: Scanning electron microscopy study. *Am. J. Vet. Res.*, 46: 2110-2115.
- Dallman, M., R. McClure and E. Brown, 1988. Histochemical study of normal and collapsed tracheas in dogs. *Am. J. Vet. Res.*, 49: 2117-2125.
- De Lorenzi, D., D. Bertonecello and M. Drigo, 2009. Bronchial abnormalities found in a consecutive series of 40 brachycephalic dogs. *J. Am. Vet. Med. Assoc.*, 235: 835-840.
- Ettinger, S.J., 2010. Diseases of the Trachea and Upper Airways. In: *Textbook of Veterinary Internal Medicine: Diseases of the Dog and the Cat*, Ettinger, S.J. and E.C. Feldman (Eds.). Saunders, St. Louis, pp: 1066-1088.
- Georgiopoulou, V.V., A.P. Kalogeropoulos, B.M. Psaty, N. Rodondi and D.C. Bauer *et al.*, 2011. Lung function and risk for heart failure among older adults: The health ABC study. *Am. J. Med.*, 124: 334-341.
- Harvey, C. and E. Fink, 1982. Tracheal diameter: Analysis of radiographic measurements in brachycephalic and nonbrachycephalic dogs. *J. Am. Anim. Hosp. Assoc.*, 18: 570-576.
- Johnson, L., 2000. Tracheal collapse. Diagnosis and medical and surgical treatment. *Vet. Clin. North. Am. Small. Anim. Pract.*, 30: 1253-1266.
- Johnson, L., J. Boon and E.C. Orton, 1999. Clinical characteristics of 53 dogs with Doppler-derived evidence of pulmonary hypertension: 1992-1996. *J. Vet. Intern. Med.*, 13: 440-447.
- Johnson, R.L., and R.E. Pollard, 2010. Tracheal collapse and bronchomalacia in dogs: 58 cases (7/2001-1/2008). *J. Vet. Intern. Med.*, 24: 298-305.
- Le Roux, A., N. Rademacher, C. Saelinger, D. Rodriguez and R. Pariaut *et al.*, 2012. Value of tracheal bifurcation angle measurement as a radiographic sign of left atrial enlargement in dogs. *Vet. Radiol. Ultrasound*, 53: 28-33.
- Leonard, C.D., L.R. Johnson, C.M. Bonadio and R.E. Pollard, 2009. Changes in tracheal dimensions during inspiration and expiration in healthy dogs as detected via computed tomography. *Am. J. Vet. Res.*, 70: 986-991.
- Lord, P., K. Hansson, C. Kvarn and J. Haggstrom, 2010. Rate of change of heart size before congestive heart failure in dogs with mitral regurgitation. *J. Small Anim. Pract.*, 51: 210-218.
- Lund, E.M., P.J. Armstrong, C.A. Kirk and J.S. Klausner, 2006. Prevalence and risk factors for obesity in adult dogs from private US veterinary practices. *Int. J. Applied Res. Vet. Med.*, 4: 177-186.
- Macready, D.M., L.R. Johnson and R.E. Pollard, 2007. Fluoroscopic and radiographic evaluation of tracheal collapse in dogs: 62 cases (2001-2006). *J. Am. Vet. Med. Assoc.*, 230: 1870-1876.
- Marolf, A., M. Blaik and A. Specht, 2007. A retrospective study of the relationship between tracheal collapse and bronchiectasis in dogs. *Vet. Radiol. Ultrasound*, 48: 199-203.
- Olsen, L.H., J. Haggstrom and H.D. Petersen, 2010. Acquired Valvular Heart Disease. In: *Textbook of Veterinary Internal Medicine: Diseases of the Dog and the Cat*, Ettinger, S.J. and E.C. Feldman (Eds.). Saunders, St. Louis, pp: 1299-1319.
- Poteet, B.A., 2008. Radiology of the Heart. In: *Manual of Canine and Feline Cardiology*, Tilley, L.P. (Eds.). Saunders, St. Louis, pp: 24-48.
- Pyle, R.L., J. Abbott and H. MacLean, 2004. Pulmonary hypertension and cardiovascular sequelae in 54 dogs. *Internal J. Appl. Res. Vet. Med.*, 2: 99-109.
- Serres, F.J., V. Chetboul, R. Tissier, C.C. Sampedrano and V. Gouni *et al.*, 2006. Doppler echocardiography-derived evidence of pulmonary arterial hypertension in dogs with degenerative mitral valve disease: 86 cases (2001-2005). *J. Am. Vet. Med. Assoc.*, 229: 1772-1778.
- Sin, D.D., L.L. Wu and S. Man, 2005. The derived evidence of pulmonary function and cardiovascular mortality. *Chest*, 127: 1952-1959.
- Singh, M., L. Johnson, M. Kittleson and R. Pollard, 2012. Bronchomalacia in dogs with myxomatous mitral valve degeneration. *J. Vet. Internal Med.*, 26: 312-319.
- Tangner, C. and H. Hobson, 1982. A retrospective study of 20 surgically managed cases of collapsed trachea. *Vet. Surg.*, 11: 146-149.