

Treatment of Naturally Occurring Squamous Cell Carcinomas with Mixed Therapy Plus Tetracycline in Dogs

¹O.M. Elitok, ²B. Elitok and ³H. Yuksel

¹Agriculture and Rural Development Support Agency, Afyonkarahisar, Turkey

²Department of Internal Medicine, Faculty of Veterinary Medicine,
Afyon Kocatepe University, Afyonkarahisar, Turkey

³Vocational School of Health Services, Bingol University, Bingol, Turkey

Abstract: The objectives of this study were to determine the possible effects of mixed therapy plus the application of tetracycline on Squamous Cell Carcinomas (SCC) in dogs. Ten Anatolian shepherd dogs (Kangal dogs) with naturally occurring SCC were treated with Tetracycline (TC) both topically and parenterally. TC was applied topically in a zinc pomade with miscellaneous agents including salicylic acid betamethasone and zinc oxide plus vaseline and parenterally via intravenous injection at a dose of 3 mL/kg/day for 10 days. The healing effects of this treatment procedure were measured by histopathological observations. At the end of 3 weeks, three dogs (30%) showed significant improvement and no tumor recurrence after treatment.

Key words: Treatment, Squamous Cell Carcinoma (SCC), canine, Tetracycline (TC), vaseline

INTRODUCTION

Squamous Cell Carcinoma (SCC) is a malignant tumor of squamous epithelium (epithelium that shows squamous cell differentiation) and a form of carcinomatous cancer occurs in many different organs, including the skin, lips, mouth, esophagus, urinary bladder, prostate, lungs, vagina and cervix (Beck, 1992; Boonkitticharoen *et al.*, 1997; Head, 1990; Todoroff and Brodey, 1979). Despite having a common name these cancers are unique, each with a different manifestation and prognosis (Boonkitticharoen *et al.*, 1997; Chang *et al.*, 1998; Chenau *et al.*, 2009). Though, SCC can generally be treated by excision or surgery, nonsurgical treatment options of cutaneous SCC include topical chemotherapy, topical immune response modifiers, photodynamic therapy, radiotherapy and systemic chemotherapy (Bellnier *et al.*, 1993; He *et al.*, 2008; Magne *et al.*, 1997; Payne *et al.*, 1996). The use of topical therapy and PDT is generally limited to premalignant and *in situ* lesions (McCaw *et al.*, 2000; Meyer *et al.*, 1991; Peaston *et al.*, 1993; Wenig *et al.*, 1990). Additionally, radiation therapy is the primary treatment option for patients for whom surgery is not feasible and it is an adjuvant therapy for patients with metastatic or high-risk cutaneous SCC. At this time, systemic chemotherapy with different drugs is

used exclusively for patients with metastatic disease (Jerant *et al.*, 2000; Mcleay and Walske, 1962; Motley *et al.*, 2002; Stulberg *et al.*, 2004; Tang *et al.*, 2009).

This study was undertaken to determine the effectiveness of treating naturally occurring skin SCCs in dogs using tetracycline. Recent studies have shown that Tetracycline (TC) compounds can be effective on gene expression system which is responsible for carcinogenesis. Furthermore, TC has been shown to inhibit angiogenesis in both humans and animal models (Donsky, 1965; McLeay and Walske, 1962). SCC of the skin is also one of the most common skin cancer problems among Turkish Kangal dogs in the Afyonkarahisar Province of Turkey. In this study, 10 Kangal dogs with SCC of the skin were studied to evaluate both the systemic and topical administration of TC along with a zinc pomade with miscellaneous agents, including salicylic acid for healing malignancy.

MATERIALS AND METHODS

The study was conducted on 10 client-owned Kangal dogs in Afyonkarahisar Province. The 6 male (n = 6) and 4 female (n = 4) Kangal dogs (body weight 43-68 kg, age 3-8 years) with naturally occurring SCC were treated.

According to owners information, the symptoms of the disease began 3-8 months after their purchase from different areas of Turkey. Throughout the study, the dogs were maintained in the same field conditions were allowed to eat their regular diet including chicken meat, bread and milk and did not receive any type of medication or nutritional supplements.

Diagnosis of SCC

Source of samples: Tissue samples were surgically collected from the lesions on the skin to be examined for tumor cells. Both obtaining and measuring samples were accomplished under pre-anaesthesia which consisted of administering atropine and xylazine as pre-anaesthetic agents. Tissue samples were stored in 10% buffered formalin solution.

Histopathology: All the dogs had histopathologic evidence of tumors and all tumors were histopathologically confirmed to be SCCs. The tumors had been detected 3-8 months prior to presentation and none of the tumors had been locally excised during that period. Physical and laboratory examinations indicated that neither the spread of tumors from their local areas nor organ failure would limit any of the dogs' lifespans. All tumors were thicker than 1 cm. The diameters of tumoral formations were measured with the help of a caliper after the tumoral area had been cleaned and shaven (McCaw *et al.*, 2000).

Treatment procedures: Oxytetracycline (30mg)-Polimycin B (10000 units) (Terramycin skin ointment-Pfizer Turkey) along with enjectable tetracycline (Pan-Terramycin Enjectable-Pfizer Turkey).

Having cleaned and dried the areas to be treated, TC along with miscellaneous agents listed below were generously applied topically until the skin was thoroughly wet. The mixed solution was applied twice daily, once in the morning and once in the evening for 3 weeks. All animals were also treated with tetracycline Subcutaneously (SC) at a single dose of 3 mL/kg/day for 10 days. The following miscellaneous topical agents were used for 3 weeks:

- Salicylic acid 5% pomade plus 1 mg mometazon furoat (Momesalic pomad-Bilim Ilac-Turkey)
- Betamethasone 0.1% (Dermakord 20 g, Deva-Turkey)
- Zinc oxyde 10% plus vaseline 90% (Oxid de Zinc pomad, Lokman-Turkey)

RESULTS AND DISCUSSION

Tissues obtained from the lesions stained with Hematoxylin-Eosin (HE) were reviewed under a light microscope. Best differentiated eosinophilic cytoplasm of tumor cells in the microscopic dermal stroma grown right in the dermis in the center of the islets of keratinization (keratin pearls) was formed. A small number of mitotic figures in tumor cells were encountered. Keratin pearl formation between the dermis with the formation of new blood vessels contained the majority of inflammatory cells consisting of macrophages and neutrophil leukocytes (Fig. 1).

Where located, tumors could be easily treated by TC therapy. Therefore, the dogs with SCC were good candidates for topical application of TC along with the zinc pomade. In this study, most lesions clearly began to heal by week 3 in three animals (30%) after treatment and continued during this study.

Two dogs (20%) were sent to another city 300 km far from Afyonkarahisar Province in consequence of some reasons. One of them was reported to have healed significantly after 6 months (we did not consider this dog as among the recovered animals for we could not see him) while the other ones were dead. Other two dogs (20%) showed no apparent benefit from TC 2 months after treatment, they showed recurrence or residual tumors and were euthanized. At the end of 3rd month after treatment, the other three dogs were also dead.

The results of this study confirmed that the affinity of TCs for tumor tissue and indicated that the systemic administration of these compounds was a reliable and reproducible method for the treatment of squamous cell carcinoma located on the skin. Although, McLeay *et al.* (1962) reported that no clinical effect of TC concentrated

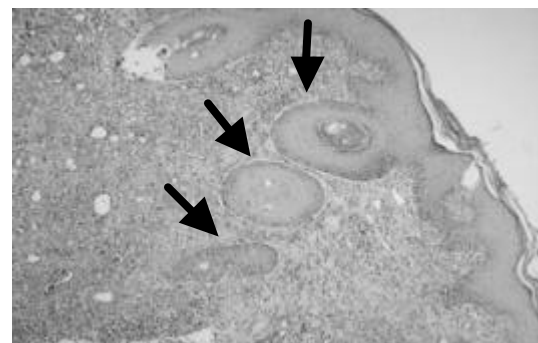


Fig. 1: Arrows indicate well-differentiated Squamous Cell Carcinoma (SCC) in the dermis keratin pearl formation; HEx400

in tumors was observed, a study by Vassar *et al.* (1960) using an ultraviolet light microscope indicated that TC was sequestered extracellularly by tumor tissue.

Preliminary ultraviolet microscopic slides seem to delineate TC in the cytoplasm of tumor cells (Magne *et al.*, 1997). Fluorescence was seen up to 10 days after discontinuing administration of the drug. Beyond this period, the intensity of fluorescence faded. After fluorescence had disappeared, biological assays indicated that TC was still present within the tumor but to a lesser degree (McLeay and Walske, 1962).

Neither metastasized nor systemic tumor effects were observed during the study was a remarkable find treatment with TC plus the other drugs. Recent studies have shown that TC compounds could be effective on gene expression system which is responsible for carcinogenesis. Furthermore, tetracycline has been shown to inhibit angiogenesis in both humans and animal models. It is possible mechanism for these effects may be the specific targeting of adherens junctions by tetracycline, inducing the expression of VE-cadherin and decreasing its phosphorylation on the membranes of endothelial cells (Fainaru *et al.*, 2008).

TC mixed therapy of dogs indicates that tumor response is similar to response in humans (Beck, 1992). It might also describe the development of a doxycycline-inducible recombinant plasmid (pBPSTR3-FlagX) with the full-length *HBV X* gene and all components of the tetracycline-on ("*Tet-on*") gene expression system (Tang *et al.*, 2009). It characterized the p53-dependent secretome of a lung tumor model *in vitro* (H358 human nonsmall cell lung adenocarcinoma cell line with a homozygous deletion of p53) and demonstrates that the modulation of exported proteins can also be detected *in vivo* in the plasma of tumor-bearing mice. It used a clone of H358 that had been stably transfected with a tetracycline-inducible wild-type p53-expressing vector. Using iTRAQ labeling and LC-MALDI-MS/MS analysis, researchers identified 909 proteins released *in vitro* by the cells, 91 of which are p53-modulated. Three proteins (GDF-15, FGF-19 and VEGF) were also investigated in H358/TetOn/p53 xenograft mice (Chenau *et al.*, 2009).

In other studies, researchers (Grant *et al.*, 1997) have claimed that photodynamic therapy was an effective but non-selective treatment for superficial cancers of the oral cavity.

CONCLUSION

Although, the value of this procedure remains limited since the tumor must be superficially located in the skin,

the results of this study confirm the affinity of TCs for tumor tissue and indicated that the systemic and topical administration of these compounds was a reliable and reproducible technique for the treatment of squamous cell carcinoma of the skin.

REFERENCES

- Beck, E.R., 1992. Lasers in Veterinary Oncology. In: Current Veterinary Therapy XI: Small Animal Practice, Bonagura, J.D. (Ed.). WB Saunders, Philadelphia, PA., USA., ISBN-13: 978-0721632933, pp: 414-418.
- Bellnier, D.A., B.W. Henderson, R.K. Pandey, W.R. Potter and T.J. Dougherty, 1993. Murine pharmacokinetics and antitumor efficacy of the photodynamic sensitizer 2-[1-hexyloxyethyl]-2-devinyl pyropheophorbide-a. J. Photochem. Photobiol. B: Biol., 20: 55-61.
- Boonkitticharoen, V., B. Kulapaditharom, S. Punnachaiya and P. Kraiphikul, 1997. Differences in *in vitro* photodynamic sensitivity among head and neck cancers. Lasers Med. Sci., 12: 274-279.
- Chang, C.J., Y.L. Lai and C.J. Wong, 1998. Photodynamic therapy for facial squamous cell carcinoma in cats using Photofrin. Changcheng Yi Xue Za Zhi, 21: 13-19.
- Chenau, J., S. Michelland, F. de Fraipont, V. Jossierand, J.L. Coll, M.C. Favrot and M. Seve, 2009. The cell line secretome, a suitable tool for investigating proteins released *in vivo* by tumors: Application to the study of p53-modulated proteins secreted in lung cancer cells. J. Proteome Res., 8: 4579-4591.
- Donsky, H.J., 1965. Tetracycline fluorescence in squamous cell carcinoma. Arch. Dermatol., 92: 388-393.
- Fainaru, O., I. Adini, O. Benny, L. Bazinet, E. Pravda, R. D'Amato and J. Folkman, 2008. Doxycycline induces membrane expression of VE-cadherin on endothelial cells and prevents vascular hyperpermeability. FASEB J., 22: 3728-3735.
- Grant, W.E., P.M. Speight, C. Hopper and S.G. Bown, 1997. Photodynamic therapy: An effective, but non-selective treatment for superficial cancers of the oral cavity. Int. J. Cancer, 71: 937-942.
- He, X.S., M. Deng, S. Yang, Z.Q. Xiao and Q. Luo *et al.*, 2008. The tumor suppressor function of STGC3 and its reduced expression in nasopharyngeal carcinoma. Cell. Mol. Biol. Lett., 13: 339-352.
- Head, K.W., 1990. Tumours of the Alimentary Tract. In: Tumors in Domestic Animals, Moulton, J.E. (Ed.). 3rd Edn., University of California Press, Berkeley, CA., USA., ISBN-13: 9780520058187, pp: 347-428.

- Jerant, A.F., J.T. Johnson, C.D. Sheridan and T.J. Caffrey, 2000. Early detection and treatment of skin cancer. *Am. Fam. Physician.*, 62: 357-368.
- Magne, M.L., C.O. Rodriguez, S.A. Autry, B.F. Edwards, A.P. Theon and B.R. Madewell, 1997. Photodynamic therapy of facial squamous cell carcinoma in cats using a new photosensitizer. *Lasers Surg. Med.*, 20: 202-209.
- McCaw, D.L., E.R. Pope, J.T. Payne, M.K. West, R.V. Tompson and D. Tate, 2000. Treatment of canine oral squamous cell carcinomas with photodynamic therapy. *Br. J. Cancer*, 82: 1297-1299.
- McLeay, J.F. and B.R. Walske, 1962. Relationship of tetracycline to carcinoma. *Annals Surg.*, 156: 313-317.
- Meyer, M., P. Speight and S.G. Bown, 1991. A study of the effects of photodynamic therapy on the normal tissues of the rabbit jaw. *Br. J. Cancer*, 64: 1093-1097.
- Motley, R., P. Kersey and C. Lawrence, 2002. Multiprofessional guidelines for the management of the patient with primary cutaneous squamous cell carcinoma. *Br. J. Dermatol.*, 146: 18-25.
- Payne, J.T., D.L. Mccaw, S.W. Casteel, D. Frazier, K. Rogers and R.V. Tompson, 1996. Pharmacokinetics of pyropheophorbide-a-hexyl ether in the dog. *Lasers Surg. Med.*, 18: 406-409.
- Peaston, A.E., M.W. Leach and R.J. Higgins, 1993. Photodynamic therapy for nasal and aural squamous cell carcinoma in cats. *J. Am. Vet. Med. Assoc.*, 202: 1261-1265.
- Stulberg, D.L., B. Crandell and R.S. Fawcett, 2004. Diagnosis and treatment of basal cell and squamous cell carcinomas. *Am. Fam. Physician.*, 70: 1481-1488.
- Tang, H., L. Liu, F.J. Liu, E.Q. Chen and S. Murakami *et al.*, 2009. Establishment of cell lines using a doxycycline-inducible gene expression system to regulate expression of hepatitis B virus X protein. *Arch. Virol.*, 154: 1021-1026.
- Todoroff, R.J. and R.S. Brodey, 1979. Oral and pharyngeal neoplasia in the dog: A retrospective survey of 361 cases. *J. Am. Vet. Med. Assoc.*, 175: 567-567.
- Vassar, P.S., A.B. Saunders and C.F. Collene, 1960. Tetracycline fluorescence in malignant tumors and benign ulcers. *Arch. Path.*, 60: 613-616.
- Wenig, B.L., D.M. Kurtzman, L.I. Grossweiner, M.F. Mafee and D.M. Harris *et al.*, 1990. Photodynamic therapy in the treatment of squamous cell carcinoma of the head and neck. *Arch. Otolaryngol. Head Neck Surg.*, 116: 1267-1270.