

Evaluation of Pinhole Castration Technique in Iraqi Black Local Breed Bucks: Morphological and Histological Assessment

¹T.A. Abid and ²E.F. Al-Baghdady

¹Department of Surgery and Obstetrics, ²Department of Anatomy and Histology,
College of Veterinary Medicine, University of Al-Qadissiya, Diwanyia, Iraq

Abstract: The study aim to assessment the effectiveness of pinhole castration in bucks. Fifteen male kids of black local breed goat 4 months old were utilized. One testis (right) of each animal was castrated by pinhole castration technique (ligation of the spermatic cord at the neck of scrotum through a hypodermic needle while the knot burred subcutaneously) after injection of 2 mL lidocaine. The left testis left uncastrated as control. Close clinical observations of animals immediately and through 1 month were done to investigate the presence of pain and complications. All animals were subjected to bilateral orchiectomy after 1 month, to evaluate the viability of the testicular tissue macroscopically and Histological examinations. The result reveals that the technique was quick and takes short time to perform with less discomfort after operation. The ligated testis seen smaller than control with no pain during palpation. After orchiectomy the ligated testis characterized by firm texture with the adhesions between its tunica and show significantly $p < 0.05$ decrease in length and girth. Histologically, massive destruction of the cellular tissue was seen with the complete hyalinization of the seminiferous tubules with no signs of spermatogenesis. The interstitial tissue replaced by thick layer of fibrous tissue with no Ledge cells. In conclusion, researchers approve to use this technique of castration in bucks since, it was simple, easy to perform, economic and it can be used in the field when the conventional tools of castration not available.

Key words: Castration, pinhole castration, goat, buck, morphological, histological assessment

INTRODUCTION

Castration of the male animals is the removal of the testicles or making the testis nonfunctional insitue. It performed to stop the production of the male androgen hormones and spermatogenesis (Baird and Wolfe, 1998; Gilbert and Fubini, 2004), for decrease the aggressiveness activities of the animals and make them docile and easier to handle and also prevent the unwanted mating and mounting activities and injuries accompanied or for testicular or inguinal pathology (Searle *et al.*, 1999; Price *et al.*, 2005; Edwards, 2008) where in meat production animals are used to improvement of meat quality and taste, improvement in feed efficiency, reduction in male aggressive behavior (Thompson, 2000; Anderson, 2007) and in goat prevent unwanted breeding result in genetic defect, unwanted pregnancies, enhance management weight development and reduce male associated odors and goaty smell in the meat (Merkel and Dawson, 2008).

Male goat has strong smell (buck odors) during the breeding season, due to the effect of the androgen hormones on special glands on skin, cornual gland area

and nose. The taste of meat also affected and differed than castrated animals (Van Lancker *et al.*, 2005). Many techniques are used to induce castration depending on the species of the animals, the anatomy of the testes, the age of the animals, the purpose to use and whether the testis is normal or sick. The conventional techniques include physical methods result in removal, irreversible damage or destruction of the testis such as application of elastrator bands or rubber rings, use of Burdizzo clamp and surgical removal (by open, closed or modified closed techniques) (Kent *et al.*, 1996; Coetzee *et al.*, 2010).

Chemical methods of castration (chemo sterilization) include injection of sclerosing or toxic agents in the testicular parenchyma (Al-Kadi, 2008; Jana *et al.*, 2005; Al-Asadi and Al-Kadi, 2012) and hormonal approaches to castration (immunocastration) in which immunization against Gonadotrophin-Releasing Hormone (GnRH) or Luteinizing Hormone Releasing Hormone (LHRH) were performed to induce antibody against GnRH resulting in decrease production of endogenous hormones (Godfrey *et al.*, 1996; Thompson, 2000; Cui *et al.*, 2003; Ulker *et al.*, 2009). Each one of these techniques has

advantages and disadvantages and recently many development were appear to simplified the technique and or to avoid the castration by routine surgical operation with its complication and reduce the pain during and post castration and make the technique economically more applicable such as pinhole castration (Ponvijay, 2007; Fazili *et al.*, 2009), ligation of spermatic cord (Al-Kadi, 2008), spermatic cord torsion (Munahi and Abid, 2011).

The study was aimed to assessment the application of pinhole castration technique in bucks as an alternative techniques replacing the conventional castration techniques used in these animals.

MATERIALS AND METHODS

Fifteen healthy male kids of black local breed goats 4 months old were utilized in this experiment. Animals clinically examined and should have both normal testicles descended in the scrotum. The right testis of each animal was castrated via pinhole castration technique described by Ponvijay (2007) while the left one was left uncastrated as control (same animal's control).

An assistant were restrained animals in lateral recumbency. The neck of scrotum were prepared for aseptic surgical by scrubbing with povidone iodine and anesthetized by injection of 2 mL of lidocaine. Percutaneous spermatic cord ligation of the right testis using Ponvijay technique were applied using 18 gage hypodermic needle and 0 catgut for ligature where the Knot's buried subcutaneously via push through the needle puncture hole. The time of operation was recorded.

Close immediate clinical observations of animals and through the first 24 h. After castration including the observation of signs of pain, discomfort, scrotal swelling or any complications if present (Molony *et al.*, 1995; Thornton and Waterman-Pearson, 1999).

After 1 month of castration, bilateral closed orchietomy (Hendrickson, 2007) above the site of ligation were done in all animals. Operated testicles were examined grossly for an abnormal lesions or adhesions and testicular measurements (length and girth) were taken. The testicles were fixed in 10% buffered formalin. Autopsy were taken, sectioned and stained with H&E stain for histological examinations.

RESULTS

The technique was seen simple, easy and quick. For each testis it takes only 1-2 min to performed when the animal on lateral recumbency. Closed observations were revealed mild discomfort, several minutes (10-15) after

application of ligation. These discomforts include vocalization, head turning, tail wagging and foot stamping. These sings were disappearing half an hour later.

On ligated testis, no hemorrhage, no infection, no swelling and no larval infestation were seen through the 1 month the time of observation. At the end of the month, the ligated testis from outside seen less small than the control one and no scrotal pain during palpation of testis. The site of ligation were felt as a ring like depression at the neck of scrotum in eleven out of fifteen testis while the other four felt resemble the control one.

The macroscopic examination of the orchide testis after surgical removal explore an adhesions between tunica durtus and tunica vaginalis in ligated testis make it difficult to detached further to marked atrophy with firm tincture compared with the control. After cutting the ligated testis seen hard and fibrosed.

The testicular length and girth significantly decreased $p \leq 0.05$ compared with the control (Table 1, Fig. 1).

Histologically, there was massive destruction of the cellular structure of the testis. The seminiferous tubules was seen less in number and its lining cells appear suffering from coagulative necrosis with desecumation in the lumen of the tubules resulting in complete hyalinization of the tubules with no signs of spermatogenesis (Fig. 2).

Table 1: Testicular measurements $\bar{X} \pm SE$ (n = 15)

Measure	Control	Ligated
Length of testis (cm)	10.0 \pm 0.37	6 \pm 0.23
Girth of testis (cm)	13.6 \pm 0.43	9 \pm 0.23

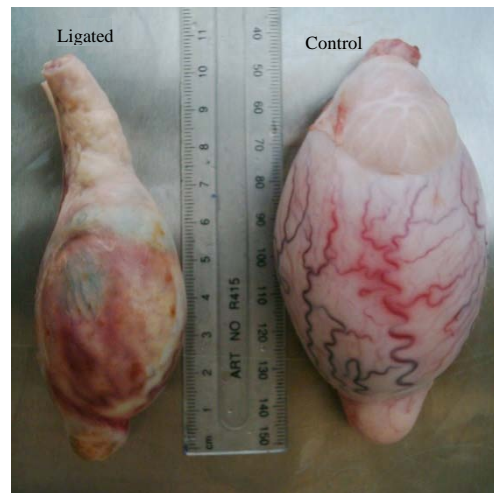

Fig. 1: Macroscopic appearance of testes 30 days after ligation, demonstrate marked atrophy compared with control

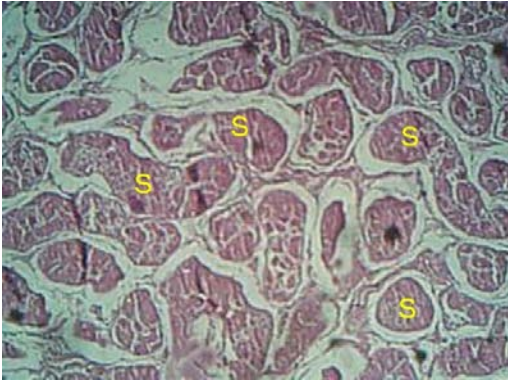


Fig. 2: Coagulative necrosis of the Seminiferous tubules (S) resulting in complete hyalinization of the tubules with no signs of spermatogenesis (X4, H&E Stain)

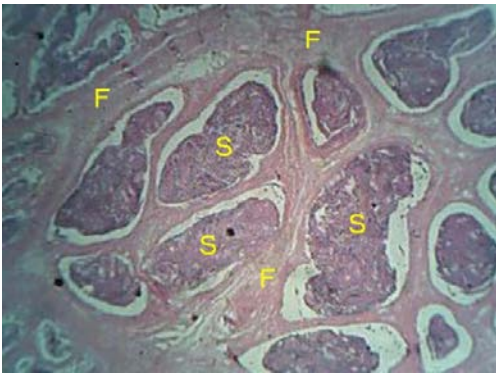


Fig. 3: The interstitial tissue replaced by thick layer of Fibrous tissue (F) with disappearance of Leydig cells. Seminiferous tubules (S) (X10, H&E Stain)

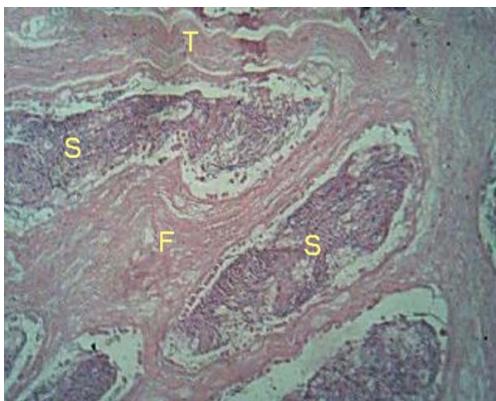


Fig. 4: Thickened of the outer layer of Testis (T), Fibrosis of the interstitial tissue (F), necrosis of the Seminiferous tubules (S) (X10, H&E Stain)

The interstitial tissue loss its normal structure with disappearance of Leydig cells. It was thickened markedly and filled with thick layer of fibrous tissue (Fig. 3). The outer layer of testis thickened and formed from thick fibrous layer (Fig. 4).

DISCUSSION

The study aims to appraisement and approval the use of a new technique of castration in buck (minimally invasive technique-pinhole castration). In ruminants in general, three techniques were most popular applicable, the Burdizzo, rubber rings (elastic band) and the surgical castration techniques (Knet *et al.*, 1996). Despite the efficiency of each one and the factors related to indicate to use. They were varies in duration of time spend for application and producing of pain (during and post operative pain). In the present study, the total time was taken (2-4 min) for the application of the pinhole ligation technique in the two testes. It was short time indicating the easiest and quickest application of the technique as the time taken by rubber ring application was <1 min, the Burdizzo castration taken 5 min while the surgical castration taken 14 min (Melches *et al.*, 2007).

Pinhole technique provides several options for its application in bucks. It can be performed while the animal in standing position, lateral recumbency, vertical holding and or by sitting on rump with the use of small quantity of local anesthetic made high malleability of the technique to perform as the preference of the applicator (surgeon or farmer) meanwhile it not need special instrument or highly experienced man to do it, make it easy to do even by farmers, like the using of Burdizzo or elastic ring. These results were in agreement with Ponvijay (2007) in calf, Okwee-Acai *et al.* (2008) in goat and Fazili *et al.* (2009) in rams, declaring the pinhole technique was simple, less painful, economic and not need special instrument.

Pinhole technique seemingly less painful (acute and chronic) where the signs of acute pain disappear half an hour after application of ligation where no chronic pain registered later during the month of observation (during touching and palpation of scrotum). This point consider a credit for this technique as the Burdizzo and surgical castration induce high level of acute pain while the rubber ring produce chronic pain can last for at least 42 days later (Molony *et al.*, 1995; Thornton and Waterman-Pearson, 1999).

The technique was elegance (Ponvijay, 2007) in which no hemorrhage, no infection and no swelling accompanied. Researchers agree with Ponvijay (2007) to use this technique at any time of year under any type of climate regardless presence or absence of flies in hot

climates. Even researchers advice those people in human being who want to castrate them self by using Burdizzo (Herzog and Santucci, 2002) to use this technique for there advantages.

Also, the technique can be used in mature buck instead of surgical castration. As most of small ruminant were castrated early at 2-3 weeks using bloodless castration techniques (Burdizzo and rubber ring) and surgical castration of ram and adult buck need general anesthesia and using of homeostasis by emasculator due to large size of the testicular cord in these species (Tibary and Van Metre, 2004).

Macroscopically the testicular mass show significant decrease in length and girth in compare with the control, this result referred to the sharp decrease if not complete stop of blood flow to the testicular tissue lead to atrophy of the testicular parenchyma. This was consistent with the earlier studies (Fisher *et al.*, 1996; Al-Kadi, 2008; Munahi and Abid, 2011).

Microscopically, severe necrosis and complete destruction of the testicular tissue were seen due to the ischemia induced by ligation of the spermatic cord make the testicular tissue nonfunctional, more fibrous tissue were seen occupying the testicular tissue. Neither spermatogenesis evidence nor viable Leydig cells were seen. This result in agreement with Stoffel *et al.* (2009).

Spermatic cord torsion cause severe damage in testicular tissue of buck and loss of spermatogenesis (Munahi and Abid, 2011) and could not return back after detorsion in rat (Turner and Brown, 1993).

CONCLUSION

Researchers seen this technique is effective and advice to use it in male goat since, it is simple, easy to perform, economic and not need more experience. It can be used in the field instead of Burdizzo and rubber ring when those tools not available.

REFERENCES

- Al-Asadi, R.N. and K.K. Al-Kadi, 2012. Non-surgical castration in Bucks a comparative study between chemical castration and external ligation of the spermatic cord. *Al-Qadisiya J. Vet. Med. Sci.*, 11: 92-102.
- Al-Kadi, K.K., 2008. Castration of the bucks via comparative study of using single and double ligation of spermatic cord. M.Sc. Thesis, Veterinary Medicine College, University of Baghdad, Baghdad, Iraq.
- Anderson, N., 2007. Castration of calves. Fact Sheet Animal Science, Ministry of Agriculture Food and Rural Affairs, Ontario, Canada, pp: 1-8.
- Baird, A.N. and D.F. Wolfe, 1998. Castration of the Normal Male. In: Large Animal Urogenital Surgery, Wolfe, D.F. and H.D. Moll (Eds.). 2nd Edn. Williams and Wilkins, Baltimore, MD., USA., pp: 295-301.
- Coetzee J.F., A.L. Nutsch, L.A. Barbur and R.M. Bradburn, 2010. A survey of castration methods and associated livestock management practices performed by bovine veterinarians in the United States. *BMC Vet. Res.*, Vol. 6. 10.1186/1746-6148-6-12.
- Cui, S., Y.F. Chen, H.N. Yue, Y.Q. He and A.S. McNeilly, 2003. Sexual development and the effect of active immunization against GnRH in Chinese Tanyang ram lambs. *Anim. Reprod. Sci.*, 77: 129-139.
- Edwards, J.F., 2008. Pathologic conditions of the stallion reproductive tract. *Anim. Reprod. Sci.*, 107: 197-207.
- Fazili, M.R., H.K. Bhattacharyya, B.A. Buchoo, M.A. Kirmani, M.M. Darzi and I. Khan, 2009. Evaluation of pinhole castration technique in rams. *Small Ruminant Res.*, 84: 61-64.
- Fisher, A.D., M.A. Crowe, M.E. Alonso de la Vega and W.J. Enright, 1996. Effect of castration method and the provision of local anesthesia on plasma cortisol, scrotal circumference, growth and feed intake of bull calves. *J. Anim. Sci.*, 74: 2336-2343.
- Gilbert, R.O. and S.L. Fubini, 2004. Surgery of the Bovine Reproductive System and Urinary Tract. In: Farm Animal Surgery, Fubini, S.L. and N. Duchorme (Eds.). Saunders, USA., pp: 351-427.
- Godfrey, S.I., S.W. Walkden-Brown, G.B. Martin and E.J. Speijers, 1996. Immunisation of goat bucks against GnRH to prevent seasonal reproductive and agonistic behaviour. *Anim. Reprod. Sci.*, 44: 41-54.
- Hendrickson, D.A., 2007. Techniques in Large Animal Surgery. 3rd Edn., Blackwell Publishing, USA., pp: 239-240.
- Herzog, M.E. and R.A. Santucci, 2002. Incisionless in-office castration using a veterinary castration device (Burdizzo clamp). *Urology*, 59: 946-946.
- Jana, K., P.K. Samanta and D. Ghosh, 2005. Evaluation of single Intratesticular injection of calcium chloride for nonsurgical sterilization of male Black Bengal goats (*Capra-hircus*): A dose dependent study. *Anim. Reprod. Sci.*, 86: 89-108.
- Kent, J.E., M.V. Thrusfield, I.S. Robertson and V. Molony, 1996. Castration of calves: A study of methods used by farmers in the United Kingdom. *Vet. Rec.*, 138: 384-387.

- Melches, S., S.C. Mellema, M.G. Doherr, B. Wechsler and A. Steiner, 2007. Castration of lambs: A welfare comparison of different castration techniques in lambs over 10 weeks of age. *Vet. J.*, 173: 554-563.
- Merkel, R.C. and L. Dawson, 2008. Castration of sheep and goats. Technical Bulletin No. 18, Ethiopia Sheep and Goat Productivity Improvement Program (ESGPIP), pp: 1-12.
- Molony, V., J.E. Kent and I.S. Robertson, 1995. Assessment of acute and chronic pain after different methods of castration of calves. *Applied Anim. Behav. Sci.*, 46: 33-48.
- Munahi, A.K. and T.A. Abid, 2011. Castration of Iraqi local bucks by bilateral spermatic cord torsion compared with double ligation of spermatic cord. *Al-Qadisiya J. Vet. Med. Sci.*, 10: 21-35.
- Okwee-Acai, J., J. Acon, D. Okello-Owiny, B. Agwai and J. Oloya, 2008. Evaluation of pinhole castration as an alternative technique for goat year sterilization. *Bull. Anim. Health Product. Africa*, 56: 299-306.
- Ponvijay, K.S., 2007. Pinhole castration: A novel minimally invasive technique for *in situ* spermatic cord ligation. *Vet. Surg.*, 36: 74-79.
- Price, J., R.A. Eager, E.M. Welsh and N.K. Waran, 2005. Current practice relating to equine castration in the UK. *Res. Vet. Sci.*, 78: 277-280.
- Searle, D., A.J. Dart, C.M. Dart and D.R. Hodgson, 1999. Equine castration: Review of anatomy, approaches, techniques and complications in normal, cryptorchid and monorchid horses. *Aust. Vet. J.*, 77: 428-434.
- Stoffel, M.H., A. von Rotz, M. Kocher, M. Merki, D. Boesch and A. Steiner, 2009. Histological assessment of testicular residues in lambs and calves after Burdizzo castration. *Vet. Rec.*, 164: 523-528.
- Thompson, D.L., 2000. Immunization against GnRH in male species (comparative aspects). *Anim. Reprod. Sci.*, 60: 459-469.
- Thornton, P.D. and A.E. Waterman-Pearson, 1999. Quantification of the pain and distress responses to castration in young lambs. *Res. Vet. Sci.*, 66: 107-118.
- Tibary, A. and D. Van Metre, 2004. Surgery of the Sheep and Goat Reproductive System and Urinary Tract. In: *Farm Animal Surgery*, Fubini, S. and N. Duchorme (Eds.). Saunders, USA., pp: 527-547.
- Turner, T.T. and K.J. Brown, 1993. Spermatic cord torsion: Loss of spermatogenesis despite return blood flow. *Biol. Reprod.*, 49: 401-407.
- Ulker, H., M. Kucuk, A. Yilmaz, M. Yoruk, L. Arslan, D.M. deAvila and J.J. Reeves, 2009. Changes in testicular development, ultrasonographic and histological appearance of the testis in buck kids immunized against LHRH using recombinant LHRH fusion protein. *Reprod. Dom. Anim.*, 44: 37-43.
- Van Lancker, S., W. Van Den Broeck and P. Simoens, 2005. Morphology of caprine skin glands involved in buck odour production. *Vet. J.*, 170: 351-358.