

## Zoonotic Potential of Health Wild Felids for Dermatophytes

<sup>1</sup>Mayra A.P. Figueiredo, <sup>1</sup>Wilson G. Manrique, <sup>1</sup>Marco A.A. Belo and <sup>2</sup>Hailton R.C. Reis

<sup>1</sup>Department of Veterinary Pathology, Sao Paulo State University, Jaboticabal/SP, Brazil

<sup>2</sup>Department of Veterinary Pathology, Maranhao State University, Sao Luis/MA, Brazil

---

**Abstract:** Dermatophytes are fungi that cause superficial mycoses in animals and humans. Infection can occur through direct contact with spores or hyphae of contaminated material. Studies in asymptomatic domestic cats have demonstrated the presence of dermatophytes which make them significant source of infection for other animals and humans that aspect is not well studied in wild felines. This study aimed to determine the presence of dermatophytes on the haircoat of health wild felids kept in captivity in Screening Center for Wild Animals in Sao Luis City, Maranhao State, Brazil. Hair samples of 13 adults wild felines were collected, seven *Leopardus trigrinus* (5 males and 2 females), one *Leopardus wiedii* (female) and five *Leopardus pardalis* (2 males and 3 females) and seeded by printing on Sabouraud dextrose agar plates supplemented with chloramphenicol 0.5 g L<sup>-1</sup> cycloheximide and 0.4 g L<sup>-1</sup> at 25°C with daily observation for 15 days. For the analysis of reproductive forms were stained with Giemsa for 35 min. In cultures was isolated: *Microsporum canis*, *Trichophyton mentagrophytes* and *Epidermophyton floccosum*. The occurrence of dermatophytes on the haircoat of healthy wild felids kept in captivity, confirms its status as asymptomatic carriers and characterizes them as sources of infection for other animals including humans.

**Key words:** *Epidermophyton* sp., feline, fungi, *Microsporum* sp., *Trichophyton* sp.

---

### INTRODUCTION

Dermatophytes are a group of fungi originally saprophytes, mycelial and keratolytics, classified into three genus: *Microsporum*, *Trichophyton* and *Epidermophyton* which can invade keratinized structures causing superficial fungal infection known as ringworm in mammals including humans. According to their habitat are classified as anthropophilic, zoophilic and geophilic although it is true that each species has a predominant but not exclusive habitat (Caretta *et al.*, 1989). Zoophilic dermatophytes regularly attack animals and their contact with humans can also result in infection. It is well known transmission of certain dermatophytes from domestic animals such as dogs and cats (Caretta *et al.*, 1989; Zaror *et al.*, 1986).

Previous studies have demonstrated that animals without clinical signs can serve as sources of infection (Caretta *et al.*, 1989). Infection occurs through direct contact with spores or hyphae contained in the skin, dandruff or contaminated fomites. Dermatophytes are associated with predisposing factors such as compromising the integrity of the skin and mucosa physicochemical factors like ultraviolet radiation

and temperature presence of disease during immunosuppressive treatment (Aljabre *et al.*, 1992; Ogawa *et al.*, 1998). The animal age can also be directly related to the infection, young animals are more susceptible than adults who may present as asymptomatic and act as a source of infection for young animals and even to humans.

In domestic cats (*Felis catus*) the *Microsporum canis* was the most isolated species with or without symptoms (Zaror *et al.*, 1986) followed by *Microsporum gypseum* and *Trichophyton mentagrophytes*. Some studies show that domestic cats are most often asymptomatic carriers of dermatophytes and therefore an important source of infection. This aspect is not well studied in relation to wild felids (Brotto *et al.*, 2005; Bentubo *et al.*, 2006) which compromises prevalence data in these animals and their zoonotic potential.

### MATERIALS AND METHODS

Animals were analyzed hair samples from 13 adult wild cats, clinically healthy with no signs of alopecia or skin lesions, seven *Leopardus tigrinus* (5 males and 2 females), one *Leopardus wiedii* (female) and five

*Leopardus pardalis* (2 males and 3 females) kept in captivity in the Triage Center of Wild Animals-IBAMA, in the municipality of Sao Luis, Maranhao State, Brazil.

The animals were sedated with the association of ketamine hydrochloride (10 mg kg<sup>-1</sup>) and xylazine (1 mg kg<sup>-1</sup>) administered by intramuscular route to collect biological samples for various tests including Feline Immunodeficiency Virus (FIV) and Feline Leukemia Virus (FELV).

**Samples and fungi isolation:** The hair samples were collected by scraping with a scalpel blade and stored in sterile Falcon tubes type to be rapidly processed at the Microbiology Laboratory from Veterinary Medicine College, State University of Maranhao. Then were inoculated in Petri dishes containing Mycobiotic agar (Difco®) and incubated at 25°C for 4 weeks. The colonies obtained were pricked out into tubes containing Sabouraud dextrose (Himedia®) with chloramphenicol (100 mg L<sup>-1</sup>) and cycloheximide (400 mg L<sup>-1</sup>) maintained at 25°C and subjected to microculture plate for later identification through macro and microscopic characteristics (Larone, 1995; Quinn *et al.*, 1994). For analysis of reproductive forms, a transparent film was passed on the plate surface, adhered to a slide and stained for 35 min with Giemsa (Sigma-Aldrich, St. Louis, EUA). No direct examination was performed.

**RESULTS AND DISCUSSION**

In the feline hair, it was identified *Microsporium canis* (Fig. 1) *Trichophyton mentagrophytes* (Fig. 2) and *Epidermophyton floccosum* (Fig. 3) which was later confirmed by culture and the prevalence were 84.6, 53.8 and 76.9%, respectively in all feline species studied.

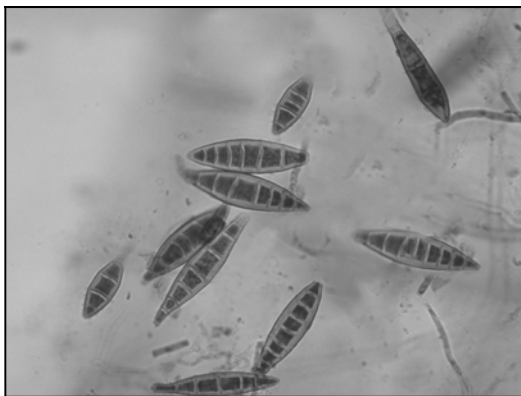


Fig. 1: Photomicrograph of macroconidia of *Microsporium canis* (Giemsa stained)

Table 1 shows the prevalence of dermatophytes observed by felids species. The prevalence stratified by sex into feline species can be seen in Table 2. All animals were seronegative for FIV and FELV.

In domestic animals, *M. canis*, *M. gypseum* and *T. mentagrophytes* are the main species related to dermatophytes. However, *M. canis* assumes considerable relevance being the main fungus isolated in cats (Zaror *et al.*, 1986; Gambale *et al.*, 1993; Pier and Moriello, 1998) corroborating the findings of this

Table 1: Prevalence of dermatophytes identified in each feline species studied

Dermatophytes	Feline species <sup>1</sup>		
	<i>Leopardus tigrinus</i>	<i>Leopardus wiedii</i>	<i>Leopardus pardalis</i>
<i>Microsporium canis</i>	85.7	100	80
<i>Trichophyton mentagrophytes</i>	42.8	100	80
<i>Epidermophyton floccosum</i>	85.7	0	80

<sup>1</sup>Prevalence of dermatophyte for each feline species

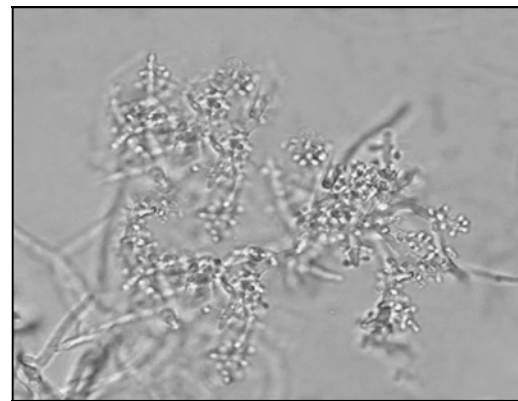


Fig. 2: Photomicrograph of *Trichophyton mentagrophytes*. Hyphae with pooled microconidia, arranged in the shape of bunches of grapes (Giemsa stained)

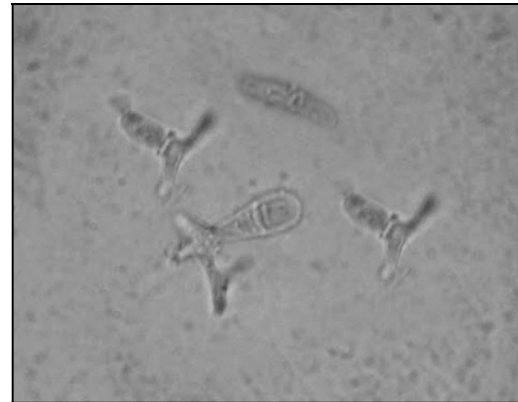


Fig. 3: Photomicrograph of *Epidermophyton floccosum* hyphae with microconidia (Giemsa stained)

Table 2: Prevalence of dermatophytes identified in each sex feline species studied

Dermatophytes	Feline species <sup>1</sup>					
	<i>Leopardus tigrinus</i>		<i>Leopardus wiedii</i>		<i>Leopardus pardalis</i>	
	Male	Female	Male	Female	Male	Female
<i>Microsporum canis</i>	80	100	-	100	66.6	100
<i>Trichophyton mentagrophytes</i>	40	50	-	100	100.0	50
<i>Epidermophyton floccosum</i>	80	100	-	0	100.0	50

<sup>1</sup>Prevalence of dermatophyte for each feline species by sex

investigation. The domestic cat status as a healthy carrier is extremely important and represent a risk of infection to other animals even to humans as well as they can be considered a public health problem (Zaror *et al.*, 1986; Costa *et al.*, 1994).

Although, the epidemiology of dermatophytosis in wild cats is not well documented, dermatophytes were isolated and described by several researchers in different wild species. In Brazil, Albano *et al.* (2013) found that 60 wild cats in captivity, 6.6% were positive for dermatophytes of the genus *Trichophyton*. Salebian and Lacaz (1980) isolated dermatophytes from the same genus in hairs from wild free-living Brazilian rodents. Another dermatophyte, *T. mentagrophytes* was isolated in Western Australia present in the hairs of various domestic and wild animals, among them one kangaroo who transmitted the dermatophytes to humans causing injuries in the skin (McAleer, 1980). In the same year, William *et al.* (1980) reported a case of infection by *T. mentagrophytes* in one wild-free living red fox (*Vulpes fulva*) in the United States of America.

The fungus *M. gypseum* has been described as the largest potential to infect animals and humans and comes to be regarded by some as the main causative agent of dermatophytosis in rabbits (Khosravi and Mahmoudi, 2003), cats (Kano *et al.*, 2001) interspecies outbreaks involving cats and humans (Costa *et al.*, 1994) and also described in the clinical features of infection associated with *Dermatophilus congolensis* in Arabian camels (*Camelus dromedarius*) (Gitao *et al.*, 1998) and *Malassezia pachydermatis* in dogs (Saridomichelakis *et al.*, 1999). In Brazil were reported two cases of dermatophytosis by this species, involving one gray wolf (*Canis lupus*) and one Bactrian camel (*Camelus bactrianus*) (Fischman *et al.*, 1987).

The diagnosis results of animals dermatophytosis obtained by Schmidt (1996) showed high prevalence of *T. mentagrophytes* in small rodents. This fungus was also isolated from wild boar hairs (*Sus scrofa*) in Italy despite not presenting symptoms of infection (Mancianti *et al.*, 1997).

Dermatophytes were also isolated from hairs of wild cats such as tiger (*Panthera tigris*) (Costa *et al.*, 1995), ocelot (*Leopardus pardalis*) and lion (*Panthera leo*) (Costa *et al.*, 1995). Already, Balda observed that in

domestic cats diagnosed with ringworm, over 65% of the animals were young and free (with street access) suggesting that the presence of fungi in the wild cats in the present study is not related to stress of captivity. Since the zoonotic potential of dermatophytes, it is important to investigate in animals captured and learned, even when they do not show symptoms to determine possible sources of infection.

The occurrence of dermatophytes in the hair of healthy wild felines kept in captivity not only increases the risk of these animals may eventually become sick but also leaves them under the category of asymptomatic carriers, characterizing them as sources of fungal infection for other animals and humans.

## CONCLUSION

Based on this information, the present study aimed to investigate the presence of dermatophyte fungi in the hair of 13 wild cats from Triage Center of Wildlife Animals-IBAMA in the municipality of Sao Luis, Maranhao State, Brazil.

## ACKNOWLEDGEMENT

Researchers thank the director from the Triage Center of Wildlife Animals-IBAMA in the city of Sao Luis, Maranhao State, Brazil for authorizing this study with felines kept in captivity.

## REFERENCES

- Albano, A.P.N., P.S. Nascente, A.T.M. Leite, M.O. Xavier and R. Santin *et al.*, 2013. Isolation of dermatophytes in wild felids from screening centers. Braz. J. Microbiol., 44: 171-174.
- Aljabre, S.H.M., M.D. Richardson, E.M. Scott and G.S. Shankland, 1992. Germination of *Trichophyton mentagrophytes* on human stratum corneum *in vitro*. J. Med. Vet. Mycol., 30: 145-152.
- Bentubo, H.D.L., J.D.L. Fedullo, S.H.R. Correa, R.H.F. Teixeira and S.D.A. Coutinho, 2006. Isolation of *Microsporum gypseum* from the haircoat of health wild felids kept in captivity in Brazil. Braz. J. Microbiol., 37: 148-152.

- Brotto, T.L., M.C.R. Andrade, M.A.B. Goncalves, F. Gimenez and A. Pina, 2005. Identification of fungi microflora in the ear conducts of rhesus macaques (*Macaca mulatta*) kept in captivity. *Braz. J. Vet. Res. Anim. Sci.*, 42: 459-464.
- Caretta, G., F. Mancianti and L. Ajello, 1989. Dermatophytes and keratinophilic fungi in cats and dogs. *Mycoses*, 32: 620-626.
- Costa, E.O., L.S.M. Diniz, N.R. Benites, S.D. Coutinho, V.M. Carvalho, L.F. Dutra and E.G. Serra, 1994. [Human and animal dermatomycosis: Outbreaks of *Microsporum canis* and *Microsporum gypseum*]. *Revista Saude Publica*, 28: 337-340 (In Portuguese).
- Costa, E.O., L.S.M. Diniz, V.M. Carvalho, S.D. Coutinho and N.R. Benites, 1995. [Dermatoses observed in man, laboratory, domestic and wild animals in Sao Paulo, Brazil. Restrospective study]. *Arquivo Brasileiro Medicina Veterinaria Zootecnia*, 47: 601-607 (In Portuguese).
- Fischman, O., P.A. Siqueira and G. Baptista, 1987. *Microsporum gypseum* infection in a gray wolf (*Canis lupus*) and a camel (*Camelus bactrianus*) in a zoological garden. *Mycoses*, 30: 295-297.
- Gambale, W., C.E. Larsson, M.M. Moritami, B. Correa, C.R. Paula and V.M.S. Framil, 1993. Dermatophytes and other fungi of the haircoat of cats without dermatophytosis in the city of Sao Paulo, Brasil. *Feline Practice*, 21: 29-33.
- Gitao, C.G., H. Agab and A. Khalifalla, 1998. An outbreak of a mixed infection of *Dermatophilus congolensis* and *Microsporum gypseum* in camels (*Camelus dromedarius*) in Saudi Arabia. *Rev. Sci. Tech. Off. Int. Epiz.*, 17: 749-755.
- Kano, R., K. Yasuda, Y. Nakamura and A. Hasegawa, 2001. *Microsporum gypseum* isolated from a feline case of dermatophytosis. *Mycoses*, 44: 338-341.
- Khosravi, A.R. and M. Mahmoudi, 2003. Dermatophytes isolated from domestic animals in Iran. *Mycoses*, 46: 222-225.
- Larone, D.H., 1995. *Medically Important Fungi: A Guide to Identification*. 3rd Edn., ASM Press, Washington, DC., USA., ISBN-13: 9781555810917, Pages: 274.
- Mancianti, F., E. Mignone and R. Papini, 1997. Keratinophilic fungi from coats of wild boars in Italy. *J. Wildlife Dis.*, 33: 340-342.
- McAleer, R., 1980. Zoophilic dermatophytes and their natural hosts in Western Australia. *Med. J. Aust.*, 1: 506-508.
- Ogawa, H., R.C. Summerbell, K.V. Clemons, T. Koga and Y.P. Ran *et al.*, 1998. Dermatophytes and host defence in cutaneous mycoses. *Med. Mycol.*, 36: 166-173.
- Pier, A.C. and K.A. Moriello, 1998. Parasitic relationship between *Microsporum canis* and the cat. *Med. Mycol.*, 36: 271-275.
- Quinn, P.J., M.E. Carter, B.M. Maarkey and G.R. Carter, 1994. *Clinical Veterinary Microbiology*. Mosby, London, UK., Pages: 648.
- Salebian, A. and C.S. Lacaz, 1980. [Isolation of dermatophytes from hair of wild animals]. *Anais Brasileiros Dermatologia*, 55: 125-130 (In Portuguese).
- Saridomichelakis, M.N., A.F. Koutinas, E. Bourdiz-Hatzopoulou, E. Petridou, I. Hatziefremidis and L. Leontides, 1999. Recovery of *Microsporum gypseum* and *Malassezia pachydermatis* from the nasal bridge in various dog groups. *Vet. Rec.*, 145: 171-172.
- Schmidt, A., 1996. Diagnostic results in animal dermatophytoses. *J. Vet. Med. Ser. B*, 43: 539-543.
- William, U.K., C.E. Gates and G.H. Ruth, 1980. *Trichophyton mentagrophytes* dermatophytosis in wild fox. *J. Wildlife Dis.*, 16: 465-468.
- Zaror, L., O. Fischman, M. Borges, A. Vilanova and J. Levites, 1986. The role of cats and dogs in the epidemiological cycle of *Microsporum canis*. *Mycoses*, 29: 185-188.