

The Potential Effect of Camel Milk and Urine Against CCL4-Induced Lesions in Male Rats

¹Salah Abdulaziz Al-Shami, ³Nagwan El-Habashi, ¹Mohamed A. Mandour,

²Yehia Ahmed Hussein and ²Marzook Mohamed Al-EknaH

¹Department of Veterinary Public Health and Animal Husbandry,

²Department of Clinical Studies, College of Veterinary Medical and Animal Resources,
King Faisal University, Saudi Arabia

³Department of Veterinary Pathology, Faculty of Veterinary Medicine,
Kafr El-Sheikh University, Kafr El-Sheikh, Egypt

Abstract: This study was designed to explore the potential of camel milk and urine and their protective effects against Carbon Tetrachloride (CCL4) intoxication in male rats. Six experimental groups of two dietary regimes (milk, urine and their mixture) before and after CCL4 injection were evaluated in comparison with positive (CCL4 only) and negative control groups. Camel urine and milk were diluted by water (1:3 and 1:1 v/v). The diluted urine and milk were mixed in equal volumes directly before fed to rats. The results revealed the occurrence of the highest histopathological changes in testis, liver and kidney of the CCL4 treated group. Feeding urine or milk prior CCL4 intoxication showed almost complete to moderate retrieval of the induced lesions. Milk urine mixture showed retrieval of the induced lesions in testis, however; gave lesions similar degree to those seen in liver and kidneys. CCL4 injection then feeding trial revealed that urine and milk reduced the induced lesions by the same degree in testis and liver. This study point to the possible protective potential of camel milk and urine (in prophylaxis or treatment) against the CCL4-induced damage.

Key words: Camel milk and urine, ameliorating effect, carbon tetrachloride, liver, kidney, testis

INTRODUCTION

Research in the last decade has focused on the use of camel milk and urine for their potential antioxidant, hepatoprotective effect and treatment or prophylaxis of disorders attributed to free radical oxidative damages in different organs of experimental animal (Young and Woodside, 2001).

Not only the camel has provided transportation and food but also its milk and urine have been used traditionally for the maintenance of good health and the treatment of diverse diseases (Yagil and van Creveld, 2000). In India, camel milk is used therapeutically against dropsy, jaundice, problems of tuberculosis, asthma, anemia and piles. A clinic has been established in which milk is used for treatment patients with chronic hepatitis had improved liver function after being treated with camel milk (Rao *et al.*, 1970; Mal *et al.*, 2001). The unique composition of camel milk has been proved to fortify the immunity system. Its components have proved to be effective in killing microbial agents both viral and bacterial

and in protecting the human body against various diseases as well as treating some types of cancer (Al-Attas, 2009).

Arabian camel urine was also, a standard prescription in Arab medicine and remains stable for Bedouin natural remedies to this day, both as diuretic stuff and delousing hair detergent (Mona, 2003). Therapeutic uses of animal's urine have a long history as that of human. Most of the earlier and current studies deal with pharmacological and therapeutic effects of urine. The percentage of use of camel urine among five nomadic tribes in eastern Sudan were as follows: 72% use camel urine for internal problems in general while 52, 32, 20 and 32% used it for malaria, ascites, dental problems and hair shampoo, respectively. The 72% drank it as pure urine whereas 28% mixed it with milk (Ohaj, 1998).

Carbon Tetrachloride (CCL4) is a well-established lipid-soluble hepatotoxic agent (Weber *et al.*, 2003). It can cause damage in many tissues other than the liver including the kidney, heart, lung, testis and brain (Abraham *et al.*, 1999; Ozturk *et al.*, 2003). In previous studies of CCL4 toxicity, severe airway obstruction,

abnormal lung inflammation, increased mast cell degranulation and bronchial edema in mice preceded the onset of severe hepatic injury (Kalinichenko *et al.*, 2003). The free radicals, produced from CCL4 metabolism, induced lipid peroxidation and caused cell membrane damage leading to a number of pathological changes in liver and kidney (Kim *et al.*, 2007).

Reports documented that several natural products, herbal extracts and plant-derived pure molecules could protect organs against CCL4 by enhancing the antioxidant activity (Rajesh and Latha, 2004). Endogenous antioxidants in medicinal herbs may play an important role as a defense against oxidative damage and protecting the biological functions of cells (Adewole *et al.*, 2007). Therefore, this research was carried out to assess the impact of camel milk and urine as a traditional folk medicine and to evaluate their protective effects against carbon tetrachloride induced toxicity in male rats.

MATERIALS AND METHODS

Camel milk and urine: Milk and urine used in this study were collected from female indigenous Majaheem camel breed (*Camelus dromedarius*) kept at the farm of camel and Range Research Center of Ministry of Agriculture (FAO project at Al-Jouf-Sakaka, Saudi Arabia). Camels were randomly selected from the physically and clinically healthy ones. Ten pregnant heifer camels (4-6 years old) were selected for urine samples and 10 lactating camels at the first parity were chosen for milk samples, after screening for detection of subclinical mastitis. They were housed together in aluminum shaded and fenced pen supplied with clean water trough and feed bunks. They were fed 4% of body weight with standard commercial camel ration (National Feed Company FEEDCO, Riyadh) with free access to alfalfa and clean fresh water. Camels under investigation were kept under close observation for two weeks before milk and urine being collected in sterile screw bottles under aseptic conditions from each camel, kept in cool insulated boxes and freezed at -80°C till shipping and feeding to laboratory rats. Camel urine and milk were diluted by water (1:3 and 1:1 v/v). The diluted urine and milk were mixed in equal volumes directly before fed to laboratory rats (Khalifa *et al.*, 2009). Water clear or mixed with fresh milk/and or urine were given *ad libitum*, being changed daily.

Laboratory animals: A total of forty five adult male albino rats aged 2.5-3 months with an average body weight of 150-200 g were selected randomly from the Laboratory Animal House located at College of Veterinary Medicine

and Animal Resources, King Faisal University, Kingdom of Saudi Arabia. They were housed in standard well ventilated fiber-glass cages (5 rats/cage) in an environmentally controlled room with constant temperature ($24\pm 2^{\circ}\text{C}$) and 60-65% relative humidity in hygienic condition under natural light and dark schedule. The rats were fed on standard laboratory diet. Food and water free or mixed with fresh camel milk/and or urine were given *ad libitum*, being changed daily. All rats were kept under a period of acclimatization for 15 days under standard hygienic conditions, before starting the experiment for a month. The guide for the care and use of laboratory animals was followed in accordance to The National Institute of Health (NIH).

Experimental design: The rats were randomly assigned into nine groups of 5 rats each as following:

- Group 1 (Gp1); received neither milk and/or urine nor CCL4 for 30 days but received only a single intraperitoneal (I/P) dose (1.0 mL) of olive oil then received only commercial pellet of rat diet, water and served as normal or negative control
- Group 2 (Gp2); was given a single intraperitoneal dose (3 mL kg^{-1}) of CCL4 in 1.0 mL of olive oil (Ganu *et al.*, 2013) then received only commercial pellet of rat diet and water and served as a positive control for CCL4 (Gp2a for prophylactic trial and Gp2b for treatment trial)

Prophylactic groups:

- Group 3 (Gp3); was supplemented with camel milk for a month first then followed by a single intraperitoneal injection (I/P) of CCL4 (3 mL kg^{-1})
- Groups 4 (Gp4); was supplemented with camel urine for a month first then followed by a single intraperitoneal dose of CCL4 (3 mL kg^{-1})
- Group 5 (Gp5); was supplemented with camel milk and urine mixture for a month first then followed by a single intraperitoneal dose of CCL4 (3 mL kg^{-1})

Treatment groups:

- Group 6 (Gp6); received a single dose of CCL4 (3 mL kg^{-1}) first, then followed by feeding camel milk for a month
- Group 7 (Gp7); received a single dose of CCL4 (3 mL kg^{-1}) first then followed by feeding camel urine for a month
- Group 8 (Gp8); received a single dose of CCL4 (3 mL kg^{-1}) first then followed by feeding camel milk and urine mixture for a month

Histopathological studies: Rats of all groups under investigation were clinically observed until the end of the experiment (4 weeks) then three rats from each group were euthanized and necropsied out. Small pieces of testis, liver and kidney were fixed in bouin's solution, dehydrated in ascending grades of alcohol and embedded in paraffin blocks. The 3-5 μm thick paraffin sections were cut, stained with haematoxyline and eosin (Bancroft, 2008) then examined microscopically. The microscopic changes in the organs of the studied groups were recorded and comparatively evaluated (Misawa *et al.*, 2000; Yildiz *et al.*, 2011).

RESULTS

Regards for the clinical observations in the present research, the rats in most of all groups did not exhibit any obvious clinical signs or mortalities and they were apparently healthy all over the whole experimental period.

Histopathological changes: No differences were detected between Gp2a for prophylactic trial and Gp2b for treatment trial so, they will be discussed as one group Gp2.

Effect of feeding camel milk, urine or their mixture then CCI4 injection (prophylactic groups): Testes (Fig. 1a-d): the testes in Gp2 and 3 were mostly affected by testicular degeneration in the form of cellular vacuolation with absence of spermatogonial cells, primary and secondary spermatocytes and presence of large number of spermatide giant cells in some of the seminiferous tubules. Interstitial edema and congestion were also noticed. On the contrary, Gp4 and 5 showed almost complete retrieval of the induced testicular changes to a very mild degree of interstitial edema and congestion.

Liver (Fig. 2a-d): the most prominent histological changes were in the form of hepatocytic hydropic degeneration which ranged from very mild degree in Gp4

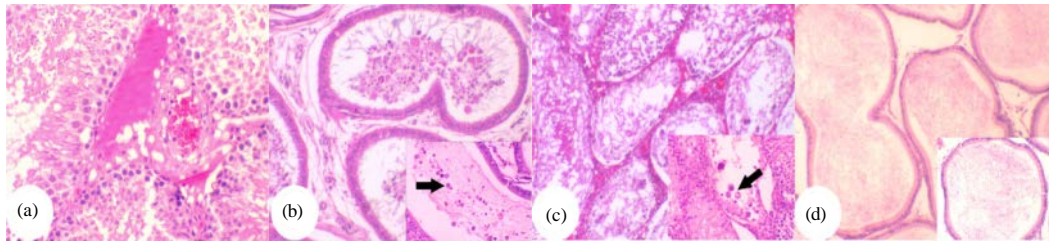


Fig. 1a-d): Histopathological features of testis stained with H&E; Gp2, the testis showing interstitial edema and congestion (x400); Gp3, the epididymal ducts showing decrease in the number of mature sperms in their lumen and presence of immature cells from seminiferous tubules (arrowhead) x200; Higher inset, x400; Gp3, the testis showing testicular degeneration, vacuolation of seminiferous tubules with absence of spermatogonial cells, primary and secondary spermatocytes, spermatids and spermatozoa together with a large number of multinucleated giant cells (arrowhead) x200; higher inset, x400; Gp4, the epididymal ducts showing normal number of mature sperms in their lumen (x200)

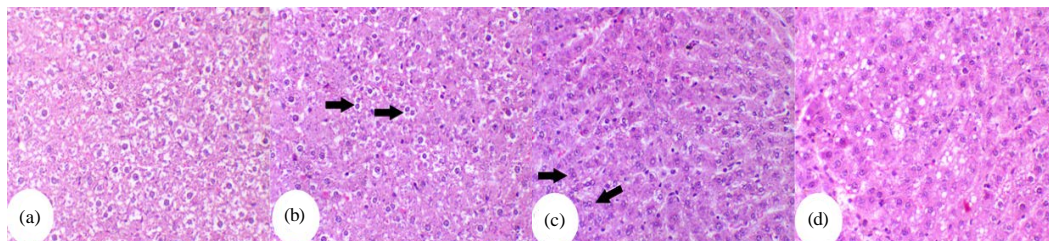


Fig. 2a-d): Histopathological features of liver stained with H&E, x200; Gp2, the liver showing marked hydropic degeneration of the hepatocytes; Gp3, the liver showing moderate hydropic degeneration and frequent double or hyperchromatic nuclei (arrowhead); Gp4, the liver showing very mild hydropic degeneration of the hepatocytes and frequent double nuclei (arrowhead); Gp5, the liver showing mild fatty change of the hepatocytes

to severe degree in G2 and Gp5. Very mild sinusoidal cell activation and sinusoidal dilation which tended to be moderately recorded in Gp2, 3 and 5. Hypertrophy of some hepatocytes with large hyperchromatic or double nuclei as sign of regeneration was detected in groups 4 and 5.

Kidney (Fig. 3a-c): rats in Gp2, 4 and 5 showed similar mild degrees of renal lesions in form of epithelial vacuolation and hydropic degeneration of the renal

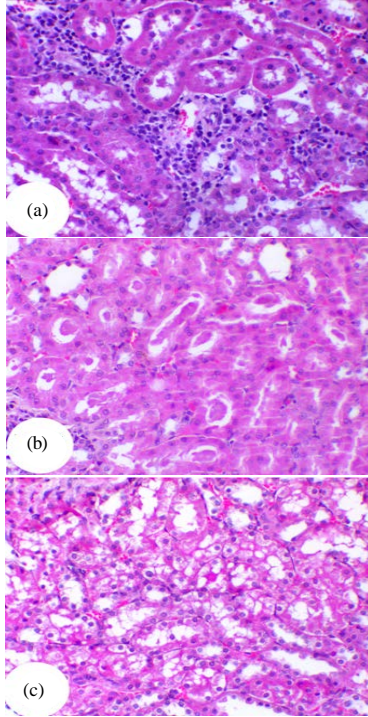


Fig. 3a-c): Histopathological features of kidney stained with H&E, x200; Gp2, the kidney showing intertubular mononuclear cells infiltrations; Gp5, the kidney showing renal casts; Gp5, the kidney showing vacuolation of renal tubular cells

tubules, glomerular and intertubular congested blood capillaries. Mononuclear cells infiltrations and renal tubular casts were also seen in Gp2 and 5.

Effect of injecting CCl4 then feeding camel milk, urine or their mixture (treatment groups): Testes (Fig. 4a-b): the testes in Gp6 and 7 were nearly normal except for some very mild interstitial edema and congestion while mild testicular degeneration were seen in Gp8.

Liver (Fig. 5a-d): the most prominent changes were in the form of mild degree of sinusoidal cell activation in groups in addition to focal sinusoidal dilation in Gp2, 6 and 8. Bile duct proliferation was detected in Gp8 in mild degree. Some degrees of hepatocytic hydropic all degeneration were observed in Gp2 and Gp8. Hypertrophy of hepatocytes with large hyperchromatic or double nuclei was detected in some cases. Increase in apoptotic figures was observed in Gp7.

Kidney (Fig. 6a-b): decreased glomerular and intertubular congestion was observed in Gp7. Other groups showed similar changes. They were in the form of vacuolation of the renal tubular epithelium, glomerular and intertubular congestion as well as mononuclear cells infiltrations especially in the renal cortex. Renal tubular casts were also observed in Gp2 and 8.

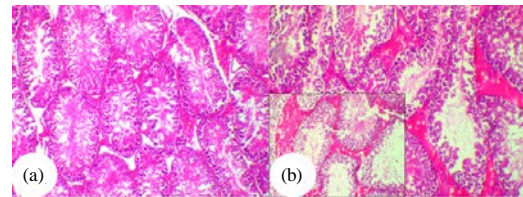


Fig. 4a-b): Histopathological features of testis stained with H&E, x100; Gp6, the testis showing normal seminiferous tubules; Gp8, the testis showing mild testicular degeneration and interstitial edema

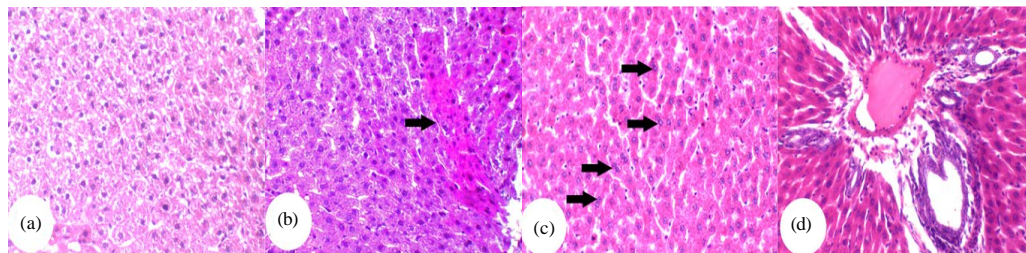


Fig. 5a-d): Histopathological features of liver stained with H&E, x200; Gp2, the liver showing hydropic degeneration of the hepatocytes with nuclear pyknosis; Gp7 group, the liver showing increase apoptotic figures in the hepatocytes (arrowhead); Gp8, the liver showing sinusoidal cell dilation and frequent double nuclei (arrowhead); Gp8, the liver showing biliary hyperplasia, edema and perivascular inflammatory cells infiltrations

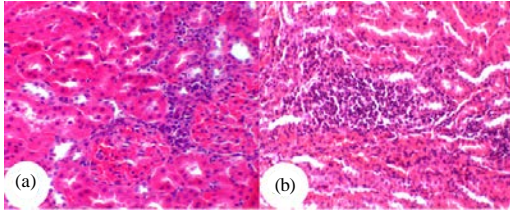


Fig. 6a-b): Histopathological features of kidney stained with H&E, x200; Gp2, the kidney showing glomerular congestion with marked decrease in the glomerular space together with mononuclear intertubular cells infiltration; Gp8, the kidney showing intertubular mononuclear cells infiltrations (x100)

Carbon Tetrachloride (CCL4) a highly toxic chemical agent with a strong nephrotoxicity is widely used to provoke experimental liver damage, intoxication in animals and oxidative stress (Weber *et al.*, 2003; Eman *et al.*, 2010). It causes kidney, lungs, heart and testicular damages in rats (Abraham *et al.*, 1999; Ozturk *et al.*, 2003). In the present study, CCL4 treated group showed lesions in different organs including testis, liver and kidney similar to those stated in the above mentioned reports.

Camel milk is different from other ruminant milk. It is low in cholesterol, sugar and protein but high in minerals (sodium, potassium, iron, copper, zinc and magnesium), vitamins (A, B2, C and E) and contains a high concentration of insulin (Knoess, 1979). The protective effect of camel milk against CCL4-induced renal, hepatic and testicular injury in male rats used in this experiment can be explained based on its nutritional composition and its antioxidant properties (Yousef, 2004).

The histopathological changes in testes of rats administered CCL4 are in agreement with Khan and Ahmed (2009) who showed that CCL4 administration caused testicular atrophy, degeneration of germinal cell layer in male rats. Feeding urine or milk after CCL4 intoxication to male rats showed almost complete retrieval of the lesions induced by CCL4, however, feeding milk and urine mixture induced changes similar to those observed in CCL4 received group in injection then feeding study. These findings agreed with Khalifa (2006) who indicated that camel milk and urine retrieved experimentally the toxic pathological effect of Haloperidol (Antipsychotic agents) in testis of Albino rats and reduced its side effect. Moreover, the ameliorating effect of natural products against induced rat testis intoxication was also supported by the report of Hasseeb *et al.* (2013) about the chemoprevention of acrylamide toxicity by using of antioxidants.

The liver is responsible for metabolism and detoxification of the most of components that enter the body. In the present study, milk or urine received rat groups showed almost complete retrieval of the liver lesions induced by CCL4 though, combination group (received milk and urine) showed lesions less than CCL4 received group in injection then feeding trial. The protective effect of camel milk, orally administered against induced liver toxicity in white Albino rats was also indicated by Al-Hashem *et al.* (2009) for cadmium and Althnaian *et al.* (2013) for CCL4.

Moreover, feeding urine or milk reduced the induced lesions ranged from mild to moderate degree, nevertheless, combination group showed lesions similar to those observed in CCL4 treated group in feeding then CCL4 injection experiment. These results agree with those of Khalifa *et al.* (2009, 2010) who reported that mixture of camel milk and urine (equal parts) masked and reduced the toxic effect of CCL4 in liver of rats.

Reports from Abraham *et al.* (1999) and Ogeturk *et al.* (2005) indicated that kidney tissue has great affinity for CCL4 because of the predominant presence of the cytochrome P450 in the cortex. Kidney histopathological alterations observed in the CCL4-treated group in the present investigation were similar to the findings of the previously mentioned researchers who stated that kidneys of CCL4 treated rats have shown characteristic morphological findings such as glomerular and tubular degeneration and interstitial mononuclear cell infiltration. Glomerular hypercellularity and tubule-interstitial alterations were also detected by Ozturk *et al.* (2003) and Ogeturk *et al.* (2005) in renal tissues of rats treated with CCL4. In the present study, although urine fed group showed a prominent reduction in glomerular and intertubular congestion, milk, combination and CCL4 received groups had comparable changes in injection then feeding trial. In addition, feeding urine to rats reduced the previous lesions to a very mild degree. This result agreed with Al-Hashem (2009) who found that treatment with camel milk feeding before intoxication of Aluminum Chloride (AlCl₃) exposure alleviated its associated hazards and protected the kidney and liver from AlCl₃ toxicity. On the other hand, combination group showed lesions similar to those observed CCL4 treated group in feeding then CCL4 injection experiment. The non-protective effect of camel milk and urine mixture against the CCL4 induced kidney lesions disagree with the results of El-Hummdi (2006) who recorded a noticed reduction in the histopathological changes of mammalian kidney induced by Anticoagulant drug (Enoxaparin Sodium).

CONCLUSION

It could be concluded that the protective potential of milk and urine against the CCL4-induced liver, kidney and testicular damage was detected. There may be discrepancies in the retrieval of CCL4-induced lesions between milk and urine as following:

- Urine gave better retrieval of the lesions induced by CCL4 than milk by one degree in both studies
- Adding milk in prophylactic study gave better retrieval of the lesions than injection then feeding study
- In Feeding then injection of CCL4, urine only made retrieval of the lesions induced by CCL4 in testis
- Urine gave better retrieval of the lesions induced by CCL4 than milk in liver and kidney
- Combination showed retrieval of the lesions induced by CCL4 in testis, however; gave lesions similar to those observed in CCL4 in liver and kidney. Of importance, combination between milk and urine is not recommended either in prophylaxis or in treatment (before and after treatment). Further investigation needed to determine the cause of such antagonism in their protective action

ACKNOWLEDGEMENT

This project was financially supported by Deanship of Scientific Research, King Faisal University, Ministry of Higher Education, Kingdom of Saudi Arabia.

REFERENCES

- Abraham, P., G. Wilfred and S.P. Cathrine, 1999. Oxidative damage to the lipids and proteins of the lungs, testis and kidney of rats during carbon tetrachloride intoxication. Clin. Chim. Acta, 289: 177-179.
- Adewole, S.O., A.A. Salako, O.W. Doherty and T. Naicker, 2007. Effect of melatonin on carbon tetrachloride-induced kidney injury in Wistar rats. Afr. J. Biomed. Res., 10: 153-164.
- Al-Attas, A.S., 2009. Determination of essential elements in milk and urine of camel and in *Nigella sativa* seeds. Arabian J. Nucl. Sci. Applic., 42: 59-67.
- Al-Hashem, F., 2009. Camel's milk protects against aluminum chloride-induced toxicity in the liver and kidney of white albino rats. Am. J. Biochem. Biotechnol., 5: 98-109.
- Al-Hashem, F., M. Dallak, N. Bashir, M. Abbas, R. Elessa, M. Khalil and M. Al-Khateeb, 2009. Camel milk protects against cadmium chloride toxicity in white albino rats. Am. J. Pharmacol. Toxicol., 4: 107-117.
- Althnaian, T., I., Albokhadaim and S.M. El-Bahr, 2013. Biochemical and histopathological study in rats intoxicated with carbontetrachloride and treated with camel milk. Springer Plus, Vol. 2. 10.1186/2193-1801-2-57.
- Bancroft, J.D., 2008. Theory and Practice of Histological Techniques. 6th Edn., Elsevier Health Sciences, USA.
- El-Hummdi, L.A.T., 2006. The influence of camel's urine and milk on histopathological responses of mammalian kidney to anticoagulant drug (Enoxaparin Sodium) treatment. Egypt. J. Comp. Path. Clin. Path., 20: 53-71.
- Eman, A.A., S.I. Zein and M.E. Azza, 2010. Protective effect of curcuma longa against CCL₄ induced oxidative stress and cellular degeneration in rats. Global Vet., 5: 272-281.
- Ganu, G., T.A. Deshmukh and A. Middha, 2013. Potential hepatoprotective activity from extracts of *Mimusops Elengi* Linn. Pharma Res. Library, 1: 342-347.
- Hasseeb, M.M., F.A. Al-Hizab and M.A.H. Hamouda, 2013. Impacts of grape seed oil supplementation against the acrylamide induced lesions in male genital organs of rats. Pak. Vet. J., 33: 282-286.
- Kalinichenko, V.V., D. Bhattacharyya, Y. Zhou, G.A. Gusarova, W. Kim, B. Shin and R.H. Costa, 2003. *Foxf1* +/- mice exhibit defective stellate cell activation and abnormal liver regeneration following CCL₄ injury. Hepatology, 37: 107-117.
- Khalifa, S.A., 2006. Effect of Camel's urine and milk, honeybee with *Nigella sativa* mixture and ginger on the toxic potentials of haloperidol (Antipsychotic Agents) on fertility in the male albino rats. J. Egypt. Soc. Toxicol. Special Issue, 34: 119-129.
- Khalifa, S.A., R.A. Al-Elyani, L.A. El-Hummdi and A.D. Al-Ailwani, 2009. The effect of camel's urine and milk on hepatic toxicity of male rats treated with carbon tetrachloride (a histological study). Sci. J. King Faisal Univ. (Basic Applied Sci.), 10: 35-62.
- Khalifa, S.A.M., R.A.A. Al-Elyani and A.D.A. Al-Alwani, 2010. Compared effect of camel urine mixture, milk and chemotherapy on liver toxicity by carbon tetrachloride (Ultrastructure study). Saudi J. Biol. Sci., 17: 135-144.
- Khan, M.R. and D. Ahmed, 2009. Protective effects of *Digera muricata* (L.) Mart. on testis against oxidative stress of carbon tetrachloride in rat. Food Chem. Toxicol., 47: 1393-1399.
- Kim, Y.C., H.K. Yim, Y.S. Jung, J.H. Park and S.Y. Kim, 2007. Hepatic injury induces contrasting response in liver and kidney to chemicals that are metabolically activated: Role of male sex hormone. Toxicol. Applied Pharmacol., 223: 56-65.

- Knoess, K.H., 1979. Milk production of the dromedary. Proceedings of the 1st International Symposium on Camels, December 18-20, 1979, Sudan, pp: 201-214.
- Mal, G., D.S. Sena, V.K. Jain and M.S. Sahani, 2001. Therapeutic utility of camel milk as nutritional supplement in chronic pulmonary tuberculosis. *Livest. Int.*, 7: 4-8.
- Misawa, Y., K. Watanabe, T. Sakurai, E. Fujii, K. Tsukamoto, A. Kato and T. Sugimoto, 2000. Collaborative work to evaluate toxicity on male reproductive organs by repeated dose studies in rats. Testicular toxicity of 2 or 4 week repeated or single-dose administration of a novel platinum complex. *J. Toxicol. Sci.*, 25: 117-127.
- Mona, A.K., 2003. Antibacterial effect of camel urine (*Camelus dromedaries*). M.Sc. Thesis, Medicine University of Khartoum, Sudan.
- Ogeturk, M., I. Kus, N. Colakoglu, I. Zararsiz, N. Ilhan and M. Sarsilmaz, 2005. Caffeic acid phenethyl ester protects kidneys against carbon tetrachloride toxicity in rats. *J. Ethnopharmacol.*, 97: 273-280.
- Ohaj, H.M., 1998. Clinical trial for treatment of ascitis with camel urine. M.Sc. Thesis, University of the Gezira, Sudan.
- Ozturk, F., M. Ucar, I.C. Ozturk, N. Vardi and K. Batcioglu, 2003. Carbon tetrachloride-induced nephrotoxicity and protective effect of betaine in Sprague-Dawley rats. *Urology*, 62: 353-356.
- Rajesh, M.G. and M.S. Latha, 2004. Carbon tetrachloride *Glycyrrhiza glabra* Linn. On carbon tetra chloride induced peroxidative damage. *Indian J. Pharmacol.*, 36: 284-287.
- Rao, M.B., R.C. Gupta and N.N. Dastur, 1970. Camel milk and milk products. *Ind. J. Dairy Sci.*, 23: 71-78.
- Weber, L.W., M. Boll and A. Stampfl, 2003. Hepatotoxicity and mechanism of action of haloalkanes: Carbon tetrachloride as a toxicological model. *Crit. Rev. Toxicol.*, 33: 105-136.
- Yagil, R. and C. van Creveld, 2000. Medicinal use of camel milk. Fact or Fancy? Proceedings of the 2nd International Camelid Conference on Agro-Economics of Camelids, September 8-12, 2000, Almaty, Kazakhstan.
- Yildiz, H., A.S. Durmus, H. Simsek and M. Yaman, 2011. Protective effect of sildenafil citrate on contralateral testis injury after unilateral testicular torsion/detorsion. *Clinics*, 66: 137-142.
- Young, I.S. and J.V. Woodside, 2001. Antioxidants in health and disease. *J. Clin. Pathol.*, 54: 176-186.
- Yousef, M.I., 2004. Aluminum-induced changes in hemato-biochemical parameters, lipid peroxidation and enzyme activities of male rabbits: Protective role of ascorbic acid. *Toxicology*, 199: 47-57.