

## Use of Power Doppler for the Assessment of Vascularization in Equine Tendinitis Treated with Mesenchymal Stem Cells

<sup>1</sup>Armando de M. Carvalho, <sup>2</sup>Luis E.C. Alvarez, <sup>2</sup>Patricia G.G. Oliveira, <sup>2</sup>Cynthia P. Vendruscolo,

<sup>3</sup>Andrei Moroz, <sup>3</sup>Elenice Deffune, <sup>2</sup>Carlos A. Hussni and <sup>2</sup>Ana Liz G. Alves

<sup>1</sup>Department of Veterinary Surgery and Anesthesiology, School of Veterinary Medicine, University of Cuiaba, 78065-900 Cuiaba, Mato Grosso, Brazil

<sup>2</sup>Department of Veterinary Surgery and Anesthesiology, School of Veterinary Medicine and Animal Science,

<sup>3</sup>Blood Center, Botucatu Medical School, Sao Paulo State University, Rubiao Junior, 18618-970 Botucatu, Sao Paulo, Brazil

---

**Abstract:** Tendinous lesions are very common in athlete horses. The process of tendon healing is slow and the quality of the new tissue is often inferior to the original, leading in many cases to recurrence of the lesion. One of the main reasons for the limited healing capacity of tendons is its poor vascularization. At present, cell therapy is used in equine practice for the treatment of several disorders including tendinitis, desmitis and joint disease. However, there is little information regarding the mechanisms of action of these cells during tissue repair. It is known that Mesenchymal Stem Cells (MSCs) release several growth factors at the site of implantation, some of which promote angiogenesis. Comparison of blood flow using power Doppler ultrasonography was performed after the induction superficial digital flexor tendon tendinitis and implantation of adipose tissue-derived MSCs in order to analyze the effect of cell therapy on tendon neovascularization. For quantification of blood vessel histopathological examinations were conducted. Increased blood flow and number of vessels was observed in treated tendons up to 30 days after cell implantation, suggesting promotion of angiogenesis by the cell therapy.

**Key words:** Superficial digital flexor tendon, tendinitis, neovascularization, power Doppler ultrasonography, MSCs

---

### INTRODUCTION

Tendons are bands of specialized tissue connecting and transmitting forces from muscle to bone. Due to its high incidence, long rehabilitation periods and high rate of recurrence, inflammation of the Superficial Digital Flexor Tendon (SDFT) is an important cause of lameness and low performance in horses. The incidence of tendinitis in athlete horses varies from 11-46% and is the first cause of retirement of race horses (Lam *et al.*, 2007).

Slow repairing and formation of mechanically inferior extracellular matrix in tendons are mostly caused by poor vascularity, low mitotic activity and reduced number of progenitor cells (Violini *et al.*, 2009). Thus, blood supply in injured tendons would have to be good enough to activate the extrinsic mechanism of healing as well as to carry nutrients, inflammatory mediators and proteolytic enzymes to and from the tendons (Fenwick *et al.*, 2002). Nevertheless, poor vascularity of the fibrous tissue that

repairs the tendon after injury has been suggested as an important cause of lesion recurrence (Stromberg, 1971). It is thought that the preexisting Mesenchymal Stem Cells (MSCs) remain quiescent at the perivascular niche. When injured, tissue itself stimulates angiogenesis and probably differentiation of MSCs into proper cell types (Caplan, 2009). Until now, however, differentiation and transformation of MSCs into the same cell type of the implanted tissues has not been demonstrated *in vivo* (Koch *et al.*, 2008).

Neovascularization is one of the landmarks in wound repair and an important characteristic of tendon healing (Fenwick *et al.*, 2002). Angiogenesis is the growth of new blood vessels from pre-existing vessels and is an essential process for the development and maintenance of tissues (Kachgal and Putnam, 2011). Stromal cells from adipose tissue release significant quantities of angiogenesis-related mediators such as Vascular Endothelial Growth Factor (VEGF), Hepatic Growth Factor

---

**Corresponding Author:** Ana Liz Garcia Alves, Department of Veterinary Surgery and Anesthesiology, School of Veterinary Medicine and Animal Science, Sao Paulo State University, Rubiao Junior, 18618-970 Botucatu, Sao Paulo, Brazil

(HGF), Placental Growth Factor (PGF), Fibroblast Growth Factor 2 (FGF-2), Transforming Growth Factor (TGF- $\beta$ ) and angiopoietin-1 (Schaffler and Buchler, 2007). The secretion of angiogenesis-related cytokines probably makes MSCs appropriate for regenerative cell therapy (Nakagami *et al.*, 2006). The beneficial potential of the MSCs for tissue repair based on the release of angiogenic factors was also outlined after *in vitro* studies on the attraction and interaction of these cells with new formed vascular structures (Sorrell *et al.*, 2009).

Several studies have been already published on the use of MSCs for tendon repair in horses (Schnabel *et al.*, 2013), nevertheless there is no complete knowledge of the safety, efficiency and basic characteristics of these cells (Koch *et al.*, 2008). Research on cells from the stromal vascular fraction of adipose tissue have increased due to its relative abundance, easy-obtaining, high proliferative capacity and potential for differentiation into several cellular types (De Ugarte *et al.*, 2003). Recent studies demonstrate that Mesenchymal Stem Cells (MSC) derived from adipose tissue (AdMSCs) have potential for use in cell therapy in equine practice (Del Bue *et al.*, 2008; Nixon *et al.*, 2008; Carvalho *et al.*, 2011, 2013).

Doppler devices use color coding for velocity measurement. Color flow Doppler displays only the mean velocity and it has limited maximal detectable velocity (Risselada *et al.*, 2006). The sensibility and specificity of color Doppler in assessing patellar tendinitis was 92 and 100%, respectively (Kristoffersen *et al.*, 2005). Unlike the color mode, power Doppler provides no data on flow direction or velocity but it is more sensitive to the presence and volume of blood flow irrespective of the angle of incidence, enabling visualization of small vessels (Risselada *et al.*, 2006). Recently, power Doppler has shown to be useful in the diagnosis and monitoring of tendinopathy in humans. The power Doppler is superior for detection and monitoring of increased vascularity in inflamed tissues (Boesen *et al.*, 2007).

## MATERIALS AND METHODS

Eight clinically normal mares (2-3.5 years old) were used. Normal status of ligaments and tendons were previously assessed by ultrasonography. The protocol was approved by the ethics committee for animal experimentation of the university (number: 213/2008).

Two groups of four mares each were formed: Group A (GA), the mares were submitted to twice fortnightly ultrasound scanning followed by a bilateral biopsy of the SDFT 60 days after lesion induction and Group B (GB), mares were submitted to fortnightly ultrasound scanning up to 150 days after lesion induction followed by bilateral biopsy of the SDFT for histopathological analyses.

Tendinitis induction, adipose tissue collection and AdMSCs culture were performed as described by Carvalho *et al.* (2011). Briefly, ultrasound-guided injection (Logiq 3, General Electric, Sangdaewon-Dong, Korea) of 2.5 mg of type I collagenase (Collagenase type 1: C-0130, Sigma Pharmaceutical, St. Louis, Missouri) diluted in 1.0 mL of sterile water was achieved bilaterally in the SDFT at the mid metacarpal region. Sedation was performed with 10% xylazine (0.8 mg kg<sup>-1</sup>, i.v.) (Sedazine, Fort Dodge, Campinas, SP, Brazil). Then, region of interest was aseptically prepared followed by perineural blockage of the lateral and medial digital palmar nerves with 2% lidocaine chloridrate (Xylestesin, Cristalia Produtos Quimicos e Farmaceuticos Ltda, Itapira, SP, Brazil).

Adipose tissue was retrieved from the base of the tail. The mares were sedated with xylazine (1 mg kg<sup>-1</sup>, i.v.) followed by local anesthesia with 2% lidocaine chloride using an inverted L-block. Approximately 5 mL of adipose tissue were collected and immersed in a sterile 50 mL conic flask containing RPMI-1640 medium (Sigma Chemical Co., St. Louis, MO, USA).

Samples were washed with PBS in sterile Falcon tubes and the extracellular matrix was enzymatically digested with 0.02% type I collagenase (Gibco, Grand Island, NY, USA) in RPMI-1640 medium and incubated overnight at 37°C, under 5% CO<sub>2</sub>. Collagenase was neutralized with Knockout DMEM (Dulbecco's modified Eagle's medium, Gibco, Grand Island, NY, USA) containing 10% FBS (Fetal Bovine Serum, Gibco, Grand Island, NY, USA). After centrifugation, supernatant was discharged and added DPBS (Dulbecco's Phosphate Buffered Saline, Gibco, Grand Island, NY, USA) to the pellet. After a second centrifugation, cells were quantified and viability was carried out by exclusion test using 0.02% Trypan Blue (Trypan Blue Stain, Gibco, Grand Island, NY, USA).

Cells were kept at 37°C under 5% CO<sub>2</sub> with Knockout DMEM and 10% FBS culture medium. The medium was changed every 3 days and when minimum confluence of 70% of the plate occurred, trypsinization was conducted (Carvalho *et al.*, 2011).

The 30 days after tendinitis induction 10×10<sup>6</sup> AdMSCs were implanted in the lesion. The cells were suspended in 0.5 mL of autologous serum and placed in 1 mL syringes which were refrigerated until use. Ultrasound-guided injection of the cells was performed at the center of the lesion in one forelimb of each mare using a 21G needle. No substance was administered into the contralateral limb which was denominated the control limb.

Physiotherapy was performed after cell implantation as follows: days 46-60, 15 min walking once a day

(GA and GB); days 61-90, 15 min walking twice a day (GB); days 91-120, 30 min walking once a day (GB) and days 121-150, 30 min walking twice a day (GB).

Transversal power Doppler scans of the SDFT were performed every 2 weeks after cell implantation using an ultrasound device (Logiq 3, General Electric, Sangdaewon-Dong, Korea) with a 7.5 MHz linear transducer, 25 Doppler Gain and 0.3 MHz Pulse Repetition Frequency (PRF) in order to identify the presence of blood vessels. A copious quantity of coupling gel was applied and the transducer was gently placed at the Region of Interest (ROI) to minimize the pressure over the tendon. Power Doppler exams were recorded for further evaluation of the vessels at the ROI using a score from 0-3. Classification of the signals was based on the combination of intensity and length (Table 1). The clips were analyzed by two blinded independent evaluators and the scores from both were statistically calculated. Group A was evaluated fortnightly until day 60 after lesion induction. Group B was also examined every 15 days until 150 days after collagenase administration.

In Group A, biopsy was performed on day 60 post-lesion induction whereas in Group B, collection of tendinous material was performed on day 150 post-lesion induction. Routine inhalatory anesthesia with isoflurane (Isoflurano, Cristalia Produtos Quimicos e Farmaceuticos Ltda, Itapira, SP, Brazil) and local anesthetic blockage (20 total mL of 2% lidocaine) were performed. Skink was incised at ROI and the SDFT was isolated. The tissue collected was immersed in 10% buffered formalin. The paratenon and the skin were then sutured followed by compressive bandage and phenylbutazone, 4.4 mg kg<sup>-1</sup>, i.v. for 5 days (Equipalazone, Vitalfarma Ltda, Sao Sebastiao do Paraiso, MG, Brazil).

For histopathological analyses, tendon fragments were stained with Hematoxylin-Eosin (HE) followed by vessels' quantification by a blinded pathologist (Table 2). Data were scored from 0-3 and compared between

groups using the Wilcoxon nonparametric and Kolmogorov-Smirnov tests using the GraphPad InStat 3.05 Statistical Software Package (Graph Pad Software Inc., San Diego, CA) with p<0.05. The results are showed as the median value of the score obtained for each SDFT belonging to both MSCs-treated and control limbs per group (GA and GB).

**RESULTS**

In the power Doppler evaluation the blood flow was not detected in tendons during the pre-lesion evaluation (day 0). However, blood flow was present into the SDFT of limbs treated with MSCs the days 15 and 30 post-implantation. After 45 days from lesion induction (i.e., 15 days after cell implantation), five of the treated limbs had a power Doppler score of 1.1 and 60 days after lesion (i.e., 30 days from MSCs implantation) 4 of the treated limbs had a mean power Doppler score of 0.8 (Fig. 1). Flow was not observed after the 60th day from the beginning of the experiment in any of the animals. Regarding the control limbs, no blood flow was identified in the SDFT at any evaluation moment.

In the histopathological analysis of GA, the AdMSCs-treated group showed a moderate to strong increase in number of vessels (median, 2.5) while the histopathological findings obtained for the GA controls showed a mild to moderate increase in vascularity

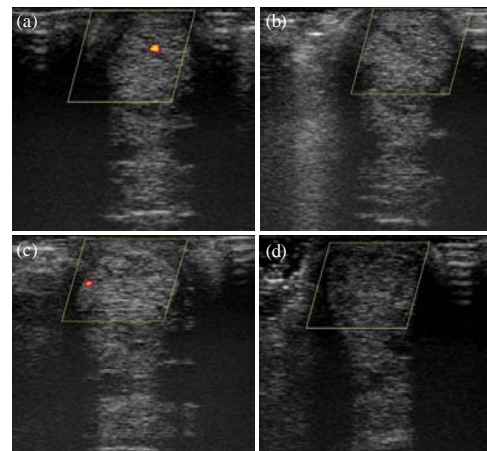


Fig. 1: Assessment of the tendinous blood flow using power Doppler; a) evaluation of the treated limbs after 15 days from cell implantation; b) evaluation of the control limbs after 15 days from cell implantation; c) evaluation of the treated limbs after 30 days from cell implantation; d) evaluation of the control limbs after 30 days from cell implantation

Table 1: Score for power Doppler evaluation of the tendinous blood flow considering length and intensity of the signal

Scores	Description
0	Absence of blood flow
1	Blood flow shorter than 3 sec and low intensity
2	Blood flow shorter than 6 sec and medium intensity
3	Blood flow longer than 6 sec and high intensity

Table 2: Score Used for each variable during the histopathological evaluation of the healing process of the SDTF in the MSCs treated and control limbs

Variables	Scores and criteria
Neovascularization (vesselnumbers)	0 (Normal)
	1 (Mild increase)
	2 (Moderate increase)
	3 (Severe increase)

(median, 1.5). Differences in the number of vessels ( $p < 0.05$ ) were observed between treated and control tendons in GA.

Regarding the histopathological findings for GB both the AdMSCs-treated and control groups had a mild increase in vascularity (median, 1.0). Differences in the number of vessels between treated and control tendons in GB were not observed.

## DISCUSSION

Most of the literature regarding the use of MSCs in large animals is based on clinical reports of a small number of patients without control groups or long term follow-up periods (Schnabel *et al.*, 2013). Until now, no research has been performed on the effect of the cell therapy over tendinous vascularity in horses. Thus, the research assess the potential of the power Doppler technique in detecting vascularity caused by AdMSCs associated with autologous serum in equine tendon.

Previous studies evidenced that the volume of drugs to be injected in tendons depends on the degree of the lesion. Thus, it is stated that high volumes can be potentially harmful for tendon healing (Van den Belt *et al.*, 1993). The intralesional injection of MSCs did not cause evident harmful reaction in the research (i.e., swelling, temperature increase or pain). Nevertheless, studies should be conducted in order to find out the ideal volume and cell concentration before clinical implementation of MSCs. It has been described that MSCs are potentially cytotoxic when injected in high concentrations in melanoma. Under these conditions, MSCs release several angiogenesis inhibitors that induce apoptosis and inhibit tumor growth (Otsu *et al.*, 2009).

Whilst the latter effects of MSCs have potential in cancer therapy, the release of angiogenesis inhibitors would be undesirable for tendon repair. Yet, data on progenitor cells causing similar effects in tendons than in tumors have not been reported.

A study using Doppler evaluation with the limb raised found a minimum visible blood flow in healthy flexor tendons as well as an increased vascular pattern after tendinous lesion (Smith, 2008). In the research, all the ultrasonographic examinations were carried out with the limb bearing weight and no Doppler pulses were identified during both pre-lesion and pre-treatment evaluation. A vascular pattern was observed in treated animals but no in the control group.

Results from the power Doppler evaluation showed a higher intralesional blood flow 30 days after cell implantation. Accordingly, histopathological examination revealed increased number of blood vessels in the treated

limbs when compared with the control limbs which may be related to the release of several angiogenic growth factors by the MSCs, e.g., VEGF, HGF, FGF-2, TGF- $\beta$  and angiopoietin-1 (Schaffler and Buchler, 2007). These results are important evidence that the injected AdMSCs suspended in autologous serum interact in the modulation of local vascularization and has therapeutic potential in tendinitis. Nobel research *in vivo* has to be conducted using different techniques for detection and quantification of angiogenesis-related growth factors after the administration of AdMSCs in order to understand the relationship between the progenitor cells and autologous serum injected in the healing tissue and the release of angiogenic factors. To verify this hypothesis, however, it would be necessary to dose the angiogenesis-related growth factors after AdMSCs implantation for tendinitis therapy in horses. Unfortunately, the findings of the research could not be directly related to the concentration angiogenic factors, e.g., equine VEGF because of the lack of an adequate method to quantify it (Bosch *et al.*, 2011).

Vascularization and increase of the vascular permeability are important aspects of tendon repair (Sharma and Maffulli, 2005). This research confirms the findings of Del Bue *et al.* (2008), Nixon *et al.* (2008) and Carvalho *et al.* (2013) which claim that the administration of equine AdMSCs has potential therapeutic effect in tendinitis therapy due to the stimulus of blood flow and increased number of local progenitor cells, favoring the formation of an extra-cellular matrix similar to a healthy tendon. Increased vascularity of tendon has also been associated with chronic tendinitis and with the emergence of new nerves running parallel to the new vessels. Such nerves have been also described as causing pain and lameness in human beings (Alfredson and Ohberg, 2005). The hypothesis of persistent formation of new vessels was not ruled out in this study because blood flow was not detected after the 30th day from cell implantation. However, clinical signs (e.g., pain and lameness) were not detected in the animals after cell implantation (Carvalho *et al.*, 2011). The absence of clinical signs in the study is inconsistent with chronic tendinitis and supports the idea of tendon repair. New studies have to be performed to verify the presence of new nerves running together with the new vessels after implantation of adipose tissue-derived MSCs in equine tendinitis. In the opinion, these studies are critical because as in cases of chronic tendinitis these nerves would increase sensitivity at the site of the implant further accentuating pain and so lameness.

Increase in blood flow and number of blood vessels was detected neither in treated nor in control limbs from the 30th day after AdMSCs implantation until the end

of the study, probably due to the lack of angiogenesis-related growth factors. These results are in agreement with the results obtained by Carvalho *et al.* (2013). Hypervascularity is expected during the tissue repair process but there is decreased vascularity with the progress of tendon repair (Smith, 2008).

Assessment of blood flow using power Doppler is a non-invasive technique useful in detecting angiogenesis in the superficial digital flexor tendon in horses. A single intratendinous injection of adipose tissue-derived MSCs suspended in autologous blood serum was enough to increase vascularization until the 30th day after therapy when compared to the process of normal repair of experimentally induced tendinitis in horses. The increased vascularity might have contributed to the improvement in quality of the tendinous tissue of the treated group when compared with the control group.

### CONCLUSION

In this study, researchers used power Doppler to assess vascularization throughout the healing process of experimentally induced tendinitis in eight mares, treated with a single injection of AdMSCs 30 days after lesion induction. Histopathological analysis of the tendons was also performed to quantify blood vessels and correlate the number of vessels and Doppler results. The hypothesis is that injection of AdMSCs into injured tendons promotes formation of new vessels due to the release of angiogenic mediators there by increasing the local blood flow and helping in the process of tissue repair.

### ACKNOWLEDGEMENTS

Fundacao de Amparo e Pesquisa do, Estado de Sao Paulo (FAPESP) for the first researchers scholarship. Coordenacao de Aperfeicoamento de Pessoal de Nivel Superior (CAPES) PEC/PG for the second researcher's scholarship.

### REFERENCES

Alfredson, H. and L. Ohberg, 2005. Neovascularisation in chronic painful patellar tendinosis-promising results after sclerosing neovessels outside the tendon challenge the need for surgery. *Knee Surg. Sports Traumatol. Arthrosc.*, 13: 74-80.

Boesen, M.I., S. Nami, H. Langberg, M. Boesen, J. Falk-Ronne, H. Bliddal and S. Torp-Pedersen, 2007. Colour Doppler ultrasonography and sclerosing therapy in diagnosis and treatment of tendinopathy in horses-a research model for human medicine. *Knee Surg. Sports Traumatol. Arthrosc.*, 15: 935-939.

Bosch, G., M. Moleman, A. Barneveld, P.R. van Weeren and H.T.M. van Schie, 2011. The effect of platelet-rich plasma on the neovascularization of surgically created equine superficial digital flexor tendon lesions. *Scand. J. Med. Sci. Sports*, 21: 554-561.

Caplan, A.I., 2009. Why are MSCs therapeutic? New data: New insight. *J. Pathol.*, 217: 318-324.

Carvalho, A.D., P.R. Badial, L.E. Alvarez, A.L. Yamada and A.S. Borges *et al.*, 2013. Equine tendonitis therapy using mesenchymal stem cells and platelet concentrates: A randomized controlled trial. *Stem Cell Res. Ther.*, Vol., 4. 10.1186/scrt236.

Carvalho, A.D.M., A.L.G. Alves, P.G.G. de Oliveira, L.E.C. Alvarez and R.L. Amorim *et al.*, 2011. Use of adipose tissue-derived mesenchymal stem cells for experimental tendinitis therapy in equines. *J. Equine Vet. Sci.*, 31: 26-34.

De Ugarte, D.A., Z. Alfonso, P.A. Zuk, A. Elbarbary and M. Zhu *et al.*, 2003. Differential expression of stem cell mobilization-associated molecules on multi-lineage cells from adipose tissue and bone marrow. *Immunol. Lett.*, 89: 267-270.

Del Bue, M., S. Ricco, R. Ramoni, V. Conti and G. Gnudi *et al.*, 2008. Equine adipose-tissue derived mesenchymal stem cells and platelet concentrates: Their association *in vitro* and *in vivo*. *Vet. Res. Commun.*, 32: 51-55.

Fenwick, S.A., B.L. Hazleman and G.P. Riley, 2002. The vasculature and its role in the damaged and healing tendon. *J. Arthritis. Res.*, 4: 252-260.

Kachgal, S. and A.J. Putnam, 2011. Mesenchymal stem cells from adipose and bone marrow promote angiogenesis via distinct cytokine and protease expression mechanisms. *Angiogenesis*, 14: 47-59.

Koch, T.G., L.C. Berg and D.H. Betts, 2008. Concepts for the clinical use of stem cells in equine medicine. *Can. Vet. J.*, 49: 1009-1017.

Kristoffersen, M., L. Ohberg, C. Johnston and A. Alfredson, 2005. Neovascularisation in chronic tendon injuries detected with colour Doppler ultrasound in horse and man: Implications for research and treatment. *Knee Surg. Sports Traumatol. Arthrosc.*, 13: 505-508.

Lam, K.H., T.D.H. Parkin, C.M. Riggs and K.L. Morgan, 2007. Descriptive analysis of retirement of Thoroughbred racehorses due to tendon injuries at the Hong Kong Jockey Club (1992-2004). *Equine Vet. J.*, 39: 143-148.

Nakagami, H., R. Morishita, K. Maeda, Y. Kikuchi, T. Ogihara and Y. Kaneda, 2006. Adipose tissue-derived stromal cells as a novel option for regenerative cell therapy. *J. Atheroscler. Thromb.*, 13: 77-81.

- Nixon, A.J., L.A. Dahlgren, J.L. Haupt, A.E. Yeager, D.L. Ward, 2008. Effect of adipose-derived nucleated cell fractions on tendon repair in horses with collagenase-induced tendinitis. *Am. J. Vet. Res.*, 69: 928-937.
- Otsu, K., S. Das, S.D. Houser, S.K. Quadri, S. Bhattacharya and J. Bhattacharya, 2009. Concentration-dependent inhibition of angiogenesis by mesenchymal stem cells. *Blood*, 113: 4197-4205.
- Risselada, M., M. Kramer, J.H. Saunders, P. Verleyen and H. Van Bree, 2006. Power Doppler assessment of the neovascularization during uncomplicated fracture healing of long bones in dogs and cats. *Vet. Radiol. Ultrasound*, 47: 301-306.
- Schaffler, A. and C. Buchler, 2007. Concise Review: Adipose tissue-derived stromal cells-basic and clinical implications for novel cell-based therapies. *Stem Cells*, 25: 818-827.
- Schnabel, L.V., L.A. Fortier, C.W. McIlwraith and K.M. Nobert, 2013. Therapeutic use of stem cells in horses: Which type, how and when? *Vet. J.*, 197: 570-577.
- Sharma, P. and N. Maffulli, 2005. Tendon injury and tendinopathy: Healing and repair. *J. Bone Joint Surg. Am.*, 87: 187-202.
- Smith, R.K.W., 2008. Tendon and ligament injury. *Proc. Am. Assoc. Equine Pract.*, 54: 475-501.
- Sorrell, J.M., M.A. Baber and A.I. Caplan, 2009. Influence of adult mesenchymal stem cells on *in vitro* vascular formation. *Tissue Eng. Part. A*, 15: 1751-1761.
- Stromberg, B., 1971. The normal and diseased superficial flexor tendon in race horses. A morphologic and physiologic investigation. *Acta Radiol. Suppl.*, 305: 1-94.
- Van den Belt, A.J.M., P.R. Keg, K.J. Dik and A. Barneveld, 1993. The correlation between the dose and distribution of intratendinous fluid injections in the flexor tendons/ligaments of the horse. *J. Vet. Med. Ser. A*, 40: 713-719.
- Violini, S., P. Ramelli, L.F. Pisani, C. Gorni and P. Mariani, 2009. Horse bone marrow mesenchymal stem cells express embryo stem cell markers and show the ability for tenogenic differentiation by *in vitro* exposure to BMP-12. *BMC Cell Biol.*, Vol., 10. 10.1186/1471-2121-10-29.