

An Outbreak of Colibacillosis in a Broiler Farm

¹Nur Hardy bin Abu Daud, ²Nwe Nwe Htin, ¹Farah Hanif Paan, ¹Than Kyaw,
¹Aung Tun Khaing, ³Yusuf Abba and ³Faez Firdaus Jesse Abdullah
¹Faculty of Veterinary Medicine,
²Faculty Agro-Based Industry, University Malaysia Kelantan, Kelantan, Malaysia
³Faculty of Veterinary Medicine, University Putra Malaysia,
Serdang, Selangor, Darul Ehsan, Malaysia

Abstract: *Escherichia coli* is one of the most economically important bacteria responsible for early chick mortality in poultry farms worldwide. In this report, researchers investigated a case of sporadic mortality (15%) in 15-18 days old Cobb 500 broiler chicks. The chicks were weak with respiratory distress and non-uniform growth rate. Postmortem examination showed evidence of polyserositis with fibrinous hepatitis, pericarditis, peritonitis and air sacculitis as the major findings observed. Bacteriological culture of affected organs showed evidence of *E. coli* growth on blood agar. The bacteria was found to be resistant to amoxicillin, clindamycin, streptomycin and trimethoprim while intermediate susceptibility to oxytetracycline and susceptibility to gentamycin were equally observed. The chicks were treated with gentamycin (5-10 mg kg⁻¹ orally) for 5 days and multivitamin (5 g L⁻¹) was given in drinking water for 3 days. Prompt diagnosis and treatment of cases of colibacillosis is crucial to ensuring optimal productivity in poultry farms.

Key words: Colibacillosis, broiler, antibiotic, postmortem, treatment

INTRODUCTION

Colibacillosis is one of the commonest infectious disease of farmed poultry considered as one of the principal causes of morbidity and mortality in young chicks (Li *et al.*, 2005). The condition has been associated with heavy economic losses in the poultry industry by its association with various disease conditions either as a primary or secondary pathogen (Yousseff *et al.*, 2008).

Colibacillosis is most commonly seen following upper respiratory tract infection (such as Infectious Bronchitis or Mycoplasmosis). It is also associated with immunosuppressive diseases such as Infectious Bursal Disease (Gumboro Disease) in chickens, Haemorrhagic Enteritis in turkeys and in young birds that are immunologically immature. Colibacillosis is caused by the bacterium *Escherichia coli* which has been reported worldwide in chickens and turkeys (Kabir, 2010). Colibacillosis in poultry is characterized in its acute form by septicaemia resulting in death and in its subacute form by pericarditis, airsacculitis and perihepatitis (Nakamura *et al.*, 1985). The bacterium has over a hundred serogroups with the most common and pathogenic ones being O78, O1, O2, O15 and O55 (Kabir, 2010). Colibacillosis is usually seen in young chicks up to 3 weeks of age, however in older birds pullorum disease and diarrhoea have been reported. Enterotoxigenic *E. coli* strains have been seldomly isolated in chickens suffering from diarrhoea and occasionally in clinically healthy

chickens and turkeys (Stordeur and Mainil, 2002; Vandekerckhove *et al.*, 2004; Kabir, 2010). Infection is by the oral or inhalation routes and via shell membranes, water, fomites with an incubation period of 3-5 days. Morbidity varies but mortality ranges from 5-20%. Avian Pathogenic *E. coli* (APEC) has been incriminated in a lot of cases of *E. coli* infection in both broilers and layers. It causes embryo mortality and omphalitis in chicks. Lesions observed are mainly polyserositis with deposition of fibrin in the air sacs, pericardium and liver (Yousseff *et al.*, 2008; Kabir, 2010).

Poor navel healing, mucosal damage due to viral infections and immunosuppression are some of the predisposing factors for Colibacillosis in chickens. In this report, researchers investigated a case of sporadic mortality associated with *E. coli* infection in a commercial broiler farm and highlight herein the stepwise protocol used to arrive at a diagnosis and treatment.

MATERIALS AND METHODS

Case report: A farmer reported a case of sporadic mortality of 15% in 15 days old Cobb 500 chicks to the Veterinary Teaching Hospital, University Malaysia, Kelantan. The farm has been operating for 20 years and houses around 50,000 birds divided in 8 open pen houses. Water and feed are tested regularly for quality assurance and conformation.

The birds have been vaccinated against Newcastle Disease (ND), Infectious Bronchitis (IB) and Gumboro. However, the farm has a history of ND outbreak three years ago. Effective Microbes (EM) are also given as supplements to the birds every 3 days. Routinely used antibiotics were tilmicosin and gentamycin.

Two stock batches of birds aged 15 and 18 days were noticed to show clinical signs and mortality. Clinical signs observed were lameness, respiratory problems (coughing and sneezing) and non-uniformity in growth. Some of the birds had pesty vent due to diarrhea. Feces was green with white to yellow urates. Severely affected individual birds were inactive and isolate themselves from the others with their eyes closed in a hunched position and a drooping head, neck and wings (Fig. 1 and 2).

Diagnostic plan

Sample collection and analysis: Postmortem examination was conducted on 60 chicks (55 moribond and 5 dead

chicks). Gross evaluation of the organs were done and the lesions observed recorded. Samples of the heart, liver and intestine were aseptically collected and sent for bacterial isolation, identification and antimicrobial susceptibility testing. Briefly, collected samples of the heart, liver and intestine were cultured onto blood agar, Mc Conkey agar and XLD agar and incubated for 24 h at 37°C. Biochemical test were conducted on the colonies and characteristics recorded. Disc Diffusion Method was used to test the antimicrobial susceptibility of the isolates obtained.

RESULTS AND DISCUSSION

Gross pathology: The most recurring gross lesion observed were fibrinous pericarditis, fibrinous perihepatitis and airsacculitis (Table 1). The air sacs were thickened, opaque and whitish with adherent caseous deposits.

Bacterial isolation and identification: The colonies were gram negative range from mucoid, small to big with white to grayish convex appearance. Biochemical test showed that the colonies are motile, lactose fermentants, citrate negative, urase negative, Methyl Red (MR) positive and Voges Proskaur (VP) negative. From these results, the bacteria was identified as *Escherichia coli*.

Antibiotic sensitivity test for *E. coli*: The result of the antimicrobial sensitivity test showed a remarkable susceptibility to gentamycin an intermediate susceptibility to tetracycline and resistance to amoxicillin, streptomycin, clindamycin and trimethoprim (Table 2).



Fig. 1: A few inappetent chicks



Fig. 2: A sick chick with open mouthed breathing

Table 1: Summary of gross pathological lesions observed in necropsized chicks (n = 60)

Post mortem finding	No. (%) in population
Fibrinous pericarditis	28 (46.6)
Fibrinous perihepatitis	26 (43.3)
Airsacculitis	23 (38.3)
Fibrinous peritonitis	19 (31.7)
Pale breast muscle	5 (8.3)
Liver congested	3 (5.0)
Gizzard erosion	1 (1.7)
Hydropericardium	1 (1.7)

Table 2: Result of antimicrobial susceptibility testing on *E. coli* isolated from infected organ samples

Antimicrobial agent	Disc code	Zone diameter interpretive standard (mm)			Result (mm)
		Sensitive (S)	Intermediate (I)	Resistant (R)	
Gentamycin	CN10	≥15	13-14	≤12	25-S
Amoxy cillin	AMC30	≥18	14-17	≤13	0-R
Streptomycin	S10	≥15	12-14	≤11	0-R
Clindamycin	K30	≥21	15-20	≤14	0-R
Trimethoprim	W5	≥16	11-15	≤10	0-R
Tetracycline	TE30	≥19	15-18	≤14	18-I

Treatment: Based on the antimicrobial sensitivity results, gentamycin (5-10 mg kg⁻¹, Orally) was given in drinking water for 5 days. This was followed by administration of multivitamin powder (5 g L⁻¹) in drinking water for 3 days.

Colibacillosis is one the main causes of early chick mortality in poultry. The disease affects young and old chickens and mortality is more severe in younger birds (Kabir, 2010). In this case, mortality was sporadic and clinical signs were mostly associated with the respiratory system; cough, respiratory distress. Postmortem findings were typical of colibacillosis with polyserositis in the liver, air sacs and pericardium (Fig. 3-6). These findings have been previously reported to be consistent in cases of colibacillosis in broiler chickens (Vandekerchove *et al.*, 2004; Li *et al.*, 2005; Yousseff *et al.*, 2008; Kabir, 2010). Pathogenicity of *E. coli* infection has been strongly associated to its virulence factors especially in the respiratory system (Stordeur and Mainil, 2002). Tonu *et al.* (2011) has highlighted that the division of *E. coli* into pathogenic and non-pathogenic strains was based on the ability to cause disease and difference or combination of virulence factors. The *E. coli* isolate in this study was resistance to a number of antimicrobial agents such as; amoxycillin, streptomycin, clindamycin and trimethoprim while intermediate susceptibility to tetracyclin and susceptibility to gentamycin were observed (Fig. 7). In a related study, Amara *et al.* (1995) reported high antibiotic resistance by *E. coli* to sulphonamides, oxytetracycline, trimethoprim+sulphamethoxazole and chloramphenicol; medium susceptibility to streptomycin, nalidixic acid, oxolinic acid, flumequine and enrofloxacin and low susceptibility to ampicillin, gentamycin, nitrofurans, colistins and rifampin. Antibiotic resistance is a genetic

trait associated with some *E. coli* strains and these genes can be detected using polymerase chain reaction (Diarrassouba *et al.*, 2007). The manifestation of these bacterial genes may be associated with indiscriminate use of antibiotics by farmers.

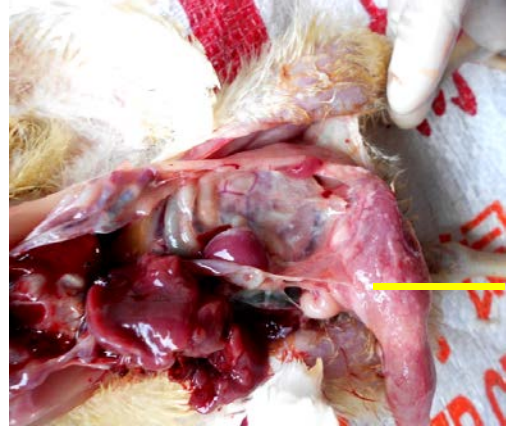


Fig. 4: Opacity of the air sacs due to fibrin deposition

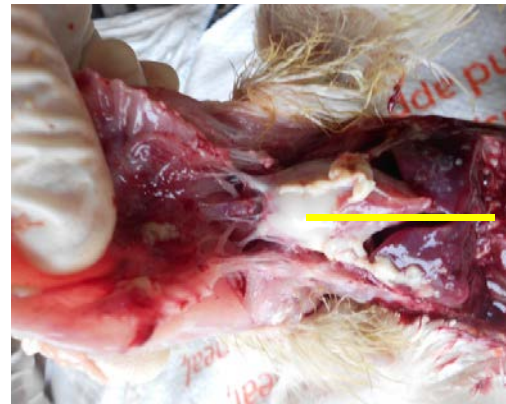

Fig. 5: Deposition of fibrin on the pericardial sac

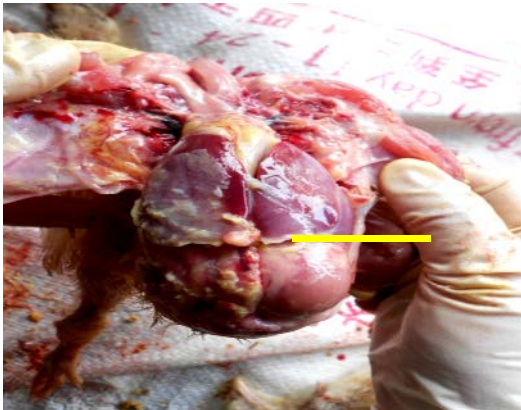

Fig. 3: Fibrinous coating on the surface of the liver

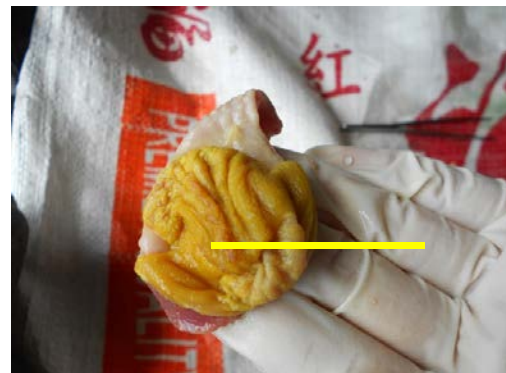


Fig. 6: An eroded area in the ventriculus (Gizzard)

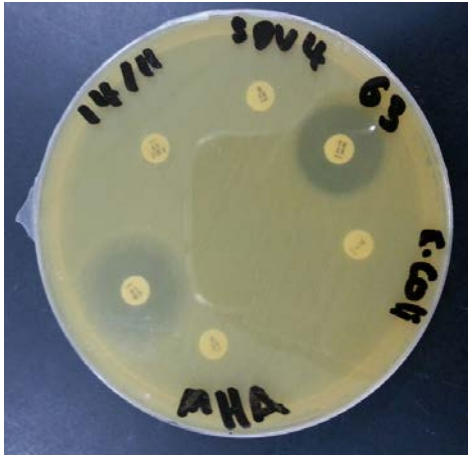

Fig. 7: Antimicrobial sensitivity test for *E. coli* on MHA agar

CONCLUSION

Colibacillosis is a leading cause of chick mortality in poultry farms worldwide. As observed in this case report, prompt diagnosis based on postmortem evaluation, bacterial culture and antimicrobial sensitivity testing is paramount in effectively managing cases in poultry farms.

REFERENCES

Amara, A., Z. Ziani and K. Bouzoubaa, 1995. Antibioresistance of *Escherichia coli* strains isolated in Morocco from chickens with colibacillosis. *Vet. Microbiol.*, 43: 325-330.

Diarrassouba, F., M.S. Diarra, S. Bach, P. Delaquis, J. Pritchard, E. Topp and B.J. Skura, 2007. Antibiotic resistance and virulence genes in commensal *Escherichia coli* and *Salmonella* isolates from commercial broiler chicken farms. *J. Food Prot.*, 70: 1316-1327.

Kabir, S.M.L., 2010. Avian colibacillosis and salmonellosis: A closer look at epidemiology, pathogenesis, diagnosis, control and public health concerns. *Int. J. Environ. Res. Public Health*, 7: 89-114.

Li, G., C. Laturnus, C. Ewers and L.H. Wieler, 2005. Identification of genes required for avian *Escherichia coli* septicemia by signature-tagged mutagenesis. *Infect. Immunity*, 73: 2818-2827.

Nakamura, K., M. Maeda, Y. Imada, T. Imada and K. Sato, 1985. Pathology of spontaneous colibacillosis in a broiler flock. *Vet. Pathol.*, 22: 592-597.

Stordeur, P. and J. Mainil, 2002. [Colibacillosis in poultry]. *Annales Medecine Veterinaire*, 146: 11-18 (In French).

Tomu, N.S., M.A. Sufian, S. Sarker, M.M. Kamal, N.H. Rahman and M.M. Hossain, 2011. Pathological study on colibacillosis in chickens and detection of *Escherichia coli* by PCR. *Bangladesh J. Vet. Med.*, 9: 17-25.

Vandekerchove, D., P. De Herdt, H. Laevens and F. Pasmans, 2004. Colibacillosis in caged layer hens: Characteristics of the disease and the aetiological agent. *Avian Pathol.*, 33: 117-125.

Yousseff, F.M., M.A. Ahmed and D.H. Mansour, 2008. Clinical, pathological and bacteriological investigations on air sacculitis in chickens in Ismailia province (Egypt). *J. Agric. Vet. Sci.*, 1: 71-79.