

Two and Three-Dimensional Computed Tomographic Anatomy of the Guttural Pouch in Arabian Foals

Sadullah Bahar and Mustafa Orhun Dayan

Department of Anatomy, Faculty of Veterinary Medicine, Selcuk University, Konya, Turkey

Abstract: The guttural pouches have an elusive anatomy due to their location, adjacency and variable shape. Computed Tomography (CT) is utilized in visualizing the details of complex body parts and their in creating 3-Dimensional (3D) Models. In the present study was aimed to demonstrate sectional reference anatomical details of the pouches and to obtain their certain morphometric features. Heads of 5 purebred female Arabian foals were scanned by helical CT. CT was quite successful in demonstrating the borders of the guttural pouches and the surrounding bone and muscular tissues. The guttural pouches volume was 82.1 ± 7.69 mL whereas volume ratios of the lateral and medial compartments were 16 and 84%. Pouches were observed as the largest air cavity of the head's total air space. 3D Models may provide substantial advantages in determining topographic, morphologic, morphometric features of the guttural pouches and in pre-surgical planning for this region.

Key words: Computed tomography, horse, guttural pouche, 3D Models, morphometry

INTRODUCTION

The guttural pouches are a pair of air-filled sacs that are formed by the expansion of the auditory tube mucosa ventrally at the level of supporting cartilage in horses and donkeys which are among domestic mammalians (Sisson, 1975; Alsafy *et al.*, 2008; Dyce *et al.*, 2009; Oto and Haziroglu, 2011).

The pouches extendparamedian from the pharyngeal recess to the atlanto-occipital joint through the dorsal side of the esophagus in the skull base (Hardy and Leveille, 2003; Dyce *et al.*, 2009; Konig *et al.*, 2010a, b). The pouches are separated by the caudal aspect of the stylohyoid bone into two compartments, small in the lateral and large in the medial which are in connection with each other. While medial compartments are separated from each other by rectus capitisventralis and rectus capitislongus muscles in the caudal portion they are in contact with each other in the rostral portion (Sisson, 1975; Dyce *et al.*, 2009; Konig *et al.*, 2010a, b). Approximate wall thickness of the guttural pouches is 0.5 μ m and the mucosa is covered by ciliated epithelium containing goblet cells. They are in contact with a number of regional muscles and some joints and bones including mainly the cranial nerves IX, X, XI and XII, cranial cervical ganglion, cervical sympathetic trunk, internal and external carotid arteries. Most of these anatomical structures can be observed under the mucosa via endoscopic examinations performed in healthy animals. The most

common diseases of the guttural pouches include mycosis, empyema and tympany (Sisson, 1975; Carmalt, 2002; Hardy and Leveille, 2003; Dyce *et al.*, 2009; Konig *et al.*, 2010a, b; Borges and Watanabe, 2011).

The volume of each pouch in mature horses was reported to be approximately from 300-600 mL (Sisson, 1975; Manglai *et al.*, 2000; Carmalt, 2002; Koning *et al.*, 2010b) whereas this volume was reported 145 mL for foals (Manglai *et al.*, 2000). Babptiste *et al.* (1996) and Manglai *et al.* (2000) have stated that the shape and size of the compartments vary based on age of the animal, position of the head and contraction of surrounding muscles.

In previous studies performed using medical scanning methods such as computed tomography (Sasaki *et al.*, 1999; Smallwood *et al.*, 2002; Solano and Brawer, 2004; Alsafy *et al.*, 2008) and Magnetic Resonance Imaging (MRI) (Chaffin *et al.*, 1997; Oto and Haziroglu, 2011). The guttural pouches and related anatomical structures were demonstrated in detail. However in these studies, evaluations were mainly based on the transverse images whereas dorsal and sagittal plane images were involved limitedly.

Serial CT images are frequently used to create 3-Dimensional (3D) digital models of the skull and the nasal and paranasal cavities (Witmer and Ridgely, 2008; Pirner *et al.*, 2009; Farke, 2010; Sahlstrand-Johnson *et al.*, 2011). These models are used to view the anatomic structures of interest through

different angles (Witmer and Ridgely, 2008) to plan surgeries (Yavuz *et al.*, 2009; Poeschl *et al.*, 2013) and to obtain many morphometric data related to these anatomical configurations (Witmer and Ridgely, 2008; Pirner *et al.*, 2009; Farke, 2010; Sahlstrand-Johnson *et al.*, 2011).

The aim of the present was to demonstrate anatomical details of the guttural pouches and related configurations in the transverse, dorsal and sagittal planes on CT images to create 3D digital models of mainly the guttural pouches and soft and bony tissues of the head using CT images to assess the morphological and topographical relationships between these structures and the pouches and to obtain certain morphometric data of the pouches in Arabian foals.

MATERIALS AND METHODS

The present study included 5 purebred female Arabian foals at the age of 8-12 weeks. Following euthanasia, the heads of the foals were separated from the body by atlanto-axial dearticulation. The study protocol was approved by the Ethical Committee of Selcuk University Faculty of Veterinary Medicine.

Computed tomography scanning: Computed tomography imaging was performed at the Radiology Department of Medical Faculty of Selcuk University. The heads were placed in the rostro-caudal position in the way that the ventral margin of the mandible could completely be in contact with the CT table. Transverse images were obtained using a Helical CT scanner (Aquilon 4, Toshiba, Tokyo, Japan). The main setting parameters were designed as follows: power settings: 125 kV and 175 mAs; slice size: 512×512 pixels (0.811 mm/pixel); slice thickness: 1 mm. Serial transverse images were recorded in DICOM format and dorsal and sagittal plane images which were obtained by reformatting the transverse images were recorded in CINE format, the images were separately recorded in CD-ROMs. The guttural pouches and related anatomical structures were visualized using Hipax Diagnostic Workstation and were named. In the present study, naming of the anatomic structures of the guttural pouch region was performed by the use of equine anatomy texts (Sisson, 1975; Nickel *et al.*, 1979; Schaller, 1992; Barone, 1999) papers (Arencibia *et al.*, 2000; Morrow *et al.*, 2000; Smallwood *et al.*, 2002; Solano and Brawer, 2004; Koning *et al.*, 2010a) and Nomina Anatomica Veterinaria (Frewin and Habel, 2012).

Segmentation and 3-dimensional modeling: The 3-dimensional reconstructions of the guttural pouch, hyoid bone, mandible and the skull were performed by the use of MIMICS program (Materialise's Interactive Medical Image Control System, Ver. 12.01, Materialise, Belgium).

The serial CT images of the head in DICOM format were imported into Mimics Software. Firstly, the CT images were segmented using segmentation tools (threshold, region growing, edit mask, etc.) to extract different tissues (Bahar *et al.*, 2014). Bony tissues, soft tissue and air spaces (guttural pouches, nasal and paranasal cavities) were isolated by setting gray level threshold 226-1000HU, 225 -849 and -850HU to -1024HU, respectively. Following these procedures, related structures were separately modeled using 3D calculate command of the program. Using these models, the topographic relationships of the guttural pouches with the skull and hyoid bone was investigated primarily (Bahar *et al.*, 2014). Subsequently, the lateral and medial compartments of the guttural pouches were manually separated from each other and 3D Model of the compartments each of which was masked in different colors was created and volume and surface area of the compartments were measured. Finally, the volumes of bony and soft tissues of the head as well as air spaces other than guttural pouches were measured.

Statistical analysis: Morphometric data regarding the volumes and surface areas of the right and left guttural pouches were evaluated by two-sample t-test whereas the relation between the right and left pouches was evaluated by Pearson's correlation test. Data were analyzed using the Predictive Analytics Soft Ware (PASW) Statistics 19.0 (SPSS, Inc., Chicago, IL, USA). A $p < 0.05$ was considered statistically significant.

RESULTS

The present study revealed that CT was quite successful in visualizing the borders of the guttural pouches and the surrounding bony and muscular tissues whereas it was partially successful in visualizing the arteries and veins and insufficient in visualizing the nerves of this region. It was determined that the guttural pouches in foals are located asparamedian between the transverse planes passing from the caudal border of the crista vomeris in the rostral portion and from the caudal border of the jugular process in the caudal portion (Fig. 1-3). The guttural pouches were observed to be separated into two compartments, small in the lateral and large in the medial by the invagination of the caudal half of stylohyoideum into the pouch through the caudoventral direction (Fig. 1-3). The medial compartment was detected to be adjacent to the base of the skull, ventral petrosal sinus and internal carotid artery at the dorsal side to the pharynx in the ventrorostralside and to the beginning of the esophagus in the ventral side (Fig. 1-3). It was identified that medial walls of the right and left medial compartments formed a septum by

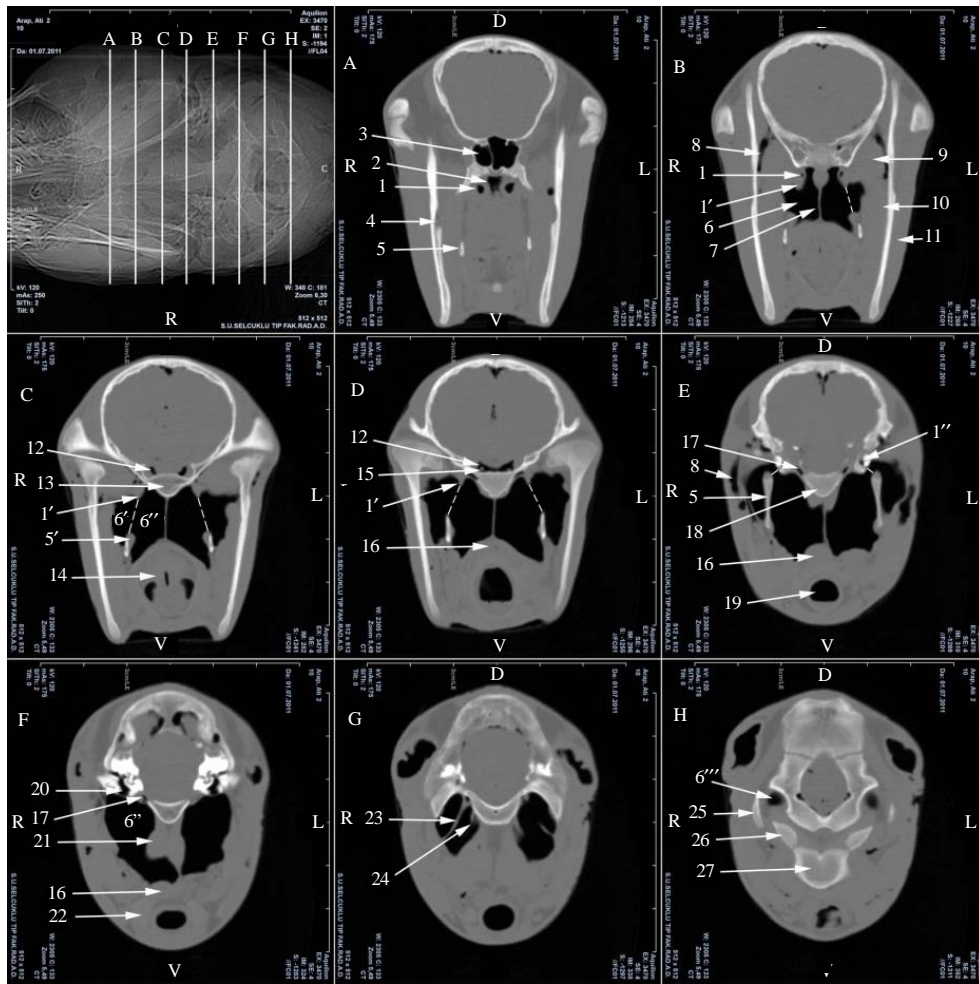


Fig. 1: Transversal CT images of guttural pouch region (No. 2, 10 weeks), 1-Auditory tube; 1': Cartilage part of auditory tube; 1'': Bone part of auditory tube; 2: Nasopharynx; 3: Sphenoidal part of sphenopalatine sinus; 4: Mandibular foramen; 5: Stylohyoid bone; 5': Caudal stylopharyngeal muscle; 6: Guttural pouch; 6': Lateral compartment of guttural pouch; 6'': Medial compartment of guttural pouch; 6''': Caudal end of medial compartment of guttural pouch; 7: Septum between right and left guttural pouches; 8: Maxillar vein; 9: Lateral pterygoid muscle; 10: Medial pterygoid muscle; 11: Masseter muscle; 12: Cavernous sinus; 13: Basisphenoid bone; 14: Larynx; 15: Internal carotid artery; 16: Esophagus; 17: Jugular foramen and ventral petrosal sinus; 18: Basilar part of occipital bone; 19: Tracheal cavity; 20: Cavity of middle ear; 21: Longus capitis muscle; 22: Thyroid gland; 23: Neural fold (glossopharyngeal and hypoglossal nerves); 24: Neurovascular fold (vagus, accessory and sympathetic nerves, cranial cervical ganglion, internal carotid artery); 25: Paracondylar process; 26: Occipital condyle; 27: Ventral arch of atlas; Dotted line-Border between lateral and medial compartments

contacting with each other in the rostral portion and that the compartments were separated from each other in the caudomedial portion due to longus capitis and ventral rectus capitis muscles passing between the two pouches (Fig. 1-3). The medial compartment was observed to form a blind pouch located in the ventral condylar fossa in the caudal portion (Fig. 1). The lateral compartments were observed to be adjacent to the tensor and levator veli palatini muscles, lateral and medial pterygoid muscles in

the rostral, rostro dorsal and rostro lateral portions to the medial pterygoid muscles, superficial temporal vein and external carotid artery as well as the main branches arising from these arteries in the lateral portion and to the petrosal bone and temporohyoid joint in the caudodorsal portion (Fig. 1).

The guttural pouches, skull, mandible and hyoid bone were successfully modeled using the 3D modeling program (Fig. 4 and 5). In these models, the rostral border

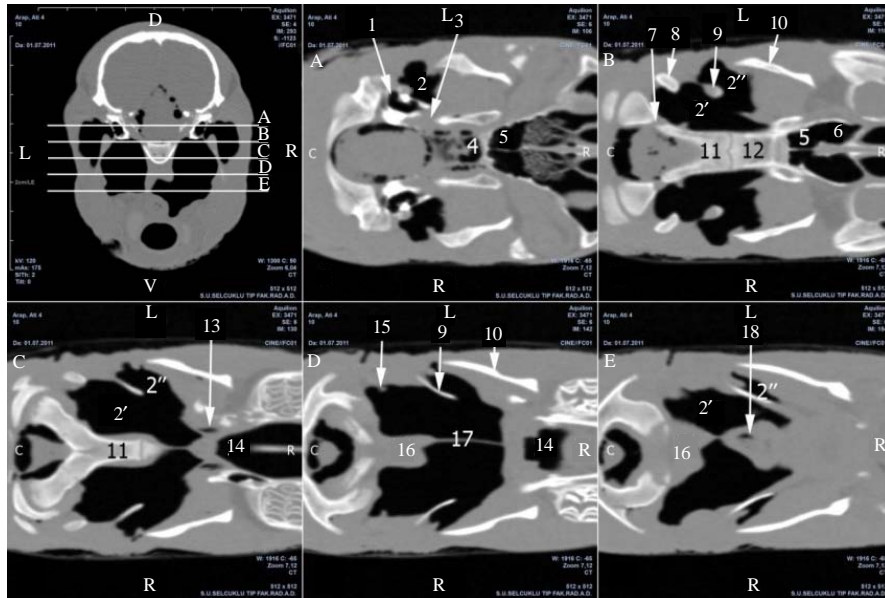


Fig. 2: Reformatted dorsal plane images of guttural pouch region (No. 4, 12 weeks); 1: Cavity of middle ear; 2: Guttural pouch; 2'-medial compartment its 2; 2'': Lateral compartment its 2; 3: Jugular foramen; 4: Cavernous sinus; 5: Sphenoidal part of sphenopalatine sinus; 6: Palatine part of sphenopalatine sinus; 7: Hypoglossal canal; 8: Paracondylar process; 9: Stylohyoid bone; 10: Mandible; 11: Basilar part of occipital bone; 12: Basisphenoid bone; 13: Auditory tube; 14: Nasopharynx; 15: Neurovascular fold; 16: Longus capitis and ventral rectus capitis muscles; 17: Septum between right and left guttural pouches; 18: Esophagus

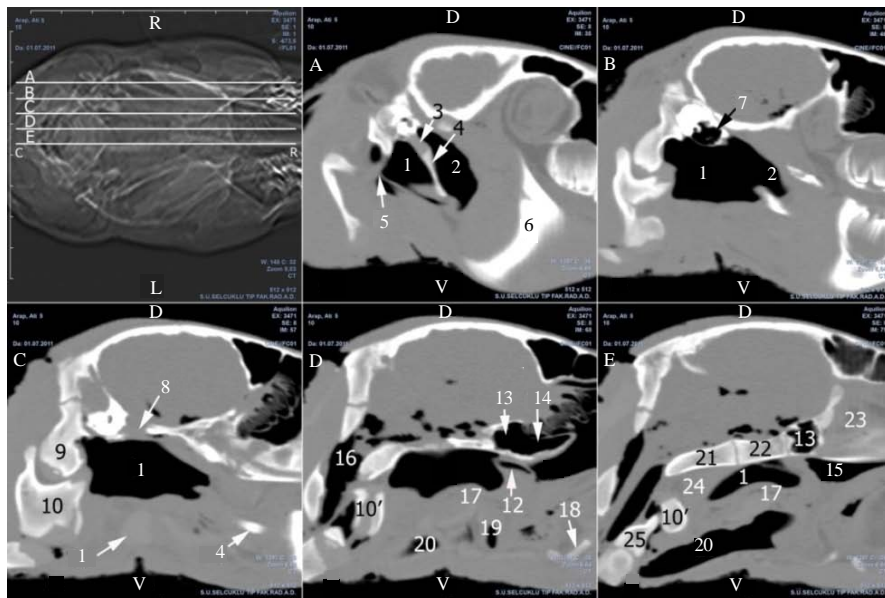


Fig. 3: Reformatted sagittal plane images of right guttural pouch region (No. 5, 12 weeks), 1: Medial compartment of guttural pouch; 2: Lateral compartment of guttural pouch; 3: Tympanohyoid bone; 4: Stylohyoid bone; 5: Neurovascular fold; 6: Mandible; 7: Cavity of middle ear; 8: Jugular foramen; 9: Occipital condyle; 10: Atlas; 10'-Ventral arch of atlas; 11: Thyroid gland; 12: Auditory tube; 13: Sphenoidal part of sphenopalatine sinus; 14: Palatine part of sphenopalatine sinus; 15: Nasopharynx; 16: Foramen magnum; 17: Esophagus; 18: Ceratohyoid bone; 19: Larynx; 20: Tracheal cavity; 21: Basilar part of occipital bone; 22: Basisphenoid bone; 23: Cartilage of nasal septum; 24: Longus capitis and ventral rectus capitis muscles; 25: Dens of axis

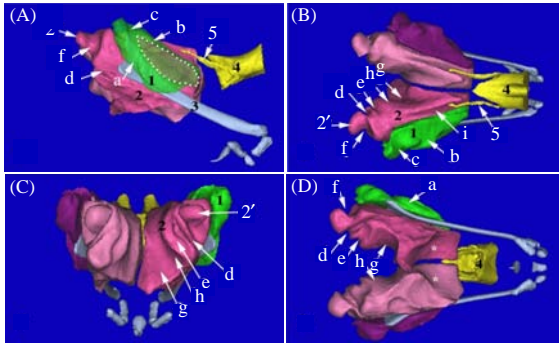


Fig. 4: Visualization depression on the 3D Models of guttural pouch compartments (No. 5, 12 weeks): A) Lateral (right) view; B) Dorsal views; C) Caudal view; D) Ventral view; 1: Right lateral compartment; 2: Right medial compartment; 2': Caudal diverticula of medial compartment; 3: Stylohyoid bone; 4: Nasopharyngeal cavity; 5: Auditory tube; a: Depression of external carotid artery; b: Depression of maxillar artery; c: Depression of caudal auricular artery; d: Neural sulcus; e-Neurovascular sulcus; f: Depression of paracondylar proccess; g: Depressions of longuscapitis muscle; h: Depression of ventral capitis rectus muscle; i: Depression of tubal cartilage; *Depression of dorsal wall of pharynx and entrance of esophagus; White dotted line area-passage between right lateral and medial compartments

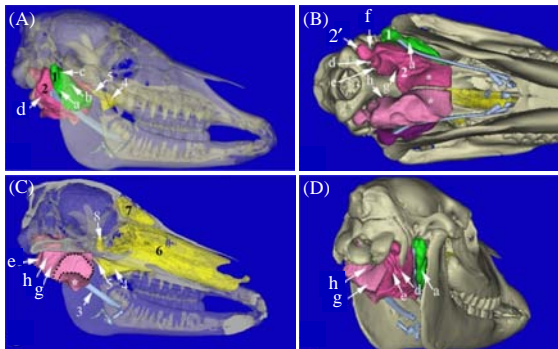


Fig. 5: 3D Models of the skull (transparent) nasal and paranasal cavity (semitransparent) and compartments of guttural pouches (different colors and opaque) (No. 5, 12 weeks): a) Right lateral view; b) Ventral view; c) Left medial view; d) Right caudolateral view; 6: Left nasal cavity; 7: Left frontal sinus; 8: Sphenoidal part of left sphenopalatine sinus; Black dotted line area-septal wall of the left medial compartment; Legend to Fig. 4 for other details

of the guttural pouches were determined to be formed by the angle resulting from the union of zygomatic processes of the frontal and temporal bones and the caudal border was formed by the transverse plane perpendicularly intersecting the plane passing from the caudal portion of the paracondylar process and the ventral margin of the mandible (Fig. 5). It was found that the pouches were bordered ventrally by a plane parallel to the plane passing from the ventral margin of the mandibular foramen and ventral part of the mandible whereas they were bordered laterally by the ramus mandible (Fig. 5). In the lateral wall of the lateral compartment which is formed by the invagination of stylohyoid muscle into the pouch through the caudoventral direction, a Y-shaped deep sulcus containing external carotid artery and maxillary vein as well as the main branches arising from this vessel (maxillary and caudal auricular arteries, caudal auricular and superficial temporal vein) was determined (Fig. 4 and 5). Furthermore, a sulcus belonging to the medial pterygoid muscle and contacting the pouch was detected in the rostralateral portion of this compartment. The rostral portion of the medial compartment showed impressions of the caudodorsal wall of the pharynx, the rostroventral portion showed impressions of the proximal part of the esophagus and the ventromedial aspect showed impressions of the longus capitis and ventral rectus muscles (Fig. 4 and 5). Neurovascular sulcus which was formed by the cranial nerves IX, X and XI together with the internal carotid artery was found in the caudomedial portion of the medial compartment and neural sulcus (beginning from the dorsal part and extending ventrolaterally) which was formed by hypoglossal nerve and lingual branch of the glossopharyngeal nerve was detected in the caudal portion (Fig. 4 and 5). Moreover, this compartment was observed to have a diverticulum located in the ventral condyloid fossa in the caudal part (Fig. 4 and 5).

The volumes of the right and left compartment which were derived from digital models of the guttural pouches that were prepared using 3D modeling program are demonstrated in Table 1. Mucosa surface area and passage area between the lateral and medial compartments are summarized in Table 2. No significant difference was found between the right and left compartments in terms of these morphometric data. Volumes and volume ratios of air spaces of the head (nasal cavity, paranasal sinus and guttural pouch) and bony and soft tissues in the foals are presented in Table 3. Whilst the ratio of volume of guttural pouch to the overall head volume was 3.6% (Table 3) it was the largest cavity accounting for 45.9% of total air space.

Table 1: Volumes of the right and left guttural pouches in Arabian foals

Compartments	Volume (mL)		Total volume (mL) Mean±SE
	Mean±SE (CV)	Ratio (%)	
Right lateral	16.6±1.9 (20)	17	80.2±7.33
Right medial	63.5±5.9 (21)	83	-
Left lateral	18.9±2.2 (26)	15	84.0±8.04
Left medial	65.1±6.0 (26)	85	

Table 2: Mucosa surface area and the passage area between the compartments of the right and left guttural pouches in Arabian foals

Parameters	Mucosal surface		Passage between the compartments	
	Right	Left	Right	Left
	(n = 5)	(n = 5)	(n = 5)	(n = 5)
Area (Mean±SEM) (cm ²)	151.1±10.1	162.4±8.9	7.13±0.82	7.12±0.84
CV	0.15	0.12	0.19	0.27

SEM: Standard Error Mean; CV: Coefficient of Variance

Table 3: Volumes and volume ratios of air spaces, bony and soft tissues of the Arabian foal heads

Head cavities and tissues	Volume (mL)	
	(Mean±SE)	Ratio(%)
Nasal cavities	48±16.0	1.0
Paranasal sinuses	146±15.8	3.2
Guttural pouches	164±14.5	3.6
Bony tissues	903±20	19.7
Soft tissues	3333±229	72.6
Total	4593±301	100.0

DISCUSSION

Owing to its perfect resolution and differentiating the tissues well, CT is frequently used in horses both to determine the anatomic details of the head region (Arencibia *et al.*, 2000; Morrow *et al.*, 2000; Smallwood *et al.*, 2002; Solano and Brawer, 2004; De Zani *et al.*, 2010) and to detect pathological conditions formed in this region (Lacombe *et al.*, 2010; Kowalczyk *et al.*, 2011). In the previous anatomical studies performed on head using CT in which mainly transverse images were used, guttural pouches were involved limitedly (Sasaki *et al.*, 1999; Arcencibia *et al.*, 2000; Morrow *et al.*, 2000; Smallwood *et al.*, 2002; Solano and Brawer, 2004; De Zani *et al.*, 2010). In the present study which was performed on the heads of healthy Arabian foals, anatomic details of guttural pouches were demonstrated not only in transverse plane images (Fig. 1) but also in dorsal (Fig. 2) and sagittal (Fig. 3) plane images. It was observed that the right and left guttural pouches were located symmetrically in these animals (Fig. 1 and 2).

It is difficult to define the guttural pouches in anatomical terms. Previous studies have reported that the shape and size of compartments vary depending on age of the animal and position of the head (Babptiste *et al.*, 1996; Manglai *et al.*, 2000). The initial detailed models of guttural pouches in horses were prepared by Babptiste *et al.* (1996) using silicone injection method. In another study that used the same method (Manglai *et al.*,

2000) volumes of the pouches were derived from silicone models using Archimedes Method in mature horses and foals. In addition these two studies (Babptiste *et al.*, 1996; Manglai *et al.*, 2000) defined impressions made by certain anatomical structures that were in contact with the pouches on the models. In another study, the guttural pouches and the skull were modeled in an Arabian foal using CT images for the first time (Borges and Watanabe, 2011). However in that particular study, impressions of the surrounding tissues on the models were not named. In the present study, sulci formed by the soft tissues including nerves, vessels and muscles were named in detail for the first time on 3D Models (Fig. 4 and 5). Moreover, topographic relationship of the pouches with the skull, mandible and hyoid bone was demonstrated (Fig. 4 and 5). Impressions of the anatomic structures which were in contact with the guttural pouches on the models were closely similar to but clearer than that reported using silicone models (Babptiste *et al.*, 1996; Manglai *et al.*, 2000).

Konig *et al.* (2010a) performed a cadaver study and defined two mucosal depressions in the caudal aspect of the medial compartment, one of which was the neurovascular fold containing the glossopharyngeal nerve, the vagal nerve, the sympathetic trunk with the cranial cervical ganglion and the internal carotid artery and the other was the neural fold comprising the accessory nerve and the hypoglossal nerve. On 3D models these two mucosal folds were named as neurovascular sulcus and neural sulcus, respectively (Fig. 4 and 5).

Babptiste *et al.* (1996) reported that the volumes of lateral and medial compartments vary depending on whether the head of the horse was in extension or in flexion position. However, the extent of this change has not been morphometrically expressed. Volumetric changes in the pouches can be identified with 3D Models which would be prepared using CT images obtained at different positions of the head in living horses.

The volume of guttural pouch in horses was reported to be approximately 300 mL by Sisson (1975), 300-500 mL by Dyce *et al.* (2009), 600 mL by Carnalt (2002) and 500 mL by Konig *et al.* (2010b). Manglai *et al.* (2000) reported the volume of guttural pouch to be 472±12.4 mL in mature horses and 145±9.4 mL in foals (n = 3, 4-5 months of age). In the present study, the volumes of the right and left guttural pouches in Arabian foals (3-4 months of age) was determined to be 80.2±7.33 and 84.0±8.04 mL, respectively and the total volume was found to be 164±14.5 mL. Moreover, the surface areas of the pouches as well as the passage area between the right and left compartments were measured for the first time in

the present study. Sisson (1975) and Carmalt (2002) reported the volume ratio of the lateral and medial compartments to be 1/3 (33.3%) and 2/3 (66.6%), respectively in mature horses. In the present study, the mean volume ratio of the lateral and medial compartments in Arabian foals was found to be 16 and 84%, respectively. It was concluded that the difference between the volume ratios reported in the literature (Sisson, 1975; Carmalt, 2002) and those obtained in the present study might have resulted from the differences in the race, age and gender of the animals used in the studies as well as the methodological differences. One of the most important diseases of the guttural pouches encountered in foals at the age of 0-1 year is the tympany which is developed due to the enlargement of the medial compartment and has an unknown etiology (Hardy and Leveille, 2003; Edwards and Greet, 2007). Tympany has been reported to be more prevalent in Arabian foals, particularly in female foals as compared to the other races (Blazyczek *et al.*, 2004; Zeitz *et al.*, 2009). The volume of the medial compartment measured in the present study was observed to be substantially higher than that reported in the literature (Sisson, 1975; Carmalt, 2002). This might be an answer in terms of morphometric approach to the question why this disease is more prevalent in Arabian foals.

CONCLUSION

Unlike nasal and paranasal cavities, it is difficult to define the anatomical structure of the guttural pouches due to its large volume, location being surrounded by soft tissues containing important vasculature and nerves and variable shape. Multiplane CT images and 3D Digital Models prepared using these images may allow detection of normal topographic, morphologic and morphometric characteristics of this structure and related pathologic conditions and may provide important advantages in planning the surgeries of this region.

REFERENCES

Alsafy, M.A.M., M.H. El-Kammar and S.A.A. El-Gendy, 2008. Topographical anatomy, computed tomography and surgical approach of the guttural pouches of the donkey. *J. Equine Vet. Sci.*, 28: 215-222.

Arencibia, A., J.M. Vazquez, M. Rivero, R. Latorre, J.A. Sandoval, J.M. Vilar and J.A. Ramirez, 2000. Computed tomography of normal cranioencephalic structures in two horses. *Anat. Histol. Embryol.*, 29: 295-299.

Babptiste, K.E., S.D. Holladay and L.E. Freeman, 1996. Alterations in equine guttural pouch morphology with head position: Observations using a new technique for producing accurate casts. *Anat. Rec.*, 246: 579-584.

Bahar, S., D. Bolat, M.O. Dayan and Y. Paksoy, 2014. Two- and three-dimensional anatomy of paranasal sinuses in Arabian foals. *J. Vet. Med. Sci.*, 76: 37-44.

Barone, R., 1999. *Anatomie Comparee des Mammiferes Domestiques*. Vigot Preres, Paris.

Blazyczek, I., H. Hamann, B. Ohnesorge, E. Deegen and O. Distl, 2004. Inheritance of guttural pouch tympany in the Arabian horse. *J. Hered.*, 95: 195-199.

Borges, A.S. and M.J. Watanabe, 2011. Guttural pouch diseases causing neurologic dysfunction in the horse. *Vet. Clin. North Am. Equine Pract.*, 27: 545-572.

Carmalt, J., 2002. Guttural pouch diseases in the horse. *Large Anim. Vet. Rounds*, 2: 1-6.

Chaffin, M.K., M.A. Walker, N.H. McArthur, E.E. Perris and N.S. Matthews, 1997. Magnetic resonance imaging of the brain of normal neonatal foals. *Vet. Radiol. Ultrasound*, 38: 102-111.

De Zani, D., S. Borgonovo, M. Biggi, S. Vignati and M. Scandella *et al.*, 2010. Topographic comparative study of paranasal sinuses in adult horses by computed tomography, sinuscopy and sectional anatomy. *Vet. Res. Commun.*, 34: 13-16.

Dyce, K.M., W.O. Sack and C.J.G. Wensing, 2009. *Textbook of Veterinary Anatomy*. 4th Edn., Saunders Elsevier, Missouri, USA., pp: 522-525.

Edwards, G.B. and T. Greet, 2007. Disorders of the Guttural Pouches (Auditory Tube Diverticuli). In: *Equine Respiratory Medicine and Surgery*, McGorum, B.C., P.M. Dixon, N.E. Robinson and J. Schumacher (Eds.). Elsevier, New York, USA., pp: 419-436.

Farke, A.A., 2010. Evolution and functional morphology of the frontal sinuses in Bovidae (Mammalia: Artiodactyla) and implications for the evolution of cranial pneumaticity. *Zool. J. Linn. Soc. Lond.*, 159: 988-1014.

Frewein, J. and R.E. Habel, 2012. *Nomina Anatomica Veterinaria*. 5th Edn., World Association of Veterinary Anatomists, Hannover, Germany.

Hardy, J. and R. Leveille, 2003. Diseases of the guttural pouches. *Vet. Clin. North Am. Equine Pract.*, 19: 123-158.

Konig, H.E., K.D. Budras, J. Seeger, M. Fersterra and M.C. Sora, 2010a. Anatomic and histological investigations of the equine guttural pouches (Diverticulum tubae auditivae)-clinical advisements. *Agro-Ciencia*, 26: 90-98.

- Konig, H.E., K.D. Budras, J. Seeger and M.C. Sora, 2010b. About the clinical anatomy of the guttural pouch (diverticulum tubae auditivae) in the horse. *Pferdeheilkunde*, 26: 152-156.
- Kowalczyk, L., A. Boehler, R. Brunthaler, M. Rathmanner and A.B.M. Rijkenhuizen, 2011. Squamous cell carcinoma of the paranasal sinuses in two horses. *Equine Vet. Educ.*, 23: 435-440.
- Lacombe, V.A., C. Sogaro-Robinson and S.M. Reed, 2010. Diagnostic utility of computed tomography imaging in equine intracranial conditions. *Equine Vet. J.*, 42: 393-399.
- Manglai, D., R. Wada, H. Endo, M. Kurohmaru and T. Yoshihara *et al.*, 2000. Macroscopic anatomy of the auditory tube diverticulum (Guttural pouch) in the thoroughbred equine silicon mold approach. *Okajimas Folia Anat. Jpn.*, 76: 335-346.
- Morrow, K.L., R.D. Park, T.L. Spurgeon, T.S. Stashak and B. Arceneaux, 2000. Computed tomographic imaging of the equine head. *Vet. Radiol. Ultrasound*, 41: 491-497.
- Nickel, R., A. Schummer, E. Seiferle and W.O. Sack, 1979. *The Viscera of the Domestic Mammals*. 2nd Edn., Springer-Verlag, New York, ISBN-13: 9781475768145, pp: 226-227.
- Oto, C. and R.M. Hazirolu, 2011. Magnetic resonance imaging of the guttural pouch (*diverticulum tubae auditivae*) and its related structures in donkey (*Equus asinus*). *Ankara Univ. Vet. Fak. Derg.*, 58: 1-4.
- Pirner, S., K. Tingelhoff, I. Wagner, R. Westphal and M. Rilk *et al.*, 2009. CT-based manual segmentation and evaluation of paranasal sinuses. *Eur. Arch. Oto-Rhino-Laryngol.*, 266: 507-518.
- Poeschl, P.W., N. Schmidt, G. Guevara-Rojas, R. Seemann, R. Ewers, H.T. Zipko and K. Schicho, 2013. Comparison of cone-beam and conventional multislice computed tomography for image-guided dental implant planning. *Clin. Oral Invest.*, 17: 317-324.
- Sahlstrand-Johnson, P., M. Jannert, A. Strombeck and K. Abul-Kasim, 2011. Computed tomography measurements of different dimensions of maxillary and frontal sinuses. *BMC Med. Imag.*, Vol. 11. 10.1186/1471-2342-11-8.
- Sasaki, M., Y. Hayashi, H. Koie, Y. Yamaya and J. Kimura *et al.*, 1999. CT examination of the guttural pouch (Auditory tube diverticulum) in Prezewalski's horse (*Equus przewalski*). *J. Vet. Med. Sci.*, 61: 1019-1022.
- Schaller, O., 1992. *Illustrated Veterinary Anatomical Nomenclature Latin-English. French & European Publications*, German, ISBN: 9780785989042, Pages: 614.
- Sisson, S., 1975. The Ear. In: *Sisson and Grossman's The Anatomy of the Domestic Animals*, Getty, R. (Ed.). W.B. Saunders Co., Philadelphia, USA., pp: 719-727.
- Smallwood, J.E., B.C. Wood, W.E. Taylor and L.P. Jr. Tate, 2002. Anatomic reference for computed tomography of the head of the foal. *Vet. Radiol. Ultrasound*, 43: 99-117.
- Solano, M. and R.S. Brawer, 2004. CT of the equine head: Technical considerations, anatomical guide and selected diseases. *Clin. Tech. Equine Pract.*, 3: 374-388.
- Witmer, L.M. and R.C. Ridgely, 2008. The paranasal air sinuses of predatory and armored dinosaurs (Archosauria: Theropoda and Ankylosauria) and their contribution to cephalic structure. *Anat. Rec.*, 291: 1362-1388.
- Yavuz, M.S., M.C. Buyukkurt, S. Tozoglu, I.M. Dagsuyu and M. Kantarci, 2009. Evaluation of volumetry and density of mandibular symphysis bone grafts by three-dimensional computed tomography. *Dent. Traumatol.*, 25: 475-479.
- Zeitz, A., A. Spotter, I. Blazyczek, U. Diesterbeck, B. Ohnesorge, E. Deegen and O. Distl, 2009. Whole-genome scan for guttural pouch tympany in Arabian and German warmblood horses. *Anim. Genet.*, 40: 917-924.