

Case of Applying Allogenic Mesenchymal Stem Cells of Adipogenic Origin in Veterinary Dentistry

Elena Yu. Zakirova, Dina A. Azizova, Albert A. Rizvanov and Rais G. Khafizov
Kazan (Volga Region) Federal University, Kremlevskaya Str. 18, 420000 Kazan, Russia

Abstract: After drawing a permanent tooth (canine tooth) in a dog because of complicated caries, an oroantral fistula was formed in the upper jaw right. Multiple surgeries gave no results and there was a relapse of fistulous tract along the mucogingival junction in the upper jaw right. We performed an operation for guided tissue regeneration in the area of oroantral fistula with simultaneous plastics of soft tissue. We used osteoinductive material was used as allogeneic mesenchymal stem cells in combination with nickelide titanium granules (nitigran). Adipogenic stem cells were isolated from subcutaneous adipose tissue of an adult female dog. The difficulty in using a suspension of mesenchymal stem cells *in vivo* lies in its spreading into the surrounding tissue in the absence of any carrier material. The three-dimensional porous-permeable nickelide titanium incubators that we use have unique features such as porous-permeable structure with widely open pores, excellent wettability with body fluids, a high biological, biochemical and biomechanical compatibility at the cellular level. We prepared the cellular therapeutic preparation immediately prior to transplantation. We used nickelide titanium granules as a matrix for the local retention of cells. The result of the conducted surgery was a complete closure of oroantral fistula in a dog.

Key words: Mesenchyme stem cells, veterinary medicine, nickelide titanium granules, oroantral fistula, compatibility

INTRODUCTION

The use of stem cells in dentistry offers opportunities for using cellular technologies in maxillo-facial surgery, periodontics and implantology (Grudianov *et al.*, 2012). There are many methods of plasty of bone defects of the alveolar ridge, however, the materials applied do not always match the requirements set therefor (Khafizov *et al.*, 2012a). The difficulty in using a suspension of Mesenchymal Stem Cells (MSC) *in vivo* lies in its spreading into the surrounding tissue in the absence of any carrier incubator. The three-dimensional porous-permeable nickelide titanium incubators created in Scientific-Research Institute for Medical Materials and Implants with Shape Memory (Tomsk) that we use have unique features such as porous-permeable structure with widely open pores, excellent wettability with body fluids, a high biological, biochemical and biomechanical compatibility at the cellular level (Khafizov *et al.*, 2012b).

In this case we used a biocompatible fine-grained porous nickelide titanium alloy with a pore size of 0.1-1000 μm , obtained by self-propagating high-temperature synthesis, as a cell carrier-provider. The structure of the incubator made of a porous permeable

nickelide titanium alloy represents a three-dimensional pore space which morphological structure is typical of the highly porous materials. The porous material has a large specific surface due to open and interconnected pores therein. Pore walls have a highly developed, relief and rough-microporous surface (Anonymous, 2011). The method of bone regeneration based on unique titanium granules with porous structure allows us to save and regenerate bone tissue. The granules stick together under the capillary action when coming in contact with patient's blood or oral fluid. Titanium surface features a high thrombogenic effect which contributes to the formation of a stable blood clot around the granules. An optimum porous effect in combination with a maximized surface structure corresponds maximally to the characteristics of human bone and thereby creates natural conditions for healthy and fast growth of bone tissue. There is also an improvement of osseointegration due to the colonization of bone-forming cells. The granules provide fast mechanical stability and do not dissolve.

Thus, the porous permeable nickelide titanium incubator is a unique biocompatible carrier for cell cultures of body tissues and can be used for creating artificial tissue-engineering structures (Anonymous, 2014).

Objective of our study is to prove experimentally, the feasibility and effectiveness of using the allogenic MSCs from adipose tissue in surgical dentistry and maxillofacial surgery for closing oroantral fistula in dogs.

MATERIALS AND METHODS

The ethical standards of experiments must be in accordance with the guidelines provided by the CPCSEA and World Medical Association Declaration of Helsinki on Ethical Principles for Medical Research Involving Humans for studies involving experimental animals. Adult female dog, a German Shepherd breed, 3 years old. About 1.5 years ago, after drawing a permanent tooth (canine tooth) in a dog because of complicated caries, an oroantral fistula was formed in the upper jaw right. There were complaints of food entering the nasal cavity and a putrefactive odor. After a course of anti-inflammatory therapy (lavage of the sinus through the fistulous tract with antiseptics, lincomycin, ceftriaxone and gentamicin therapy) we repeatedly performed fistula plasty with soft tissues.

However, multiple surgeries gave no results and there was a relapse of fistulous tract about 1 cm long and 0.2 cm wide along the mucogingival junction in the upper jaw right (Fig. 1).

We suggested to perform an operation for guided tissue regeneration in the area of oroantral fistula with simultaneous plastics of soft tissue. We used osteoinductive material was used as allogenic mesenchymal stem cells in combination with nickellide titanium granules (nitigran).

We obtained allogenic mesenchymal cells of adipogenic origin mature female Chow-Chow dog by using a previously described technique (Katina *et al.*, 2012). We performed daily *in vivo* monitoring of cell culture using an inverted microscope AxioObserver Z1 (Carl Zeiss, Germany) through light microscopy.

To investigate the ability of MSCs to differentiate osteogenically and chondrogenically, we incubated the obtained cell cultures in special media (Katina *et al.*, 2012).

To determine the fact of the differentiation, the cell cultures with a specific culture medium were fixed and stained on day 21 of incubation. To determine the mineralization, which is a sign of osteogenic differentiation, we used the Von Kossa reaction. To determine the chondrogenic differentiation, we performed staining with Alcian Blue for acid mucopolysaccharides, which are a chondritis marker.

We prepared the cellular therapeutic preparation immediately prior to transplantation. For this purpose, we used allogenic MSCs of the 4th passage. We used nickellide titanium granules as a matrix for the local retention of cells.

Before the experiment we took an X-ray of the dog's jaw. The operation was performed under intravenous anesthesia in sterile conditions. We performed excision of the abnormal mucosa around a fistulous tract using a cutting tool, enucleated the granulation tissue from the sinus cavity, repeatedly flushed the sinus cavity with antiseptic solutions, polished the surface of bone tissue with a bone cutters along the entire length of the fistulous tract and filled the defect with nickellide titanium granules saturated with allogenic mesenchymal stem cells and covered, it with collagen membrane (Fig. 2).

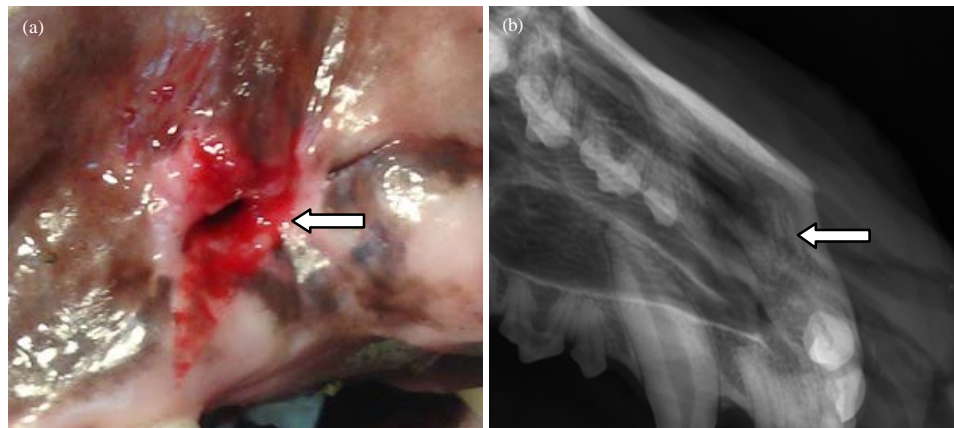


Fig. 1: Alveolar ridge of dog's upper right jaw with the formed oroantral fistula before the guided tissue regeneration surgery; a) External opening of fistulous tract in the dog's oral cavity; b) A fistulous tract is visible on the lateral X-ray as a shadow in the area of the missing canine (arrow)

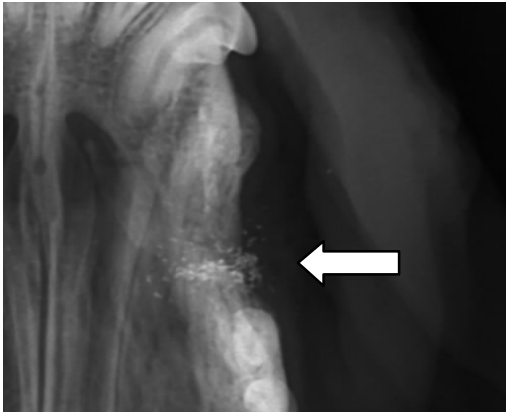


Fig. 2: X-ray of the alveolar bone of the upper right jaw of the dog. The X-ray image shows the fistulous tract closed with nickelide titanium granules, saturated with MSCs

We further conducted a fistula plasty with soft tissues, closed the wound edges with Vicryl, additionally coated with fibrin glue Tissucol (BAXTER AG, Austria), mixed with MSCs. The solution resulting from mixing two components of the Tissucol Kit turns into white elastic mass, tightly adhering to tissues (simulates main stages of blood clotting) and plays a role of MSCs carrier. During wound healing the fibrin layer completely dissolves, releasing the contained cells that stimulates the regenerative processes. The dog was prescribed a course of antibiotics. The total MSCs number administered in the dog was 6000,000. We subsequently conducted a dynamic X-ray and external examination of the animal.

RESULTS AND DISCUSSION

Allogeneic MSCs isolated from the dog's adipose tissue had fibroblast-like morphology and retained, it throughout the entire period of cell cultivation.

During the osteogenic differentiation we observed a change in cell shape from fusiform to cuboidal common to osteoblasts. Von Kossa reaction revealed the presence of substantial mineral deposits in the MSCs culture that was subjected to osteogenic differentiation (Fig. 3a) while the same were not observed in the cultures incubated in control medium (Fig. 3b).

Cultivating the MSCs in chondrogenic medium stimulated the formation of compacted spherical structures that were heavily stained with Alcian Blue. This indicates the presence of proteoglycan sulfate in the matrix typical of cartilage cells (Fig. 3c and d).

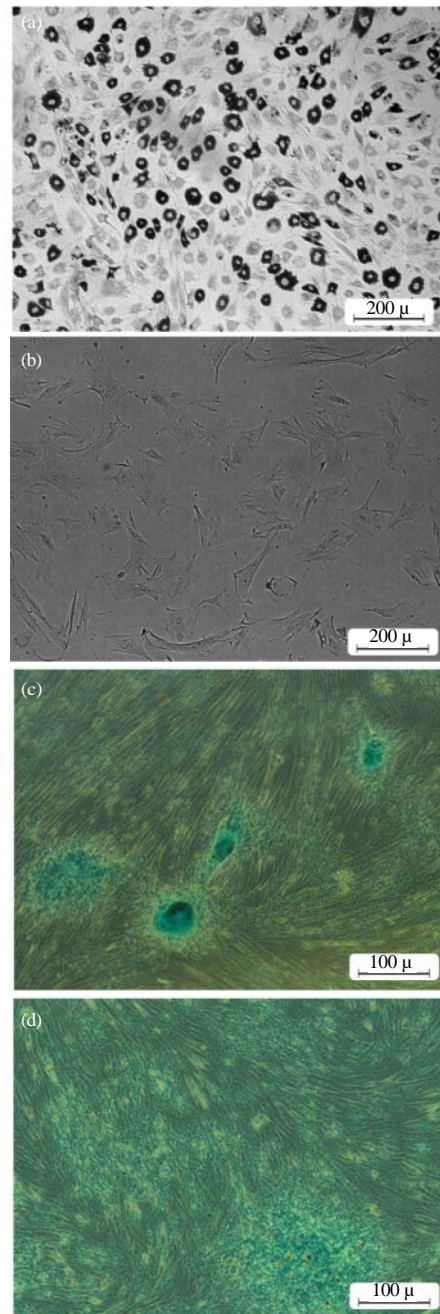


Fig. 3: Differentiation potential of the dog's MSCs of adipogenic origin, light microscopy: Osteogenic differentiation, the Von Kossa reaction: a) experiment, b) control; Chondrogenic differentiation, Alcian Blue staining: c) experiment; d) control

The result of the conducted surgery was a complete closure of oroantral fistula in a dog (Fig. 4).

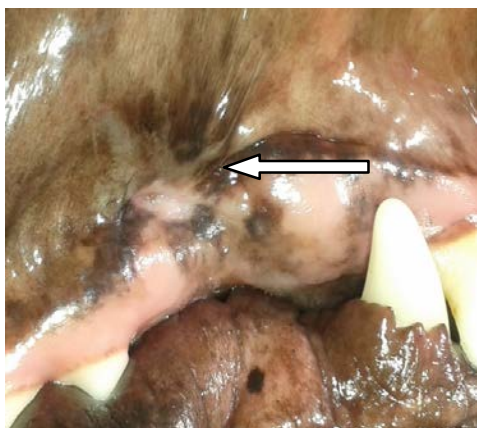


Fig. 4: Complete closure of the external opening of fistulous tract a month after the guided tissue regeneration surgery

CONCLUSION

Thus, the obtained results demonstrate the feasibility of using the proposed bone plasty method for removing bone defects in veterinary dentistry. The method is characterized by low invasiveness, immunological perfection, oncogenic security, requires no significant financial costs and can be used in a practical veterinary science and medicine.

ACKNOWLEDGEMENTS

The researchers is performed according to the Russian Government Program of Competitive Growth of Kazan Federal University and subsidy allocated to Kazan Federal University for the state assignment in the sphere of scientific activities. This research was funded by Russian Research Foundation grant No. 15-14-00046.

Some experiments were conducted with support of Interdisciplinary center for collective use of Kazan Federal University for cellular, genomic and post-genomic research in Volga region and Pharmaceutical Research and Education Center, Kazan (Volga Region) Federal University, Kazan, Russia.

REFERENCES

- Anonymous, 2011. Medical Materials and Implants with Shape Memory V.E. Giunter (Ed.). Tomsk, 1: 314-322.
- Anonymous, 2014. Medical Materials and Implants with Shape Memory. V.E. Giunter Tomsk (Ed.), 1: 17-23.
- Grudianov, A.I., V.I. Sysoeva and I.V. Ternovoi, 2012. Stem cells and their possible application in periodontics. Dentistry, No. 1, pp: 71-75.
- Khafizov, R.G., D.A. Azizova, M.Z. Mirgazitov, A.I. Frolova, V.E. Giunter *et al.*, 2012a. Features of manufacturing a porous membrane made of nickelite titanium alloy for guided tissue regeneration. Scientific notes of Bauman Kazan State Academy of Veterinary Medicine, 209: 330-335.
- Khafizov, R.G., M.Z. Mirgazitov, D.A. Azizova, A.I. Frolova *et al.*, 2012b. Restoration features of segmental defects of the alveolar part of the lower jaw in dogs. Scientific notes of Bauman Kazan State Academy of Veterinary Medicine, 209: 335-339.
- Katina, M.N., R.F. Gaifullina, Z.G. Haiatova, C.C. Emene and A.A. Rizvanov, 2012. Isolation, cultivation and differentiation of multipotent stem cells from fat tissue of *Rattus norvegicus* rats and *Mesocricetus auratus* hamsters. Cell Transplantol. Tissue Eng., No. 7, pp: 82-87.