

## Pathological Study on Renal Diseases in Cattle and Sheep

<sup>1,4</sup>F. Mahouz, <sup>3,4</sup>F. Benchaib Khoudja and <sup>2,4</sup>M. Chikhaoui

<sup>1,2</sup>Department of Clinical Sciences, Veterinary Sciences Institute, Tiaret, Algeria

<sup>3</sup>Department of Biological Sciences, Faculty of Sciences of Nature and Life, Tiaret, Algeria

<sup>4</sup>Ibn Khaldoun University (Univ-Tiaret), Tiaret, Algeria

**Abstract:** This study was carried out to determine the prevalence and type of renal lesions in cattle and sheep that were slaughtered at Tiaret abattoir. A total number of 750 clinically normal cattle and sheep of different sex, age and breed were randomly selected and renal samples were taken for histopathological study. Out of 300 cattle and 450 sheep studied, 79 (17.55%) and 55 (22.66%), respectively had renal lesions including interstitial nephritis, glomerulonephritis, Acute Tubular Necrosis (ATN), epithelionephritis, cysts and amyloidosis. Interstitial nephritis was the most common observed lesion (7.77%) in sheep and 6.33% in cattle, respectively. The prevalence of renal lesions in animals aged >2 year was 17% in cattle ( $p = 0.18$ ) and 32% in sheep ( $p < 0.05$ ). It is concluded that age is more important influence factor on renal lesions in sheep.

**Key words:** Kidney, pathology, prevalence, cattle, sheep

### INTRODUCTION

Renal diseases are important clinical problems and are frequent causes for illness and death in many animal species. Renal disorders have received much less attention in cattle and sheep. It may affect glomeruli, tubules, interstitial tissue and vessels. Some renal diseases may be associated with morphologic renal disease that affect one or both kidneys (Divers, 2008).

It may regress, persist or advance. But, many renal diseases are not detected until they become generalized, leading to renal failure. This study has been carried out to study the histopathological features of renal lesions and to determine their prevalence and types in cattle and sheep.

### MATERIALS AND METHODS

A total number of 750 clinically normal cattle and sheep from local Algerian breeds and different age were selected from Tiaret abattoir during 2 year (December 2010-2012) for detecting renal pathological changes. The Kidneys were first examined macroscopically and then sampled for histopathological studies. The samples included a piece of each kidney (1/1/1 cm) which were fixed in 10% neutral buffered formalin for routine hematoxylin and eosin staining.

### RESULTS

Prevalence of renal lesions in animals aged more than 2 year was 17% in cattle and 32% in sheep respectively, which was a significant difference ( $p < 0.05$ ) (Table 1).

**In sheep:** Seventy nine (17.55%) of the examined animals had renal lesions including interstitial nephritis (7.77%), glomerulonephritis (5.33%), epithelionephritis (1.33%), Kidney degeneration (2%), ATN (0.66%), sclerosis (0.22%) and cyst (0.22%).

**In cattle:** Fifty five (22.66%) had renal lesions. Interstitial nephritis (6.33%), glomerulonephritis (3.66%), epithelionephritis (3.66%), ATN (0.66%), amyloidosis (0.66%), Steatosis (0.33%) and tumorigenesis (0.33%). Interstitial nephritis and glomerulonephritis were the most common lesions found in this study in both sheep and cattle.

#### Macroscopic findings:

- Interstitial nephritis was characterized by swelling in between the kidney tubules

Table 1: Prevalence of renal lesions in slaughtered examined cattle and sheep

Age (year)	Animals		Lesions (%)	
	Cattle	Sheep	Cattle	Sheep
<2	100	300	13 (13%)	9 (3%)
≥ 2	200	150	34 (17%)	48 (32%)
Total	300	450	47 (15.66)	57 (12.66%)

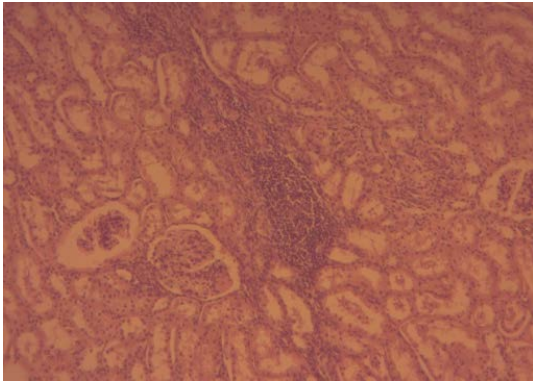


Fig. 1: Interstitial nephritis (H&E, ×10). Presence of an inflammatory infiltrate of lymphocytes and eosinophils in the interstitium

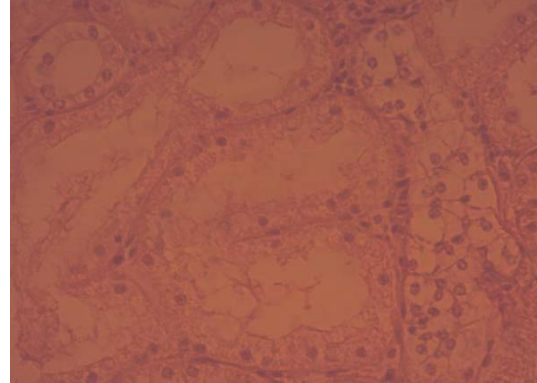


Fig. 3: Hydropic tubular degeneration (H&E, ×40)

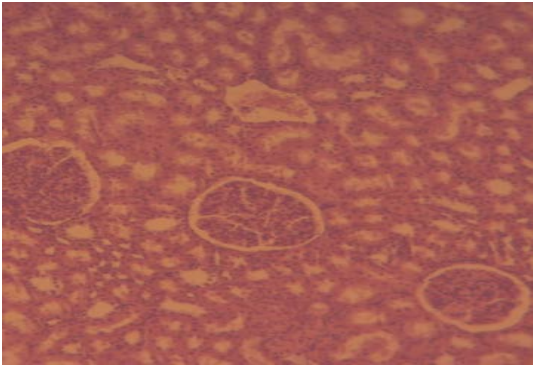


Fig. 2: Acute glomerulonephritis (H&E, ×10) Endothelial proliferation with neutrophils

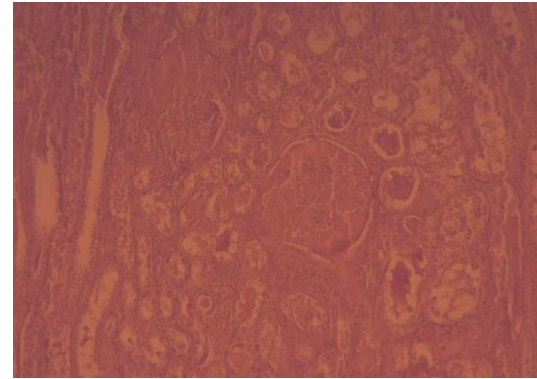


Fig. 4: Acute tubular necrosis (H&E, ×10)

- Glomerulonephritis was the second observed kidney lesion. Kidneys were macroscopically normal. They were pale and hypertrophied and the cut surface was shiny
- Epithelionephritis: the kidneys were slightly enlarged, pale and soft consistency
- Kidney degeneration: degenerative changes were lesions of the epithelium of the urinary tract in cattle associated with hydropic degeneration of medullary lesions in sheep
- Acute tubular necrosis: the kidneys were pale and slightly swollen, the cortex was finely strewn with small yellowish foci

- Epithelionephritis: lesions were characterized by a significant expansion of cortical renal tubules. Affected tubules were lined by flattened epithelium. Lymphocytes and plasma cells infiltration was observed
- Kidney degeneration: the hydropic degeneration was characterized by intracellular edema with cytoplasmic vacuolation (Fig. 3)
- Acute tubular necrosis: necrotic lesions affected the epithelium of the distal and proximal tubules in many foci (Fig. 4)

## DISCUSSION

The results of the present study revealed that (17.55) and (22.66%) of slaughtered sheep and cattle, respectively in Tialet abattoir had kidney lesions. The most common observed lesions were interstitial nephritis and glomerulonephritis followed by epithelionephritis, kidney degeneration and Acute Tubular Necrosis (ATN).

### Microscopic findings:

- In interstitial nephritis: the interstitium was edematous and showed an inflammatory infiltrate of lymphocytes and eosinophils (Fig. 1)
- Glomerulonephritis: in acute form, inflamed glomeruli were very fine small, red, dense, uniformly distributed in the renal cortex (Fig. 2)

**Table 2: Types of renal lesions**

Lesions	Sheep No. (%)	Cattle No. (%)
Interstitial nephritis	35 (7.77)	19 (6.33)
Glomerulonephritis	24 (5.33)	11 (3.66)
Epithelionephritis	6 (1.33)	11 (3.66)
Kidney degeneration	09 (2)	8 (2.66)
ATN	3 (0.66)	2 (0.66)
Amyloidosis	-	2 (0.66)
Sclerosis	1 (0.22)	-
Cyst	1 (0.22)	-
Steatosis	-	1 (0.33)
Tumor	-	1 (0.33)
Total	79 (17.55)	55 (22.66)

Interstitial nephritis is rarely recognized as a cause of clinical disease in farm animals although, it is a frequent post mortem finding in some species. Interstitial nephritis may be diffuse or have a focal distribution (Mathur and Dadhich, 2005).

In adult cattle, carrying infectious agents in the urinary tract is associated with this type of lesion. An allergic component is implicated in the occurrence of such lesions. Drugs acting by an immunological mechanism may be responsible for this type of lesions (Silva, 2004).

Glomerulosclerosis corresponds to a glomerular degeneration involving mesangial proliferation and obliteration of the glomerular capillaries (Camart, 2007).

Glomerulonephritis resulting from several disease mechanisms. Can be caused by deposition of immune complexes from a focus of infection in the glomerular basement membrane or to the antibody formation against exogenous antigen present at the basal membrane or against the basement membrane itself (Divers *et al.*, 1982).

These lesions appear after the attack glomerular tissues thus fixed by the immune system via complement and leukocytes. That encroaches on the glomerular filtration barrier, resulting in leakage of plasma proteins, particularly albumin in the urine (Assie *et al.*, 1999). Cutlip *et al.* (1980) showed that four clinically healthy cattle persistently infected with the virus, bovine viral diarrhoea, all had lesions of glomerulonephritis.

Marques *et al.* (2004) have shown a link between the disease and pest infestations. In which eleven water buffaloes naturally infected by *Fasciola hepatica* that immune complexes were deposited in the renal glomeruli, causing lesions membranoproliferative glomerulonephritis in seven buffaloes and glomerulonephritis mesangioproliferative in three others.

In epithelial nephritis, lesions were affecting tubular epithelial cells. Renal tubular cells are very active and responsible for many reabsorption and excretions shown in Table 2. They are very sensitive to hypoxia

(hypovolemic shock, toxic) which causes a reduction in the excretion of waste, including urea which is filtered by the glomerulus and reabsorbed in the tubules by 60% (Lorin *et al.*, 2009).

In kidney degeneration, overdose of some antibacterial substance including sulfonamides, can cause kidney degeneration lesions as the case described by Divers *et al.* (1982), Acute Tubular Necrosis (ATN) is a reversible condition characterized by primary renal tubular.

Acute tubular necrosis, is mainly due to three causes: toxic, infectious or hemodynamic disturbances of the kidney (Schott *et al.*, 2002; Racusen and Solez, 1986). Toxic causes are related to the ingestion of various substances or administration of certain drugs (Schott *et al.*, 2002).

The toxicity of most antimicrobials occurs due to two factors: the overdose or the right dosage administered to dehydrated animals, hypovolemic with reduced renal perfusion increasing the toxic effects on the kidney (Divers, 2008; Hoff *et al.*, 1998). Heba and Amer (2009) found that infection with clostridium perfringens type D could cause tubular necrosis.

## CONCLUSION

Kidney can be affected by both hematogenous and via the lower urinary tract. Urinary disorders are rarely diagnosed alone but often when complications or concurrent disease occur. Further, studies are required to determine the etiology of interstitial nephritis and its relationship to specific infections.

## REFERENCES

- Assie, S., V.F. Nguyen and A. Laval, 1999. Glomerulonephritis and endocarditis in a Charolais cow. *Bull. Gtv.*, 2: 89-92.
- Camart, B.P.B., 2007. Affections urinaires adult cattle. *Point Vet.*, 38: 31-37.
- Cutlip, R.C., A.W. McClurkin and M.F. Coria, 1980. Lesions in clinically healthy cattle persistently infected with the virus of bovine viral diarrhoea-glomerulonephritis and encephalitis. *Am. J. Vet. Res.*, 41: 1938-1941.
- Divers, T.J., 2008. Urinary Tract Diseases. In: *Rebhun's Diseases of Dairycattle*. Divers, T.J. and S.F. Peek (Eds.). Elsevier Publishing Company, St Louis, Missouri, pp: 447-466.
- Divers, T.J., W.A. Crowell, J.R. Duncan and R.H. Whitlock, 1982. Acute renal disorders in cattle: A retrospective study of 22 cases. *J. Am. Vet. Med. Assoc.*, 181: 694-699.

- Heba, H. and H.A. Amer, 2009. Pathological and bacteriological studies on *Clostridium perfringens* infection in kidney of cattle camel and sheep. *Egyptain J. Comp. Pathol. Clin. Pathol.*, 22: 88-108.
- Hoff, B., H.J. Boermans and J.D. Baird, 1998. Retrospective study of toxic metal analyses requested at a veterinary diagnostic toxicology laboratory in Ontario (1990-1995). *Can. Vet. J.*, 39: 39-43.
- Lorin, B., P. Belli and M. Frikha, 2009. Clinical cases of bovine medicine: Renal failure in two Holstein heifers due to poisoning acorns. *Vet. J.*, 160: 507-513.
- Marques, S.M.T., M.L. Scroferneker and M.I.A. Edelweiss, 2004. Glomerulonephritis in water buffaloes (*Bubalus bubalis*) naturally infected by *Fasciola hepatica*. *Vet. Parasitology*, 123: 83-91.
- Mathur, M. and H. Dadhich, 2005. Interstitial nephritis in sheep of Rajasthan. *Indian J. Anim. Res.*, 39: 151-152.
- Racusen, L.C. and K. Solez, 1986. Nephrotoxic tubular and interstitial lesions: morphology and classification. *Toxicol. Pathol.*, 14: 45-57.
- Schott, H.C., D.C.V. Metre and T.J. Divers, 2002. Diseases of the Renal System. In: *Large Animal Internal Medicine*. Smith, B.P. (Ed.). Elsevier Publishing Company, St Louis, Missouri, pp: 851-872.
- Silva, F.G., 2004. Chemical-induced nephropathy: A review of the renal tubulointerstitial lesions in humans. *Toxicol. Pathol.*, 32: 71-84.