

Rectal Prolapse and Successful Surgical Restoration with Enterorrhaphy in the Common Marmoset Monkeys (*Callithrix jacchus*)

Hidetoshi Ishibashi

Division of Primate Resources, National Center of Neurology and Psychiatry, 187-8502 Tokyo, Japan

Abstract: This is the first case report of traumatic rectal prolapse in common marmoset monkeys. In both of two cases, patients had two risk factors proposed in human cases: female and multiparous. In addition, both animals had suffered from diarrhea prior to the incidence, suggesting that diarrhea is another risk factor of rectal prolapse in this species. In one case, the prolapsed rectum was bitten by own family members and the extensive breeding obliged veterinarian to euthanize the patient. Hence, the marmoset was euthanized. In the other case, the prolapsed rectum was bitten by own family members but in this case surgical treatment, enterorrhaphy was performed and the treated animal survived until she was subjected to an experiment two years later.

Key words: Non-human primates, gastrointestinal diseases, surgical restoration, treatment, rectum, breeding

INTRODUCTION

Complete rectal prolapse is the protrusion of the entire thickness of the rectal wall through the anal sphincter complex. Women aged 50 and older are 6 times as likely as men to present rectal prolapse (Kairaluoma and Kellokumpu, 2005; Madiba *et al.*, 2005). Two thirds of women patients are multiparous and 15-30% report associated urinary dysfunction and vaginal prolapse (Gonzalez-Argente *et al.*, 2001).

The common marmoset (*Callithrix jacchus*) has been used increasingly in recent years for studies in bio-medical fields (Abbott *et al.*, 2003; Bert *et al.*, 2012). The primate institute in National Center of Neurology and Psychiatry Japan was founded in 2005. Since, then the number of marmoset gradually increased and 320-350 marmosets were housed in 2012. Averaged number of housed marmosets throughout the period is about 300. In the history of the institute, two cases of traumatic rectal prolapse which had not been reported in marmosets were found. This study reports the etiology and the possible surgical treatment of marmoset rectal prolapse.

MATERIALS AND METHODS

Both animals were captive-born adult female common marmosets that were maintained according to recommendations of the Guide for the Care and Use of Laboratory Animals (US National Research Council) and were conducted in accordance with the institutional guidelines. They were housed in groups, except after the

surgery in purpose-built caging 1.0 m wide×0.8 m deep×1.6 m high. Animals were fed a commercial diet (CMS1, Clea Japan Inc., Tokyo, Japan) with supplements of fruits. Room temperatures were maintained at 26-28°C, relative humidity 40-60%, fluorescent lighting from 07:00-19:00 and the rooms had 15 air changes per hour. All animals appeared clinically normal except diarrhea. Fecal condition was scored daily as a rate of firm (normal) stool: score 0 indicates no normal stools and score 5 indicates that all stools are normal. The average score of control animals in year 2012 was 4.19.

RESULTS AND DISCUSSION

A female marmoset fune was born on July 27th of 2004. As a breeder she has delivered 6 offspring by 3 times before October of 2007. After the delivery of two babies on November 11th, 2007, she has suffered from intermittent diarrhea and consequently the fecal score decreased (Fig. 1). On January 25th, 2008, a caretaker noticed her prolapsed rectum. The peroral skins of cage-mates were stained with blood and their cage was stained with much blood. Fune was diagnosed as being hemorrhagic shock and was euthanized. Postmortem hemoglobin was 5.6 g/dL.

A female marmoset Takeruko was born on September 16th of 2004. As a breeder she has delivered 26 offspring by 11 times before June of 2012. She has delivered two babies on July 6th, 2012. She has suffered from severe diarrhea from July 15th (Fig. 1). On August, 26th, a caretaker noticed her prolapsed rectum. The peroral skins

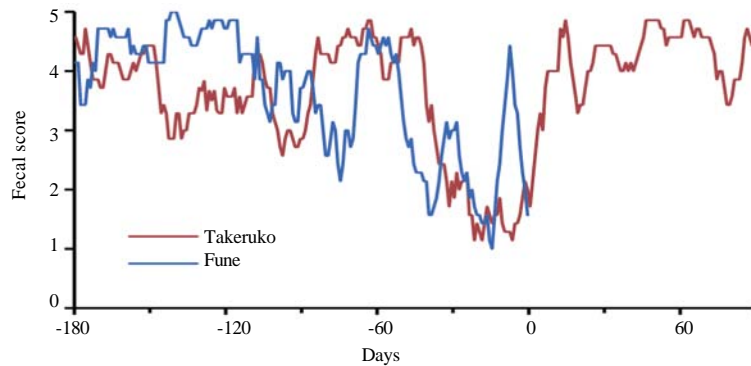


Fig. 1: Fecal scores of 2 marmosets that had rectal prolapse. The daily fecal scores were moving-averaged over past 7 days. The day 0 indicates the day of rectal prolapse. The low scores immediately before the incidence of rectal prolapse

of cage-mates were stained with blood and their cage was stained with much blood. The rectal tissue was partially cut off but physical condition was not worst and researcher operated enterorrhaphy after ventrotomy, pulling back of the rectum to the abdominal cavity and resection of wounded intestine. Intestine was sutured by Albert-Lembert suture method with 4-0 absorbable suture (PDS II, k.k. Johnson and Johnson, Tokyo, Japan). To prevent peritonitis, researcher administered antibiotics (62 mg/kg BW of Viccillin, Meiji Seika Pharma Co., Ltd, Tokyo, Japan) intraperitoneally before the abdominal closure. Follow-up 12 mg/kg BW of Viccillin and anti-inflammatory agent (Predonine, Shionogi and Co., Ltd., Osaka, Japan) were administered twice a day for 3-7 days, respectively. Additionally, researcher orally administered a probiotics product (Biofermin R, Taisho Pharmaceutical Co., Ltd., Tokyo, Japan). Fecal score ameliorated from the 3rd week post-operatively and was stable thereafter until she was subjected to an experiment on August 25th of 2014.

In both marmosets, solitary rectal ulcer that is potentially induced by rectal prolapse (Goei and Baeten, 1990) was not macroscopically apparent. Both marmosets did not show urinary dysfunction and vaginal prolapse. Both marmosets had two risk factors: female and multiparous. Another risk factor of rectal prolapse in squirrel monkeys, another new world monkey species is a Giardiasis (Hamlen and Lawrence, 1994). However, this is not likely in common marmosets, since, 20 and 4% of a colony of marmosets younger and older than 1 year, respectively were positive for Giardiasis but none of animals manifested clinical signs of disease (Kalishman *et al.*, 1996) and more importantly that due to an anti-parasitic program giardia has not been observed

for several years in the present institute. Thus, there must be another factor, other than the Giardiasis, influencing the incidence of the rectal prolapse in marmosets. A possible risk factor is the diarrhea as both marmosets had diarrhea prior to the incidence of rectal prolapse (Fig. 1).

CONCLUSION

This report proposes that diarrhea is a risk factor of rectal prolapse and that surgical restoration is a practical treatment to traumatic rectal prolapse.

ACKNOWLEDGEMENT

This research is supported by Takeda Science Foundation.

REFERENCES

- Abbott, D.H., D.K. Barnett, R.J. Colman, M.E. Yamamoto and N.J. Schultz-Darken, 2003. Aspects of common marmoset basic biology and life history important for biomedical research. *Comp. Med.*, 53: 339-350.
- Bert, A., D.H. Abbott, K. Nakamura and E. Fuchs, 2012. The marmoset monkey: A multi-purpose preclinical and translational model of human biology and disease. *Drug Discovery Today*, 17: 1160-1165.
- Goei, R. and C. Baeten, 1990. Rectal intussusception and rectal prolapse: Detection and postoperative evaluation with defecography. *Radiol.*, 174: 124-126.
- Gonzalez-Argente, F.X., A. Jain, J.J. Noguerras, G.W. Davila and E.G. Weiss *et al.*, 2001. Prevalence and severity of urinary incontinence and pelvic genital prolapse in females with anal incontinence or rectal prolapse. *Dis. Colon Rectum*, 44: 920-925.

- Hamlen, H.J. and J.M. Lawrence, 1994. Giardiasis in laboratory-housed squirrel monkeys: A retrospective study. *Lab. Anim. Sci.*, 44: 235-239.
- Kairaluoma, M.V. and I.H. Kellokumpu, 2005. Epidemiologic aspects of complete rectal prolapse. *Scand. J. Surg.*, 94: 207-210.
- Kalishman, J., J. Paul-Murphy, J. Scheffler and J.A. Thomson, 1996. Survey of cryptosporidium and giardia spp. in a captive population of common marmosets. *Lab. Anim. Sci.*, 46: 116-119.
- Madiba, T.E., M.K. Baig and S.D. Wexner, 2005. Surgical management of rectal prolapse. *Archives Surg.*, 140: 63-73.