

Experimental Mastitis in Cows Induced by Field Isolates of *Nocardia farcinica*

¹Abdelbasit O. Ahmed, ²H. A. E. Babiker, ³Adil Mahgoub and ⁴Mohamed E. Hamid

¹Department of Clinical Medicine, Faculty of Veterinary Medicine, University of Khartoum North,
P.O. Box 32, Khartoum, Sudan

²Department of Clinical Studies, Faculty of Veterinary Medicine, University of King Faisal,
31982 Alahsa, P.O. Box 400, Kingdom of Saudi Arabi

³Department of Preventive Medicine, Faculty of Veterinary Medicine, University of Khartoum North,
P.O. Box 32, Khartoum, Sudan

⁴Department of Microbiology, College of Medicine, King Khalid University,
61314 Abha, P.O. Box 641, Kingdom of Saudi Arabia

Abstract: Mastitis is a common disease of lactating cows and is caused by several different types of bacteria including *Nocardia farcinica*. The objective of the current study is to demonstrate pathology clinical manifestations of experimental mastitis in dairy cows induced by field isolates of *Nocardia farcinica*. The infection was done by intramammary infusion in two healthy lactating dairy cows using two field isolates of *N. farcinica*. The infected animals were examined periodically for clinical signs and laboratory profiles. The first cow showed typical clinical signs of acute *Nocardia mastitis* with granulomatous reaction whereas the second cow showed sub-acute clinical mastitis. While the first cow died within a few days post infection, the second cow survived but didn't respond to standard mastitis treatment. Treatments of the experimentally induced mastitis with Neomastipra® and Gentamast® failed to cure the infection and after the withdrawal period of both drugs *Nocardia* continued to shed from udder. Clinical isolate of *Nocardia farcinica* caused mastitis that was either subacute/irresponsive to treatment or fatal peracute leading to death.

Key words: Mastitis, cows, *Nocardia farcinica*, experimental infection, clinical manifestations, granulomatous

INTRODUCTION

Mastitis is a common disease of lactating cows and is caused by a number of different types of bacteria. The organisms most frequently involved in mastitis in goats are *Staphylococcus aureus*, streptococci, *Corynebacterium pyogenes*, mycoplasma, coliforms and *Nocardia* (Radostitis *et al.*, 2000; Riemann and Bergmann, 2000) member of the genus *Nocardia*, especially, *N. asteroides* and *N. farcinica* have been reported as infrequent causal agents of mastitis in dairy cattle (Battig *et al.*, 1990; Moreyra *et al.*, 1980; Pier *et al.*, 1961) including some outbreaks (Manninen *et al.*, 1993).

Several *Nocardia* species cause various infections mainly pulmonary and cutaneous diseases but can be systemic. Cutaneous nocardiosis is a rare infection and can be presented as a disseminated disease which can be misdiagnosed or passed undiagnosed given its nonspecific clinical picture. In the past *Nocardia farcinica* had been associated with bovine farcy, a

chronic lymphocutaneous disease of zebu cattle in the tropics. It is uncertain if *Nocardia farcinica* produces cutaneous lesions in animals that simulate bovine farcy. There is a need for awareness and need to watch cultures for a longer period to be able to detect and diagnose nocardiosis.

In Sudan there were some reports indicating the presence of *Nocardia mastitis* (Awad, 1960; Hamid *et al.*, 1998; Maldonado *et al.*, 2004; Shigidi and Mamoun, 1981) but still the extent and economical significance of the disease remains to be studied with particular emphasis on recognizing unusual microbial isolates such as actinomycetes notably *Nocardia*. These are most likely represent difficulty in treatment and control (Quinn *et al.*, 1999).

The objective of this study was to investigate the pathogenicity and clinical effect of experimental mastitis in healthy lactating dairy cows using two field isolates of *N. farcinica*.

MATERIALS AND METHODS

Experimental cows: Two lactating cows were selected for the experimental mastitis infections. Cow (1) was a first lactation heifer with no previous history of infectious mastitis. Cow (2) was a mature cross-breed cow at the mid of its third lactation with a history of mastitis then treated and made complete recovery, since, 8 months ago.

The 2 dairy cows were proven to be free of mastitis by repeated per inoculation cultural and microscopic examination of their milk using: Rapid Mastitis Test (RMT) and Direct Microscopic Somatic Cell Count (DMSCC) (Quinn *et al.*, 1999).

Bacterial strains: About 2 strains of *Nocardia farcinica* (SD1312, SD1828) were used for the inoculation. Inoculum was a suspension of the organisms made in sterile saline solution. The two strains have been isolated from mastitis case and have been identified previously (Maldonado *et al.*, 2004).

Primary isolation from milk samples was done using Tryptic Soya Agar (TSA; Difco). Infected milk samples were collected and transported immediately to the laboratory. Aliquots were inoculated onto TSA, incubated at 37°C and examined daily for bacterial growth. Subsequent subcultures were done using Glucose Yeast Extract Agar (GYEA; Glucose, 10 g; yeast extract, 10 g agar, 14 g, distilled water 100 mL; pH 6.8).

The grown cultures were subjected to an identification scheme using selected morphological and cultural characteristics (Goodfellow, 1998) and mycolic acid analysis (Hamid *et al.*, 1993).

Experimental infection: The vial bacterial counting method for the inoculum was done according to, miles-misra technique (Quinn *et al.*, 1999). The amounts of inoculum used were as follows:

Cow (1): The left front quarter was used as a control by infusing 1 mL of sterile saline solution. The left rear quarter was given 1 mL of *N. farcinica* (SD1828) which was approximately 350,000,000 organisms per mL. The right front quarter was given 0.1 mL of *N. farcinica* (SD1312). The right rear quarter was given 1 mL of *N. farcinica* (SD1312) which were approximately 1,450,000 organisms per mL.

Cow (2): The left front quarter was used as a control which was infused by sterile saline solution. The left rear quarter was given 1 mL of *N. farcinica* (SD1312). The right front quarter was given 0.1 mL of *N. farcinica* (SD1828) and the right rear quarter was given 1 mL of *N. farcinica* (SD1828). The same inoculum with the same concentration of each organism was used for both infected cows.

Before infusion complete milking of the quarters was done. Outer surface of the udder and teats was washed with water and potassium permanganate (0.1%) and the teats orifices were carefully disinfected with 70% alcohol. The preparation of the inoculum and the cultural and microscopic examinations of milk samples post inoculation were critically done under aseptic condition.

After the intramammary infusion the inoculated teat was massaged to distribute the inoculum and the gland was not milked for 24 h in order to allow the organisms to establish itself. Daily rectal temperature, RMT reaction and clinical observation were recorded for each experimentally infected cow. Milk samples from each quarter were taken aseptically every 2 days and were examined culturally by using Glucose Yeast Extract Agar (GYEA) medium and microscopically by Modified Ziehl-Neelsen stain technique (Quinn *et al.*, 1999).

The Direct Microscopic Somatic Cell Count (DMSCC) is the procedure of evenly spreading a measured volume of milk over a calibrated area of a microscope slide, staining the film and counting somatic cells within a specified area of the film (Packard *et al.*, 1992). The count is then converted to cells per milliliter (mL) by a factor which is determined by magnification and area counted. The inoculum was infused intramammary through the teat orifices in the teat canal by sterile pipette. All of the methods done for cow 1 were applied for cow 2 in the same way and under the same condition. Histopathological examination was done by surgical removal of the granulomatous lesions. The blocks were fixed in 10% formal saline, embedded in paraffin, cut at 5 µm thickness and stained with Hematoxylin and Eosin (H&E).

Treatment: Treatment of cow 2 was done as follows: the udder was washed and disinfected with 0.2% solution of potassium permanganate and 70% alcohol and milk was completely drained using sterile teat syphon. The skin over the udder was dried off with a piece of quaze.

Gentamycin injectable solution (Alfamycine 5%, Alfasan Nederland BV, Kuipersweg 9, 3449 JA Woerden) was injected intravenously for 5 consecutive days. Gentamast® intramammary infusion (Pantex Holland B.V., The Netherlands) was infused in each infected quarter of the udder.

RESULTS AND DISCUSSION

Results of the clinical and laboratory observations conducted in the 2 cows were as follows:

Cow (1): After the first 24 h post inoculation no abnormalities were seen in this cow. The udders and milk secretions were normal. By the 2nd day post inoculation

body temperature was 39.7°C, heart rate: 96/min; pulse rate: 94/min. The quarters inoculated with nocardia cultures produced visibly altered milk which contained clots and strands of exudate. The control on the other hand, gave milk which appeared normal.

By the 3rd day all inoculated quarters were enlarged and hard and the inflammatory swelling extended to the ventral side of the abdomen. The cow was feverish (40.4°C) and was depressed and inappetent. There were detectable pronounced changes in milk secretion, color and consistency. Total milk yield was considerably reduced. The infected quarters were hyperemic, painful and warm.

By the 5th day, all inoculated quarters were much enlarged and firmly fibrosed. Body temperature reached 41.2°C, heart rate 90/min pulse rate 88/min. There was increase of local udder temperature with inflamed supramammary lymph nodes. A milk secretion of the right front quarter was reddish in color with flakes and clots. The secretion of the right rear quarter was very thick with creamy color. The left rear quarter secretion was yellowish with clots and flakes. The cow was extremely depressed, anorexic with lameness. There was lacrimation and diarrhea. Loss of body condition was marked. Milk sample was positive for RMT with increase somatic cell counts.

After 6 days post inoculation, the body temperature was 39.7°C, heart rate 92/min and pulse rate 90/min. The cow was depressed and there was loss of body condition

with refuse of feed. Udder palpation revealed a very firmer feel, increased local temperature and pain with reduced milk yield in the three infected quarters and enlarged supramammary lymph nodes. Udder inspection revealed increase in size and the inflammatory swelling extended to cover an area at the ventral part of the abdomen. The udder was asymmetrical and the right half was much enlarged than left one. The left front quarter (the control) still remained small. No infection from the neighboring three quarters was detected. Milk yield was reduced markedly. Milk from the three infected quarters reacted strongly to RMT with increased somatic cell counts. Udder secretion revealed increased discoloration and contents as seen on the 5th day post inoculation. Two discrete nodules one of 2 cm and the other of 4 cm in diameter were palpable on the udder. The graphs of the daily rectal temperature record and the somatic cell counts related to cow 1 showed a gradual and continuous increase of both parameters.

Cultural analysis of the milk sample from cow 1 before inoculation on GYEA medium was found negative for any nocardial strains and modified ziehl-neelsen stained smears gave negative reaction. Cultural and microscopic analysis of milk samples for cow 1 after 6 days of inoculation showed the presence of branching filamentous organism which was acid fast (Fig. 1).

About 7 days following inoculation the infected cow 1 showed signs of depression and was found dead on the morning of the 8th day.

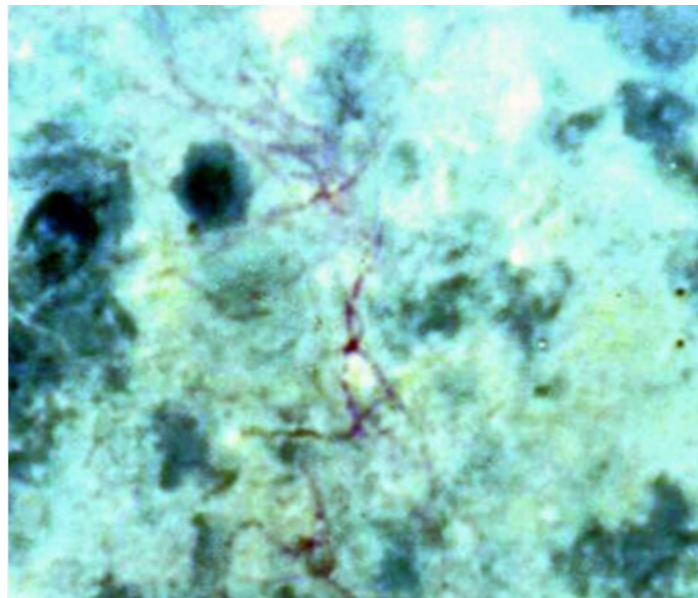


Fig. 1: Modified Ziehl-Neelsen-stained smear made from udder discharge of a cow experimentally infected with *Nocardia farcinica* SD1828. Notice the branching filamentous organisms ($\times 100$)

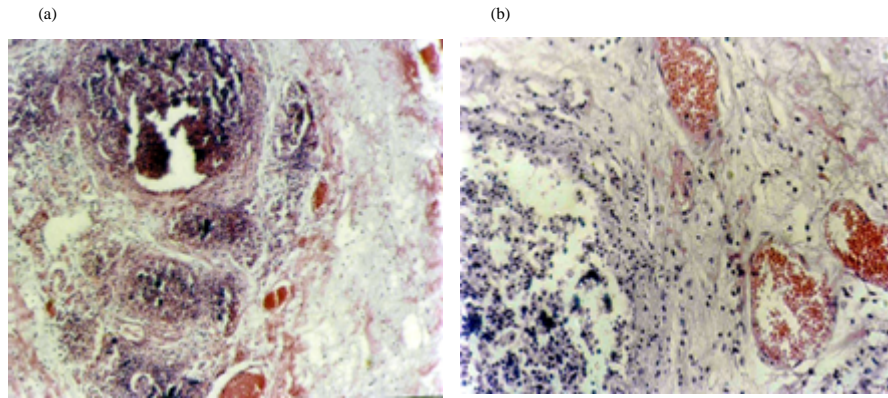


Fig. 2a, b: Histopathological section from a mastitic udder of a crossbred cow experimentally infected with *Nocardia farcinica* SD1828. Notice the granulomatous reactions with a central zone of caseation, cavitations and necrosis with infiltration of inflammatory cells and fibrous tissues

Necropsy of this cow revealed areas of mixed congestion and hemorrhage and small purulent foci in the inoculated quarters. Serous fluid with fibrinous shreds was found in the pleural cavity. Surgical removal of the largest nodules exposed a draining sinus tract filled with pus underneath. Cultural and microscopic examinations of this pus sample showed branching filaments and MZN positive organisms which is characteristic for *Nocardia farcinica*.

On histological examination the lesion revealed granulomatous changes. It's characterized by necrosis of the glandular structure and infiltration of inflammatory cells. These are lymphocytes, macrophages, epitheloid and neutrophils. The necrotic lesion is surrounded by fibrous connective tissue (Fig. 2). In the center of the lesion there are colonies of *Nocardia farcinica* with pyknotic nuclei of the glandular cells and pus cells.

Cow (2): After 24 h from inoculation the animal was examined and no changes were recorded in its health. By the 2nd day post inoculation, the rectal temperature increased by 1.2-40°C with moderate swelling and hardness of the two right quarters. Slightly visible altered secretions were shed by the three infected quarters. Milk samples were positive for RMT and this result was assessed as score 1 (slight slime) with elevation of somatic cell counts.

By the 4th day after inoculation, the rectal temperature was 40.7°C, heart rate 86/min and pulse rate 85/min. The three infected quarters were increased in size and assumed a more firmly texture (Fig. 3). Milk yield was reduced. The visible alteration of the milk secretions became clear. Milk from the two right quarters was yellowish in color with clots and flakes. Milk from the left rear quarter was whitish and wateriness with clots. Milk

samples from the three infected quarter's revealed strong positive RMT reaction (score 2). Also, there was increase in the somatic cell counts. The cow was normal with good appetite.

By the 7th day post inoculation the cow's body temperature was 38.6°C, heart rate 75/min and pulse rate 72/min. No prominent changes were seen in the udder size and texture more than those described for the 4th day. There was more decrease in milk yield, especially that from the left rear quarter. Secretions from the right quarters were more yellowish with more clots and shreds of exudate and from the left rear quarter the secretion was very thick with grey color. There was slight change in the milk secretion of the left front quarter (control). Milk samples gave positive reaction with RMT with increase in somatic cell counts. Milk samples from the three infected quarters were positive culturally and microscopically for *Nocardia* sp.

On the 10th day after inoculation general clinical improvement was apparent and no systemic reactions were recorded in the animal. This included all parameters associated with these reactions. There was gradual disappearance of udder swelling and a decrease in the firmer feel of the udder tissue. There was a decrease in milk yield and the left rear quarter was completely ceased milking. There was improvement in the milk secretion in both color and consistency. Milk samples from infected quarters reacted moderately to RMT (score 2) with increased somatic cell counts. Cultural and microscopic examination of milk samples gave positive results for *Nocardia* sp.

By the 12th day this case received gentamast® intramammary (Pantex Holland B.V. The Netherlands) plus intravenous gentamycin. By the 15th day post inoculation, complete clinical improvement of the animal

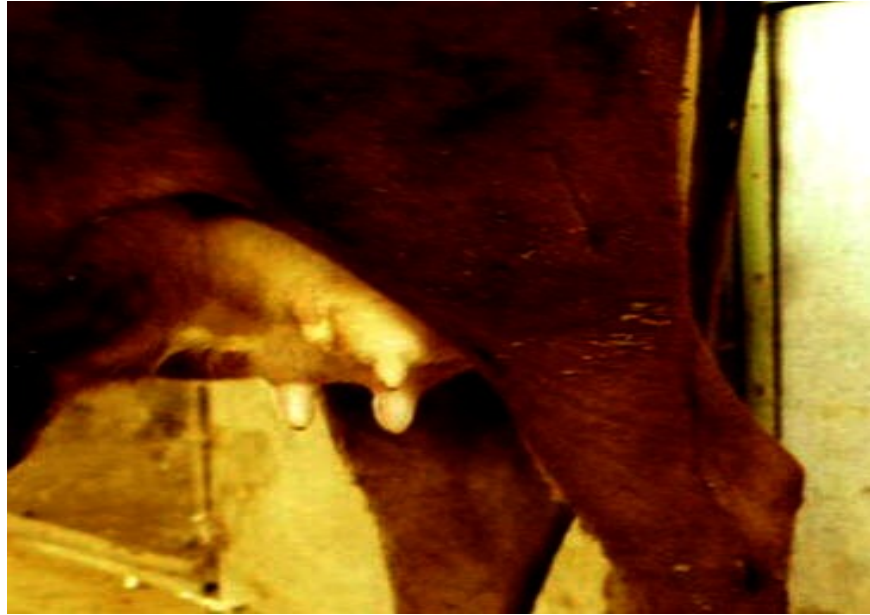

Fig. 3: A kenana-friesian crossbred cow with severe mastitis experimentally induced by *Nocardia farcinica* strains. Note the swelling and the asymmetry of the infected three quarters (No. 2-4) in comparison to the control quarter No.1

took place. There were only slightly visible altered milk secretions and the milk color and consistency went towards normal quickly. Milk from infected quarters reacted moderately to RMT with increased values of somatic cell counts. The size and consistency of the udder tissue was almost normal.

Cultural and microscopic examinations of milk samples from infected quarters were positive for *Nocardia* sp. Although, treatment with gentamycin improved the condition and the systemic reactions disappear but milk secretion was still positive for *Nocardia* sp.

In the present study, experimental infections of mastitis were attempted in two lactating dairy cows which were proven to be free of the disease by repeated preinoculation cultural and microscopic examination of their milk. This research was done in order to study the reproducibility of the infection with two *Nocardia farcinica* isolates and to observe the sequence of clinical signs from the time of infection. Clinical and laboratory observations conducted during each experimental infection were recorded.

Nocardia is known to cause a variety of suppurative infections of humans and animals. The most pathogenic species reported are *N. africana*, *N. asteroides*, *N. farcinica*, *N. nova*, *N. brasiliensis*, *N. otitidiscaviarum*, *N. pseudobrasiliensis* and *N. transvalensis* (Goodfellow, 1998). The incidence of such infections in man and animals in many tropical countries is not known

though nocardiosis has been reported from most regions of the world. But is well established that nocardiae can be easily overlooked under routine culture and smear examination. Mastitis continues to be one of the major disease problems facing dairy farmers (Radostitis *et al.*, 2000; Riemann and Bergmann, 2000). In spite of all control efforts taken mastitis is still the most important disease problem in the dairy industry (Gomes and Henriques, 2016). Among these etiologic agents was the nocardial mastitis which seems to be more serious than previously thought (Battig *et al.*, 1990; Cook and Holliman, 2004; Maldonado *et al.*, 2004; Manninen *et al.*, 1993). *Nocardia asteroides* type 4, *Nocardia otitidiscaviarum*, *Nocardia nova* (type 3) and *Nocardia farcinica* (type 5) were found to cause nocardial bovine mastitis in dairy herds with poor environmental hygienic conditions between milking and inappropriate intramammary therapy (Ribeiro *et al.*, 2008). However, knowledge regarding clinical picture, epidemiology and treatment of bovine mastitis caused by these actinomycetes are still needed for initiating better control programs.

In this study, infection produced in cow (1) showed severe udder lesions with peracute symptoms and systemic reactions. These findings were similar to previous records by Pier *et al.* (1961). When they did their experimental infections via the teat canal of the mammary glands by *Nocardia asteroides*. In addition to that those researchers during their experiment infuse novobiocin and

sulfamerazine because of fearing a fatal termination of their experimental lactating heifer. Because our experimental heifer didn't receive any of these antibiotics it died by day 8 post inoculation. On histological examination, the granulomatous nature of the lesions was evident and this also agreed with the findings of Pier *et al.* (1961).

Cow (2) which was at her 3rd lactation cycle with a previous history of mastitis, produced clinical response less severe than that shown by cow (1). It is postulated that like this cow may have a decreased susceptibility to this infection through a more effective host defense mechanism. High antibody-mediated immune responses associated with decreased mastitis and improved response to vaccination (Hernandez *et al.*, 2003). Leukocytic response to staphylococcal antigens in experimental cows was found depended on earlier episodes with staphylococcal cell materials (Targowski and Berman, 1975) which clearly explained the immune response experienced by cow (2) that resulted in lesser acute mastitis (Fig. 3) than that caused in cow (2) which had ultimately died.

Although Neomastipra® was successful in treating streptococcal and *Staphylococcal* mastitis but in case of *Nocardial mastitis* (one treated case) only limited improvement occurred in the disappearance of systemic reactions without improvement in the abnormalities of udder, milk and bacteriology. This confirms that *Nocardia* cannot be treated by penicillin like streptococci and staphylococci.

CONCLUSION

Back to history of mastitis treatment, it was stated that: "To treat bovine *mastitis*, particularly caused by *Streptococcus agalactiae* it is usual to prepare penicillin in the form of an oil suspension which is introduced into the gland via the teat sphincter". Penicillin is used in sodium or procaine forms and doses of up to 300000 units are used for each affected quarter.

ACKNOWLEDGEMENTS

The researchers are grateful to Prof. M. Goodfellow (Newcastle University) for help with reference materials. The financial support from the British Council (DFID KHT/991/21/Vet) is highly acknowledged.

REFERENCES

Awad, F.I., 1960. *Nocardiosis* of the bovine udder and testis. *Vet. Rec.*, 72: 341-342.

- Battig, U., P. Wegmann, B. Meyer and J.H. Penseyres, 1990. *Nocardia mastitis* in cattle 1: Clinical observations and diagnosis in 7 particular cases. *Schweizer Archiv Tierheilkunde*, 132: 315-322.
- Cook, J.G. and A. Holliman, 2004. Mastitis due to *Nocardia asteroides* in a UK dairy herd following restocking after FMD. *Vet. Rec.*, 154: 267-268.
- Gomes, F. and M. Henriques, 2016. Control of bovine mastitis: Old and recent therapeutic approaches. *Curr. Microbiol.*, 72: 377-382.
- Goodfellow, M., 1998. The Genus *Nocardia* Trevisan 1889, 9AL. In: Topley and Wilson's Microbiology and Microbial Infections, Balows, A. and B.I. Duerden (Eds.). Edward Arnold, London, UK., pp: 464-489.
- Hamid, M.E., D.E. Minnikin, M. Goodfellow and M. Ridell, 1993. Thin layer chromatographic analysis of glycolipids and mycolic acids from *Mycobacterium farcinogenes*, *Mycobacterium senegalense* and related taxa. *Zentralbl. Bakteriol.*, 279: 354-367.
- Hamid, M.E., S.M. El-Sanousi, D.E. Minnikin and M. Goodfellow, 1998. Isolation of *Nocardia farcinica* from Zebu Cattle suffering from Mastitis. *Sudan. J. Vet. Sci. Anim. Husband.*, 37: 66-71.
- Hernandez, A., N. Karrow and B.A. Mallard, 2003. Evaluation of immune responses of cattle as a means to identify high or low responders and use of a human microarray to differentiate gene expression. *Genet. Selection Evol.*, 35: S67-S81.
- Maldonado, L.A., M.E. Hamid, O.A.G. El-Din and M. Goodfellow, 2004. *Nocardia farcinica*-a significant cause of mastitis in goats in Sudan. *J. South Afr. Veterinary Assoc.*, 75: 147-149.
- Manninen, K.I., R.A. Smith and L.O. Kim, 1993. Highly presumptive identification of bacterial isolates associated with the recent Canada-wide mastitis epizootic as *Nocardia farcinica*. *Can. J. Microbiol.*, 39: 635-641.
- Moreyra, H., P.P. Martinez and V.M. Villamar, 1980. Bovine mastitis caused by *Nocardia asteroides*: First report in Peru. *J. Vet. Med. Ser. B.*, 27: 22-27.
- Packard, Jr. V.S., Tatini, R. Fugua, J. Heady and C. Gilman, 1992. Direct Microscopic Methods for Bacteria or Somatic Cells. In: Standard Methods for the Examination of Dairy Products, Marshall, R.T. (Ed.). 16th Edn., American Public Health Association, Washington, DC, USA., pp:309-325.
- Pier, A.C., E.H. Willers and M.J. Mejia, 1961. *Nocardia asteroides* as a mammary pathogen of Cattle II: The sources of Nocardial infection and experimental reproduction of the disease. *Am. J. Vet. Res.*, 22: 698-703.

- Quinn, P.J., M.E. Carter, B.K. Markey and G.R. Carter, 1999. The Actinomycetes. In: Clinical Veterinary Microbiology, Quinn, P.J. (Eds.). Wolfe, Baltimore, pp: 144-155.
- Radostits, O.M., J.H. Arundel, C.C. Gay, D.C. Blood and K.W. Hinchcliff, 2000. Veterinary Medicine: A Textbook of the Diseases of Cattle, Sheep, Pigs, Goats and Horses. 9th Edn., Saunders Publisher, London, UK., ISBN:9780702026041, Pages: 1877.
- Ribeiro, M.G., T. Salerno, A.L.D. Mattos-Guaraldi, T.C.F. Camello and H. Langoni *et al.*, 2008. Nocardiosis: An overview and additional report of 28 cases in cattle and dogs. *Rev. Inst. Medicina Trop. Sao Paulo*, 50: 177-185.
- Riemann, T. and A. Bergmann, 2000. Epidemiology, pathogenesis, treatment and prevention of bovine acute Escherichia coli mastitis, a literature review. *DTW. Dtsch. tierarztliche Wochenschr.*, 107: 444-454.
- Shigidi, M.T. and I.E. Mamoun, 1981. Isolation of *Nocardia asteroides* from cattle with mastitis in the Sudan. *Bull. Anim. Health Prod. Afr.*, 29: 275-278.
- Targowski, S.P. and D.T. Berman, 1975. Leukocyte response of bovine mammary gland to injection of killed cells and cell walls of *Staphylococcus aureus*. *Am. J. Vet. Res.*, 36: 1561-1565.