

Comparative Survey of the Detection of Optic Disk and Exudates in Retinal Images

¹V. Vijaya Kumari Miste and ²N. Suriyanarayanan

¹Department of ECE, V.L.B. Janakiammal College of Engineering and Technology,
Coimbatore 641-042, India

²Department of Physics, Government College of Technology, Coimbatore 641-013, India

Abstract: A problem of fundamental importance in retinal image analysis is the extraction of exudates and the detection of optic disk. Detection of the exudates is the fundamental requirement to diagnose the progress of diabetic retinopathy. The detection of optic disk is very essential to locate the various anatomical features in the retinal image. Screening to detect retinopathy disease can lead to successful treatments in preventing visual loss. This study discuss different methods involved in the detection of optic disk and exudates.

Key words: Diabetic retinopathy, optic disk, exudates, anatomical features, visual loss, retinal image

INTRODUCTION

Diabetic retinopathy is a severe and widely spread eye disease, which can be regarded as manifestation of diabetes on the retina. Retinopathy literally means damage to the retina. There are actually 2 types of retinopathy. The most common type is early or background diabetic retinopathy. In this condition, diabetes gets damages in the capillaries of the retina and microscopic leaks are formed in these vessels. Leakage causes the retina to swell, which interferes with normal vision. Background diabetic retinopathy may be associated with macula edema. The macula is the part of the affected retina; edema refers to the swelling caused by leakage. The macula, which enables us to see sharp detail, is the center of the retina, so macular edema can cause problems with central vision. The 2nd type of retinopathy is proliferative diabetic retinopathy. In this condition, the capillaries of the retina shuts down. This causes new blood vessels to grow in the retina (revascularization). Retinal neo vascularization may also lead to scar tissue. This scar tissue may contract, pull on the retinal surface and result in a retinal detachment. New blood vessels may grow on the iris of the eye and cause a form of glaucoma. These complications can cause a serious loss of vision, or even total blindness. Figure 1 shows a normal retina, portions of the required boundaries are clearly visible, other portions are obscured or very indistinct. The original image is 512×512 pixels and 8 bit grey scale.

Screening to detect retinopathy disease can lead to successful treatments in preventing visual loss. The

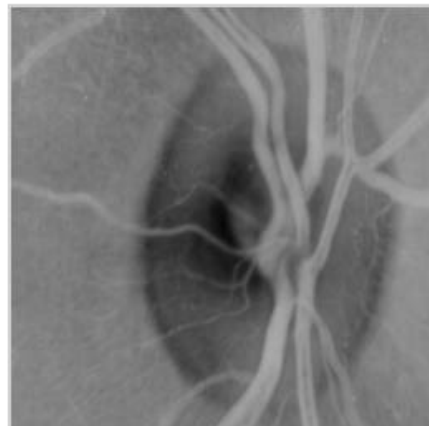


Fig. 1: Retinal image

location of the optic disc is of critical importance in retinal image analysis and is required as a prerequisite stage of exudates detection.

MATERIALS AND METHODS

Detection methods of optic disk: The Optic Disc (OD) is the exit point of retinal nerve fibers from the eye and the entrance and exit point for retinal blood vessels. It is a brighter region than the rest of the ocular funds and its shape is approximately round. The location of the OD is crucial in retinal image analysis, for example, as a reference to measure distances and identifies anatomical parts in retinal images (e.g., the fovea), for blood vessel tracking and many others. Precise localization of optic disk

boundary is an important sub problem of higher level problems in ophthalmic image processing. Specifically, in proliferate diabetic retinopathy; fragile vessels are developed in the retina, largely in the OD region, in response to circulation problems created during earlier stages of the disease.

Clustering and PCA method: The intensity of optic disc is much higher than the surrounding retinal background. A common method of optic disc localization is to find the largest cluster of pixels with the highest gray level. A simple clustering method (Li and Chutatape, 2001) is applied on the intensity image to find the candidate regions where the optic disc may appear and Principal Component Analysis (PCA) is applied only on these candidate regions to locate the optic disc. This method is applied with the presence of large area of light lesions.

PCA and active shape model: Principal Component Analysis (PCA) is applied to the candidate regions at various scales to locate the optic disc. The minimum distance between the original retinal image and its projection onto disk spaces indicates the center of the optic disc. The shape of optic disc is obtained by an active shape method, in which affine transformation (Huiqi and Chutatape, 2003) is used to transform the shape model from shape space to image space. The effects of vessels present inside and around optic disc are not eliminated, but also incorporated in the processing. This algorithm takes advantage of top-down strategy that can achieve more robust results especially with the presence of large areas of light lesions and when the edge of the optic disc is partly occluded by vessels.

Contour detection using ellipse fitting and wavelet transform: The contours are usually represented by image edges and image features consisting of points where the image intensity function varies sharply. It is crucial for the precise identification of the macula to enable successful grading of macular pathology such as diabetic maculopathy. However, the extreme variation of intensity features within the optic disc and intensity variations close to the optic disc boundary presents a major obstacle in automated optic disc detection. The presence of blood vessels, crescents and peripapillary chorioretinal atrophy seen in myopic patients also increase the complexity of detection. A novel algorithm is used to detect the optic disc based on wavelet processing and ellipse fitting. Daubechies wavelet transform (Pallawala *et al.*, 2004) is used to approximate the optic disc region. Next, an abstract representation of the optic disc is obtained using an intensity-based template. This yields robust results in cases where the optic disc

intensity is highly non-homogenous. Ellipse fitting algorithm is then utilized to detect the optic disc contour from this abstract representation. Additional wavelet processing is performed on the more complex cases to improve the contour detection rate.

Sobel edge detection and least square regression: The Optic disk can be seen as a pale, well defined round or vertically slightly oval disk. The detection is performed in the red component in 3 steps: candidate area identification, sobel edge detection and estimation step. The candidate area is identified and a clustering algorithm (Li and Chutatape, 2000) is applied to assemble nearby pixels into clusters. The gravity center of the largest cluster is defined as the center of the candidate area. Sobel edge detector is applied to the candidate area to get the contour of optic disc. It is not satisfied because of noises. Hence, LSR (Least Square Regression) is applied to get the estimated circle, based on Sobel edge detector. Another method uses texture descriptors (Lupascu *et al.*, 2008) and a regression based method in order to determine the best circle that fits the optic disc. The best circle is chosen from a set of circles determined by the method.

Lab colour morphology: The location of the optic disc is of critical importance in retinal image analysis was by both the automatic initialization of the snake (Osareh *et al.*, 2002a-c) and the application of morphology in color space. Previously OD was focused on locating its center (Sinthanayothin *et al.*, 1999). The interference of blood vessels is removed by dilation and erosion restores the boundaries. Standard gray level morphology was performed after a transformation of the RGB color image into the gray level image. By fitting the snake onto the optic disc, the performance can be measured for various morphological methodologies. The initial contour for snake must be close to the disk boundary otherwise it can converge to the wrong place. The accuracy obtained was 90%.

Simulated annealing optimization: The method is based on the preliminary detection of the main retinal vessels by means of a vessel tracking procedure. All retinal vessels originate from the optic disc and then follow a parabolic course towards retinal edges. A geometrical parametric model (Ruggeri *et al.*, 2003) was proposed to describe the direction of these vessels and 2 of the model parameters are just the coordinates of the optic disc center. Using samples of vessels directions (extracted from fundus images by the tracking procedure) as experimental data, model parameters were identified by means of a simulated annealing optimization technique. These estimated values provide the coordinates of the center of optic disc.

Circular hough transform and local variance: The green band of the images was processed as it was found that these images had the greatest contrast between the optic disk and the retinal tissue. Firstly, the blood vessels in the image were suppressed by morphological methods (closing). Then 24 radial vectors were defined using the approximate centre of the optic disk as the origin. The image was resampled along these vectors to form a representation that was subsequently processed.

The image was firstly enhanced using the Sobel operator and then threshold using the local mean and variance to compute the threshold value. The remaining points were input to a circular Hough transform (Abdel-Ghafara *et al.*, 2004) the largest circle was found consistently to correspond to the optic disk. The success rate is only 65%. This method separates the normal and abnormal images due to glaucoma. The optic disc appearance is uniform in normal images but progressively less as the disease progresses. Chanwimaluang and Guoliang (2003) suggested 2 steps.

The approximate center of optic disc is located using maximum of the local variance and the boundary is delineated by fitting the active snake. The local variance can indicate the intensity variation of OD, which is related to blood vessel and small structures inside the OD. The large variance, the more snake points should be used to overcome the disturbing gradient from blood vessel and/or intensity variations. The more anatomical constraints were not involved.

Histogram equalisation and dynamic contour: The retinal image was enhanced using histogram equalization. Preprocessing was achieved by applying a pyramid edge detector to the contrast enhanced image. Pixels in a layer of the pyramid data structure was computed as the average of groups of 4 pixels and this averaging prevents future examination of the spurious edge points arising from noise. Edge strength was used to fit snake to the disc boundary. The cholesky algorithm (Morris, 1999) was used. But here the snake had failed to locate the boundary in the upper right quadrant.

Texture based method: A random of 23 images was chosen for training and other 23 for testing. In the training step, 3 blocks containing the 1% were collected from each image, which accounted for 69 blocks and used as the training set. The weighted function was defined by linearly combining 3 regression lines obtained by fitting 3 pairs of statistic parametric (Chu *et al.*, 2005) relations, which were used to precisely detect the optic disc regions

and this can effectively eliminate the incorrect optic disk detection caused by extending bright areas around the optic disk. Optic disc localization was also achieved by iterative threshold method to identify initial set of candidate regions followed by connected component analysis (Siddalingaswamy and Prabhu, 2007) to locate the actual optic disc.

Pyramidal approach: The optic disk tracking is done by pyramidal decomposition (Gagnon *et al.*, 2001) and OD contour search technique based on the Hausdorff distance. The global OD region was found by means of a multi-scale analysis (pyramidal approach) using a simple Haar-based wavelet transforms. The brightest pixel that appears in a coarse resolution image (at an appropriate resolution level depending on the initial image resolution and the OD average dimension) is assumed to be part of the OD. This global OD localization serves as the starting point for a more accurate OD localization obtained from a template-based matching that uses the Hausdorff distance measure on a binary image of the most intense Canny edges. An average error of 7% on OD center positioning is reached with no false detection. In addition, a confidence level is associated to the final detection that indicates the level of difficulty the detector has to identify the OD position and shape. Genetic based detection (Abraham *et al.*, 2006) was involved in the preprocessing stage having pixels with the highest 2% gray levels. Simple clustering mechanism and optic disc diameter are considered to determine the candidate region and optic disc center. Genetic algorithm explores the combinatory space of possible contours (solutions) by means of crossover and mutation, followed by the evaluation of fitness and the selection of a new set of contours. The cumulative local gradient is used as a fitness function to find the fittest contour.

Topological Active Nets (TAN): Lalonde *et al.* (2000) extracted the optic disc using Hausdorff based template matching and pyramidal decomposition. It is neither sufficiently sensitive nor specific enough for clinical application. An average error of 7% on OD center positioning was reached with no false detection. In addition, a confidence level was associated to the final detection that indicates the level of difficulty the detector had to identify the OD position and shape. Chrastek *et al.* (2002) used an automated method for the optic disc segmentation, which consists of 4 steps: localization of the optic disc, nonlinear filtering, canny edge detector and Hough transform. The nonlinear filtering was used as a method for noise reduction, which at the same time preserve the edges. Since, the optic disc

is a circular structure, the authors used the Hough transform in order to have a method of circle detection. The transform give them the center and radius of a circle approximating the border of the optic disc. A new approach to the optic disc segmentation process was proposed by Novo *et al.* (2008) in digital retinal images by means of Topological Active Nets (TAN). This is a deformable model used for image segmentation that integrates features of region-based and edge-based segmentation techniques, being able to fit the edges of the objects and model their inner topology. The optimization of the active nets is performed by a genetic algorithm, with adapted or new ad hoc genetic operators to the problem. The active nets incorporate new energy terms for the optic disc segmentations, without the need of any pre-processing of the images.

Detection of exudates

Support vector machines and neural networks:

Osareh *et al.* (2002a-c) used Gaussian-smoothed histogram analysis and Fuzzy C means clustering to segment candidate exudates region and SVM and neural network classifies the exudates and non exudates. Support vector machine uses SRM approach. For separate classification, a kernel function is used where a separating hyper plane (w, b) with w as the weight and b as the bias is used which maximizes the margin or distance from the closest points. The optimum separating hyper plane based on the kernel is:

$$F(x) = \text{Sign} \left(\sum \alpha_i y_i k_{i-1}(x, x_i) + b \right) \quad (1)$$

where:

- n = The number of training examples
- y_i = The label value of i, k is the kernel
- α_i = The coefficient to maximize the lagrangian representation

Optimum hyper plane is defined by y_i (w. x_i +b) ≥ 1-ξ_i, ξ_i ≥ 0. This can achieve a trade off between false positives and false negatives using asymmetric soft margin and they converge to solution regardless of initial condition and remove the danger of over fitting.

Bayesian statistical classifier: Wang *et al.* (2000) applied Bayesian statistical classifier based on colour features to differentiate the yellowish lesions. It combines brightness adjustment procedure with statistical classification method and local window based verification strategy. Objects in an image can be described in terms of features such as colour, size, shape, texture and other complex characteristics. Different objects are classified into corresponding clusters by the rules. This detects the

lesions correctly but misclassifies the optic disk due to the similarity in colour. The presence of lesions can be preliminarily detected using MDD (Maximal Dependence Decomposition) and brightness adjustment procedure solves the non uniform illumination problem. The accuracy is 70% in classifying the normal images. They did not measure accurately to distinguish exudates among other lesions. The exudates identified exudates in gray level images based on a recursive region growing technique. Gardner *et al.* (2002) used a neural network to identify the exudate lesions in gray level images. A neural network was trained to recognize features of diabetic fundus images and tested for sensitivity and specificity. The network can be used to identify the presence of vessels, exudates and hemorrhages with high predictive value. Back propagation neural network was employed to analyse images using grids. The network was then tested from the previously seen training data and the unseen test data. Neural network determination of retinopathy for a whole image was based on the statistical threshold and some squares in the grid may be missed. By altering the threshold, it is possible to change the networks detection rate to increase the sensitivity and this leads to a lower specificity. The network training took 2-3 weeks, whereas, this requires about an hour. We can also increase our sensitivity and specificity results by changing the threshold on the network output. This approach is weakened since not all of the exudates region may appear within a square pach.

Fuzzy C-means clustering and morphological methods:

Sopharak and Uyyanonvara (2007a, b) transformed Red, Green and Blue (RGB) space to Hue, Saturation and Intensity (HSI) space. A median filtering operation was applied to reduce noise before a Contrast-Limited Adaptive Histogram Equalization (CLAHE) was applied for contrast enhancement. CLAHE operates on small regions in the image. Each small region's contrast is enhanced with histogram equalization. FCM is used for segmentation and the fine segmentation using morphological reconstruction. The algorithm still has some false detection because some pixels with similar colour to the exudates belong to optic disc and edge of blood vessel. Candidate exudates were detected using a multi-scale morphological process (Alan *et al.*, 2007). Based on local properties, the likelihoods of a candidate being a member of classes exudate, drusen or background were determined. This leads to a likelihood of the image containing exudates, which can be thresholded to create a binary decision. Wasif *et al.* (2008) used green component of the image and preprocessing steps such as average filtering, contrast adjustment and thresholding.

The other processing techniques used are morphological opening, extended maxima operator, minima imposition and watershed transformation. The algorithm was evaluated using the test images with fixed and variable thresholds.

RESULTS AND DISCUSSION

Region growing and edge detection: Principal component analysis (Li and Chutatape, 2003) was employed to locate optic disk; A modified active shape model was proposed in the shape detection of optic disk; A fundus coordinate system was established to provide a better description of the features in the retinal images; exudates are detected by the combined region growing and edge detection approaches. LUV is selected as the suitable color space for the exudates detection. The fundus image is divided into 64 sub images. Detection is done in each sub image. The color difference of the object can be defined as:

$$D(I, j) = \sqrt{(L(i, j) - L_r)^2 + (U(i, j) - U_r)^2} \quad (2)$$

$L(I, j), U(i, j)$ = The colors of pixel (I, j) in the component L and U, respectively
 L_r, U_r = The reference colors of the object

The reference color is determined as the gravity center of the object. Mean squared Wiener filter removes the noise. A combined method of region growing and edge detection, which includes seed selection, edge detection and growing criteria was employed to detect the exudates. Edges in the sub images were detected by the canny edge detector. Specificity obtained was low.

Recursive region growing segmentation: An automated screening system (Sinthanayothin *et al.*, 2002) to analyse the features of Non-Proliferative Diabetic Retinopathy (NPDR) includes recursive region growing segmentation algorithms combined with the use of a new technique, termed a Moat Operator, were used to automatically detect features of NPDR. These features included Haemorrhages and Microaneurysms (HMA), which were treated as 1 group and hard exudates as another group. This study presents, encouraging results in automatic identification of important features of NPDR.

K nearest neighbour and neural network: Screening to detect retinopathy disease can lead to successful treatments in preventing visual loss. Intraretinal fatty (hard) exudates are a visible sign of diabetic retinopathy and also a marker for the presence of co-existent retinal oedema. The retinal images were automatically analysed

in terms of pixel resolution and image-based diagnostic accuracies and an assessment of the level of retinopathy was derived. To estimate the exudates and non-exudates probability density distributions, K nearest neighbour, Gaussian quadratic and Gaussian mixture model classifiers were utilized. This includes colour image segmentation and region-level classification based on neural network and support vector machine classifier models. A sliding windowing technique Schaefer and Leung (2007) also used to extract parts of the image which were then passed to the neural network to classify whether that area was a part of exudates region or not. PCA and histogram specifications were used to reduce training times and complexity of the network and to improve the classification rate.

Fuzzy C-means clustering and neural network: The detection of exudates regions was done using image color normalisation, enhancing the contrast between the objects and background, segmenting the color retinal image (Osareh *et al.*, 2001). The exudates and non exudates patches were determined by a neural network. The color normalisation was done using histogram specification. Local contrast enhancement improves both the contrasting attributes of lesions and the overall color saturation in an image. Along with this FCM, clustering highlights the salient regions and extracts relevant features and finally classifies the exudates using perceptron neural network. This was performed on the intensity channel of the image after it was converted to the HIS color space. The optic disk is segmented as fragmented EX regions due to the similarity of its color to yellowish EX regions. The false detected optic disk regions were ignored. The segmented objects were classified as EX/nonEX regions by a neural network.

Intelligent system: Image contrast is enhanced by means of a neurofuzzy subsystem where fuzzy rules are implemented using Hopfield type neural network (Carnimeo and Giaquinto, 2006). This is developed to behave as a fuzzy system to highlight pale regions in the fundus images of patients. Multilayer perceptron neural network is trained for evaluating the optimal global threshold, which can minimize pixel classification errors. The performances were compared with the algorithms like Gradient decent backpropagation, gradient descent momentum with adaptive learning rate, conjugate gradient backpropagation with fletcher reeves updates and Levenberg-Marquardt backpropagation. The globally optimal segmentation generates binary images, which contain only significant information about suspect damaged retinal areas.

Adaptive multiscale morphological processing: The diabetic retinopathy related spot lesions of various sizes and shapes are accomplished by an adaptive multiscale morphological processing technique (Zhang and Fan, 2006). Local minima are the reference points to determine the proper scale for dark lesions and 2-sided edge model was used to define the lesion area. Segmentation of dark and bright lesions was obtained by using entropy based thresholding techniques. The limitation is that lesion validation may remove some dark lesions that are connected with blood vessels.

Machine learning based automated system: A machine learning based automated system (Niemeijer *et al.*, 2007) capable of detecting exudates and cottonwool spots and differentiates them using statistical classifier. Each pixel was classified and lesion probability map indicates the probability that a pixel was a part of a bright lesion. Pixels with high probability were grouped in to clusters. The classifier differentiates the different types of pixels or clusters based on the so called features or numerical characteristics such as pixel color or cluster area. This gave outputs whether bright lesions were present or not and which class each lesion was. The bright lesions may be missed by human experts and the automated system because of the limitations of the digital 2 field non stereo photography. Secondly, there could be a constraint of the quality of annotations of the training image. A large number of training pixels may improve the system performance. Retinal thickening, if present, will be missed by the algorithm. The testing can be done on a small number of patients.

Contextual clustering and fuzzy art neural network: There was an extensive dissimilarity in the color from different patients owing to intrinsic attribute of lesions, decreasing color dispersion at the lesion periphery and lighting disparity, which results in color of lesion of some images lighter than the background color. Jayakumari and Santhanam (2007) applied Histogram equalization independently for each RGB channel followed by enhancement. The contrast enhancement algorithm not only enhances the brightness of lesions but also augments the brightness of the surrounding pixels so that these may be recognized as class lesion. The segmented images are discriminated to locate the hard exudates using features such as convex area, solidity and orientation. The exudates were detected with 93.4% sensitivity and 80% specificity. This cannot detect soft exudates.

CONCLUSION

The importance for optic disk and exudate detection methods lies in detecting early stages of diabetic retinopathy. Even though some methods in optic disk detection have acceptable accuracy there may be some false location of the disk due to noises and other parameters. A method for the efficient detection of optic disk irrespective of the intensity variations near the boundary will give better result. Similarly the intensity of exudates are sometimes close the optic disk intensity. This study gives the different approaches for optic disk and exudates detection in retinal images.

ACKNOWLEDGEMENT

Our sincere thanks to Dr. K. Sankaranarayanan, Dean, Electrical Sciences, VLB Janakiammal College of Engineering and Technology for his suggestions and guidance.

REFERENCES

- Abdel-Ghafara, R.A., T. Morriss, T. Ritchingsb and I. Woods, 2004. Detection and characterisation of the optic disk in glaucoma and diabetic retinopathy. Proc. Int. Conf. Med. Image, 32 (1): 19-25.
- Abraham, D., V. Chandy and V. Kumari, 2006. Genetic Algorithm Based Location of Optic Disc in Retinal Images. Academic OpenInternet J., Vol. 17, Part 6/P5.
- Alan, D.F., S.P.K. Goatman, G.J. Williams, J.A. Olson and P.F. Sharp, 2007. Automated detection of exudates for diabetic retinopathy screening. Phys. Med. Biol., 52: 7385-7396.
- Carnimeo, L. and A. Giaquinto, 2006. An intelligent system for improving detection of diabetic symptoms in retinal images. www.medlab.cs.uoi.gr/itab2006/proceedings/IntelligentSystems.
- Chr'astek, R.W., M. Donath, K. Michelson and G.H. Niemann, 2002. Optic Disc Segmentation in Retinal Images. In Bildverar beitung fur die Medizin, pp: 263-266. ISBN: 3540432256.
- Chu, Y.P., S.F. Yang-Mao, Y.F. Chan, C.S. Tsai and W.C. Chiang, 2005. Optic disk locating of the Retinal Fundus Images using Simple Statistic Parameters. Proc. (458) Biomed. Eng. Innsbruck, Austria, pp: 16-18. ISBN: 0-88986.476.4.
- Gagnon, L., M. Lalonde, M. Beaulieu and M.C. Boucher, 2001. Procedure to detect anatomical structures in optical fundus images. Proc. Conf. Med. Imaging Image Processing SPIE, pp: 1218-1225.

- Gardner, G., D. Keating, T. Williamson and A. Elliott, 2002. Automatic detection of diabetic retinopathy using an ANN: A Screening Tool. *Br. J. Ophthalmol.*, 80: 940-944. DOI: 10.1136/bjo.80.11.940.
- Jayakumari, C. and T. Santhanam, 2007. Detection of hard exudates for diabetic retinopathy using contextual clustering and fuzzy art neural network. *Asian J. Inform. Technol.*, 6 (8): 842-846.
- Lalonde, M., M. Beaulieu and L. Gagnon, 2001. Fast and robust optic disk detection using pyramidal decomposition and Hausdorff-based template matching. *IEEE. Trans. Med. Imag.*, 20 (11): 1193-1200. DOI: 10.1109/42.963823. INSPEC: 7094337.
- Li, H. and O. Chutatape, 2000. Fundus image features extraction. *Proc. 22nd Ann. Int. Conf. IEEE. Eng. Med. Biol. Soc.*, 4: 3071-3073. ISBN: 0-7803-6465-1. DOI: 10.1109/IEMBS.2000.901530. INSPEC: 7011416.
- Li, H. and O. Chutatape, 2001. Automatic Location of Optic Disc in Retinal images. *Int. Conf. Image Processing. IEEE ICIP*, pp: 837-840 Issue, 7-10. DOI: 10.1109/icp.2001.958624.
- Li, H. and O. Chutatape, 2003. A model-based approach for automated feature extraction in fundus images. *9th IEEE Int. Conf. Comp. Vision*, 1: 394-399. DOI: 10.1109/ICCV.2003.1238371.
- Lupascu, C.A., D. Tegolo and L. Di Rosa, 2008. Automated detection of optic disc location in retinal images. *Computer-based medical systems. 21st IEEE Int. Symp.*, 17-19: 17-22. DOI: 10.1109/CBMS.2008.15.
- Morris, D.T., 1999. Identifying the neuroretinal rim boundary using dynamic contours. *Image Vision Comput.*, 17 (3-4): 169-174.
- Niemeijer, M., B.V. Ginneken, S.R. Russell, S. Maria, A. Suttrop-Schulten and M.D. Abramoff, 2007. Automated detection and differentiation of drusen, exudates and cotton-wool spots in digital color fundus photographs for diabetic retinopathy diagnosis. *Investigative Ophthalmol. Visual Sci.*, 48: 2260-2267. DOI: 10.1167/iovs.06-0996.
- Novo, J., M.G. Penedo and J. Santos, 2008. Optic disc segmentation by means of GA-optimized topological active nets. *Image Anal. Recogn.*, 5112: 807-816. DOI: 10.1007/978-3-540-69812-8_80. PMID: 807-816.
- Osareh, A., M. Mirmehdi, B. Thomas and R. Markham, 2002b. Comparison of colour spaces for optic disc Localization in Retinal Images. *IEEE. Comput. Soc.*, 1: 743-746.
- Osareh, A., M. Mirmehdi, B. Thomas and R. Markham, 2001. Automatic recognition of exudative maculopathy using fuzzy C-means clustering and neural networks. Department of Computer Science, University of Bristol. *Proceedings of Medical Image Understanding and Analysis*, pp: 49-52. citeseer.ist.psu.edu.
- Osareh, A., M. Mirmehdi, B. Thomas and R. Markham., 2002a. Color morphology and snakes for optic disc localization. *The 6th Medical Image Understanding and Analysis Conference, University of Bristol*, pp: 21-24. DOI: 10[1].1.1.19.3703.
- Osareh, A., M. Mirmehdi, B. Thomas and R. Markham, 2002c. Comparative Exudate Classification Using Support Vector Machine and Neural Networks. *Med. Image Comput. Computer Assisted Intervention*, 2489: 413-420. DOI: 10.1007/3.540-45787-9.
- Pallawala, P.M.D.S., W. Hsu, M.L. Lee and K.G.A. Eong, 2004. Automated optic disc localization and contour detection using ellipse fitting and wavelet transform. *8th Eur. Conf. Computer Vision, Prague, Czech Republic*, pp: 139-151. DOI: 10.1007/b97-866.
- Ruggeri, A., M. Forrachia and E. Grisan, 2003. Detecting the optic disc in retinal images by means of a geometrical model of vessel by network. *Proc. 25th Ann. Int. Conf. IEEE Eng. Med. Biol. Soc.*, 1 (17-21): 902-905. DOI: 10.1109/IEMBS.2003.1279911.
- Schaefer, G. and E. Leung, 2007. Neural Networks for Exudate Detection in Retinal Images. *Adv. Visual Comput.*, 4842: 298-306.
- Siddalingaswamy, P.C. and G.K. Prabhu, 2007. Automated detection of anatomical structures in retinal images. *Conf. Comput. Intellig. Multimed. Appl.*, 3 (13-15): 164-168. ISBN: 0-7695-3050-8. INSPEC: 9895472. DOI: 10.1109/ICCIMA.2007.94.
- Sinthanayothin, C., J.F. Boyce, T.H. Williamson, H.L. Cook, E. Mensah S. Lal and D. Usher, 2002. Automated detection of diabetic retinopathy on digital fundus images. *Diabetic Med.*, 19 (2): 105-112. DOI: 10.1046/j.1464-5491.2002.00613.
- Sinthanayothin, C., J. Boyce and C.T. Williamson, 1999. Automated localisation of the optic disk, fovea and retinal blood vessels from digital colour fundus images. *Br. J. Ophthalmol.*, 83: 902-910. DOI: 10.1136/bjo.83.8.902.
- Sopharak, A. and B. Uyyanonvara, 2007a. Automatic exudates detection from diabetic retinopathy retinal image using fuzzy C-means and morphological methods. *Proc. Int. Conf. Adv. Comput. Sci. Technol. Phuket, Thailand*. ISBN: 978-0-88986-656-0.

- Sopharak, A. and B. Uyyanonvara, 2007b. Automatic Exudates Detection from non-dilated diabetic retinopathy retinal image using Fuzzy C-means clustering. WACBE World Congress on Bioengineering July 9-11. Bangkok, Thailand, www.siiit.tu.ac.th/bunyarit/publications/2007.
- Wang, H., W. Hsu, K. Goh and M. Lee, 2000. An effective approach to detect lesions in colour retinal images. IEEE Conf. Comput. Vision Pattern Recognit., 2: 181-186. ISBN: 0-7695-0662-3. INSPEC: 6651776. DOI: 10.1109/CVPR.2000.854775.
- Wasif, A.R., C. Eswaran and S. Hati, 2008. Automatic tracing of optic disc and exudates from color fundus images using fixed and variable thresholds. J. Med. Syst., 33 (1): 73-80. DOI: 10.1007/s10916-008-9166-4.
- Zhang, X. and G. Fan, 2006. Retinal spot lesion detection using adaptive multi scale morphological processing. School of Electrical and Computer Engineering, Oklahoma State University, Stillwater, OK74078. Int. Symposium Visual Comput., No. 2, Lake Tahoe NV, ETATS-UNIS, 4292: 490-501. DOI: 10.1007/11919629_50.