

Acute-Toxicity of Sodium Chloride (NaCl) on *Oreochromis niloticus* Fingerlings

T. Jegede

Department of Forestry, Wildlife and Fisheries, University of Ado Ekiti,
P.M.B 5363, Ado Ekiti, Nigeria

Abstract: A static bioassay was conducted to determine the 96h LC50 of NaCl to *Oreochromis niloticus* fingerlings (11.58 ± 0.13 g) and to describe the histological changes in the gill, heart and kidney. LC50 of *O. niloticus* fingerlings was determined graphically as 11.33ppt. The fish showed increase hyperactivity exemplified by erratic movement, loss of reflex and hyperventilation during 96 h exposure. Histological examination revealed that gill architecture was destroyed and gill lamellae were fused. The heart showed deformities including perforation and enlargement. The kidney was greatly deformed and discoloured.

Key words: Histological changes, *Oreochromis niloticus*, sodium chloride, toxicity

INTRODUCTION

The importance of the tilapias in aquaculture is evident from the fact that they have now spread to all continents of the world (Pullin, 1984). FAO (1998) reported that Nile tilapia (*Oreochromis niloticus*) is amongst the ten most cultured fish species in the world with total production of 201, 933 metric tonnes, amounting to about 3.4% as at 1990. The realization of the above attributes, coupled with increase in the level of advancement in fisheries has necessitated fish seed production. However, fish seed is still at the minimal production level in sub-Saharan Africa, as a result of parasite infestation causing considerable loss to the producer. Fish seeds are often destroyed by treatable diseases because of lack of adequate knowledge of appropriate chemical dosage.

Klinger and Floyd (2002) reported that a common mistake of fish culturists is misdiagnosing disease problems and treating their sick fish with the wrong medication or chemical. When the chemical doesn't work, they will try another, then another. Selecting the wrong treatment becomes detrimental to the fish than no treatment at all. Mitchel advised that the application of KMnO₄ is ideal in the early morning so that it can be observed throughout the day, to determine if additional application(s) will be necessary to retain the red wine colouration for 10-12 h.

Sodium chloride (NaCl, common salt) is used in aquaculture as an osmoregulatory enhancer. It has also been used effectively to control external parasitic protozoans such as leaches, fungus parasite, such as *Saprolegnia*, *Columnaries*, *Ichthyophthirius*, fin rot, virus infection, ulcers, bacterial infection, etc (Schnick *et al.*, 1998). Little work has been done to determine the

relationship between water quality and chemotherapeutics and their effects on fish. Maladministration of these compounds often results in danger or fish mortality. It is therefore imperative to determine the level at which a particular chemical/salt will become toxic to fish before administering treatment (bioassay). Therefore, this study is aimed at determining the effect NaCl on *O. niloticus* fingerlings.

MATERIALS AND METHODS

O. niloticus fingerlings (11.58 g±0.13) were obtained from a government fish farm and acclimated in glass tanks in the laboratory for seven days during which the fish were fed on a 35% crude protein commercial diet. Prior to the acute toxicity test, 20 *O. niloticus* fingerlings were used for range finding test. Toxicity test was conducted in glass tanks (75×40×40 cm; 60 L capacity). Two thirds of each tank was filled with water. Ten *O. niloticus* fingerlings (11.58±0.13 g) were stocked into each glass tank, with 2 replicates per treatment. The treatments were: Treatment 1, 16g NaCl L⁻¹ of water; Treatment 2, 17g NaCl L⁻¹ of water; Treatment 3, 18g NaCl L⁻¹ of water; Treatment 4, 19g NaCl L⁻¹ of water; Treatment 5, 20g NaCl L⁻¹ of water; Control 6, 0 g NaCl L⁻¹ of water.

Prior to the commencement of the experiment, the fish were starved for 2 days. This is to minimize the amount of waste in the test media and to prevent organic decomposition and oxygen depletion. The experiment was conducted under standard static bioassay condition. Temperature, pH, dissolved oxygen and conductivity level were determined using standard methods and readings were taken at 24 h interval for 96 h. At the end of the treatment period, two fish from each treatment tank

were removed, weighed on a Metler top-loading balance (Model P13 8001), killed by decapitation and vital organs such as the gill, heart and kidney were removed, fixed for 24 h in formalin-saline solution made of equal volumes of 10% formalin and 0.9% NaCl solution. Histological sections of 8N thickness were prepared following standard procedures (Chieli *et al.*, 1995) photomicrographs were taken with Leitz (Ortholux) microscope and camera.

RESULTS AND DISCUSSION

Median lethal level (LC50): There were significant losses of fish with increase in NaCl concentration ($p < 0.05$). The LC50 was recorded graphically at 11.33g NaCl L⁻¹ of water (Fig. 1).

Histological changes in some organs of tilapia fingerlings

Normal gill architecture was observed in fish from the control treatment. Both the lamellae and the gill filament visible with the gill filaments well separated from each other (Fig. 2). At high NaCl concentration, the normal gill architecture/structure had been destroyed. The gill lamellae were extensively fused together (Fig. 3). The

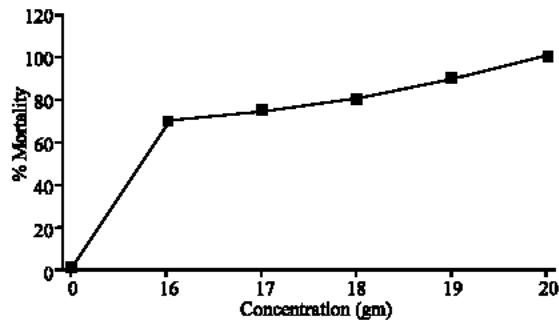


Fig. 1: Effect of sodium chloride on the fingerlings of *Oreochromis niloticus*

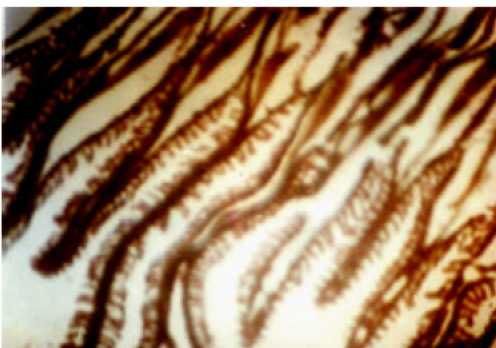

Fig. 2: Control experiment Gill

were heart of the fish from the control treatment showed normal structure. The shape and the colour of the heart were maintained and no visible alteration was noticed (Fig. 4). At high NaCl concentration, the heart was enlarged and a big hole was observed in heart (heart burst). Thick dark blood clots were scattered on the heart (Fig. 5). The shape and colour of kidney of fish from the control treatment were normal and no alteration was

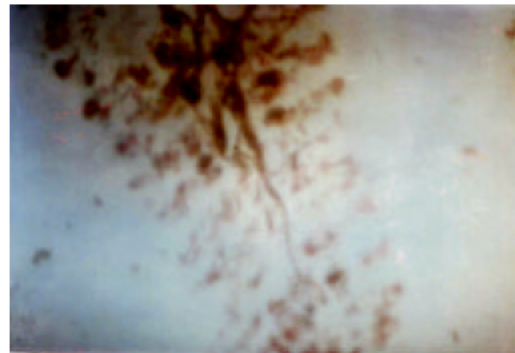


Fig. 3: Effect of sodium chloride on gill

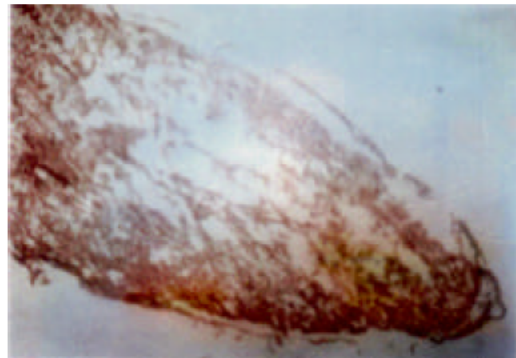


Fig. 4: Control experiment heart

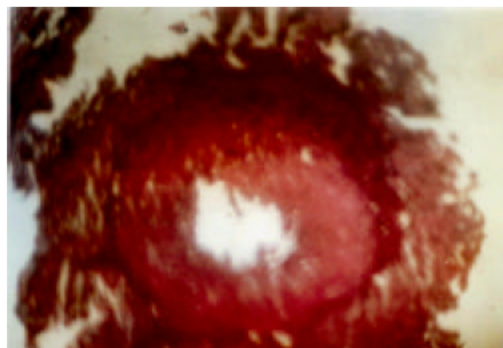

Fig. 5: Effect of sodium chloride on heart

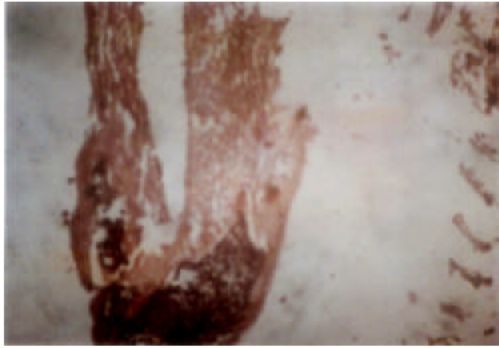

Fig. 6: Control experiment kidney

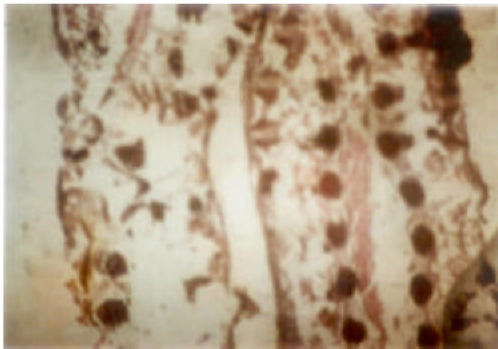


Fig. 7: Effect of sodium chloride on kidney

noticed (Fig. 6). At high NaCl concentration, the normal kidney shape/structure had been distorted. Thick black colourations were noticed at the tail end of the specimen (Fig. 7).

In this study, a relationship between the water quality and salinity was established. Increase in salinity led to a decrease in dissolved oxygen concentration in all tanks except those in the control treatment; and electrical conductivity increased progressively with increase in salinity; similar to the observations recorded by Boyd (1981). Furthermore, after 24 h of subjecting the fish to NaCl toxicity, the surviving fish were stationary (tropic movement), in most cases they converged at the edges of the tank. This observation was also reported made by Mitchell (1984) as swimming performances of fish were reduced by reduction oxygen uptake. Fishes that were subjected to NaCl toxicity test lost their escape reflex after 48 h, which was detected by knocking the walls of the tank and even attempting to touch the fishes inside each tank. This observation corroborated Woothon (1992) that healthy or unstressed fish are usually very timid and

if they are in or at great depth, they react to external agitations such as quick motion the water, a moving shadow or the surface, knocking on the transportation vessel or aquaria. However, the LC50 for *O. niloticus* subjected to NaCl toxicity was 11.33 ppt. This did not agree with Watanabe *et al.* (1985) who reported that fertilized eggs, fry and fingerlings of *O. niloticus* suffered 50% mortality within 96 h at between 15 and 20 ppt salinity. The variation in LC50 value in this study when compared with their results may be attributed to differences in size, sex or even experimental/environmental influence.

REFERENCES

- Boyd, C.E., 1981. Water quality in warmwater ponds. Agriculture Experimental Station, Auburn University, Alabama.
- Chieli, E., M. Saviozzi, T. Mc Wicagli Branca and P.G. Gervari, 1995. Hepatotoxicity and p-450 ZEL dependent metabolic oxidation of non-dimethylformamide in rats and mice. Arch. Toxicol. 69: 165-170.
- FAO, 1998. <http://www.fao.org/waicent/faoinfo/fishery/fishery.html>. Fisheries Statistics.
- Schnick, R.A., F.P. Meyer and D.L. Gray, 1998. A guide to approved chemicals in fish production and fishery resources management. Cornell University College of Veterinary Medicine. General Fish Medicine Homepage.
- Klinger, R. and R.H. Floyd, 2002. Introduction to fresh water fish parasites. CIR716 Series, Fisheries and Aquatic Science Department, Florida Cooperative Extension Service, Institute of Food Agricultural Science, University of Florida. Published by Fredrick J. Aldridge and Jerome V. Shireman, pp: 1-16.
- Pullin, R.S.V., 1984. Tilapia-potentially an international food commodity. Infofish Marketing Digest, 3/84: 35-36.
- Watanabe, W.O., C.M. Kuo and M.C. Huang, 1985. Salinity tolerance of Nile tilapia fry (*Oreochromis niloticus*), spawned and hatched at various salinities. Aquaculture, 48: 159-176.
- Woothon, R.J., 1992. Fish Ecol., pp: 1-93.
- Mitchell, A.J., 1984. Parasites and diseases of striped bass. In: J.P. McCraren (Ed.), The aquaculture of striped bass: A proceeding. UMSGMAP8401. University of Maryland, College Park, US., pp: 177-204.