

## Evaluation of the Serum Levels of Retinol in Patients Affected by Leukoplakia and Oral Lichen Planus: A Statistical Analysis

<sup>1</sup>G.A. Scardina, <sup>1</sup>A. Ruggieri, <sup>2</sup>F. Carini, <sup>1</sup>A. Cacioppo, <sup>2</sup>V. Valenza and <sup>1</sup>P. Messina

<sup>1</sup>Department of Oral Science, University of Palermo, Italy

<sup>2</sup>Department of Experimental Medicine, University of Palermo, Italy

**Abstract:** The aim of this study is the comparative evaluation of the serum levels of retinol in patients affected by leukoplakia and oral lichen planus. The study has been conducted through a statistical investigation with the purpose to underline possible variations of such levels, provided that meaningful, between the two groups. The retinol, an important molecule belonged to the family of retinoids, has an important anti-oxidant action and for this characteristic it can neutralize metabolic products (including reactive oxygen species), interfere with activation of procarcinogenes, prevent binding of carcinogens to DNA, inhibit chromosome aberrations, restrain replication of the transformed cell, suppress actions of cancer promoters and it may even induce regression of precancerous oral lesions. Leukoplakia and Oral Lichen Planus are oral precancer lesions with a greater potential of neoplastic malignant transformation that often show a strong subepithelial accumulation of inflammatory cells. Serum levels of retinol were estimated by the High Performance Liquid Chromatography (HPLC) method. Statistical analysis has been conducted with the Mann-Whitney U-test and we used P.A.S.T., ver. 1.53; a freeware developed by P.D. Ryan, D.A.T. Harper and J.S. Whalley in 1995 and up-to-date to the last version in September 2006. No significant differences were noticed in retinol serum levels in leukoplakia and oral lichen planus cases examined in this study. This result suggests that low serum retinol levels are not risk factors for occurrence of leukoplakia and oral lichen planus.

**Key words:** Leukoplakia, oral lichen planus, OLP, retinol, retinoids

### INTRODUCTION

The retinol an important molecule belonged to the family of the retinoids, has an important anti-oxidant action and for this characteristic it can neutralize metabolic products (including reactive oxygen species), interfere with activation of procarcinogenes, prevent binding of carcinogens to DNA, inhibit chromosome aberrations, restrain replication of the transformed cell, suppress actions of cancer promoters and it may even induce regression of precancer oral lesions (Enwonwu and Meeks, 1995). Leukoplakia and Oral Lichen Planus are oral precancer lesions with a greater potential of neoplastic malignant transformation and they, often, show a strong subepithelial accumulation of inflammatory cells (Njar *et al.*, 2006). Retinol serum value lowering could induce the reduction of its epithelium protective action and anti-oxidant effects. For these reasons, the study of the retinol serum level variations is important to establish if this value is a potential risk factor.

### MATERIALS AND METHODS

Thirty-three participants were recruited from patients at the University of Palermo (Italy). Eligibility requirements included age >18 years; presence of clinically and histologically documented oral leukoplakia and/or oral lichen planus; good general health; no history of malignancy; no prior high-dose vitamin A or retinoid therapy; willingness to have periodic photographs to document findings; ability to travel to appointments; and if female, not pregnant and using an appropriate contraceptive method. Serum levels of retinol were estimated by the High Performance Liquid Chromatography (HPLC) method. All participants signed an informed consent. Participants had medical, tobacco, alcohol, drug use and dietary histories taken. Oral examination was performed and clinical lesions were measured, photographed. Punch biopsies (4 mm) were taken from the lesion and from an uninvolved control site after infiltration with local anesthetic. Counseling and

education about the carcinogenic risks of tobacco and alcohol were discussed and subjects were offered referral to counseling and/or cessation programs.

**RESULTS**

The results of the investigation are reported in Table 1. The differences between the two groups statistically result not-meaningful. This is conforming to what reported by international literature.

**Statistical analysis:** The preferred test was the Mann-Whitney U test for ordinal, non-parametric data.

The computer support used was P.A.S.T. software v. 1.53, a freeware software developed in 1995 by P.D. Ryan, D.A. T. Harper and J.S. Whalley, updated to the latest version in September 2006. The results of the statistical analysis of the data, divided according to the parameters, are reported (Table 1 and 2).

Leukoplakia	Cases	P	Significance
Num.	17		
Mean±SD	0.83±0.37	0.055	NS

Lichen	Cases	P	Significance
Num.	16		
Mean±SD	0.56±0.23	0.117	NS

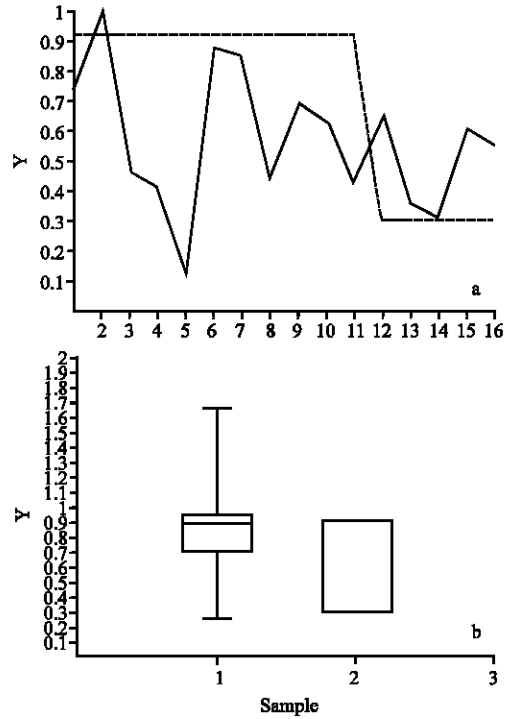


Fig. 2a, b: Box plot and graphical representation of OLP data

It can be deduced that, in both lichen and leukoplakia patients, the differences between the two groups are not statistically significant.

The graphical representation (Fig. 1 and 2) is reported.

**DISCUSSION**

The leukoplakia is one of the more frequent white lesions of the oral mucosa. It's observed about 3% of adults. It shows a clean preference for males with the exception of some geographical areas, for example India and Pakistan, where also in the women it finds a strong consumption of tobacco. It is observed especially in individuals above the 40 years with a peak of greater incidence around the 60 years. Such lesions are well known for their propensity for malignant transformation to the extent of 10-20% (Mishra *et al.*, 2005). The variability of these data obviously depends by numerous factors among which the studied populations, the risk factors in cause and the methodologies of search used. Oral lichen planus is a chronic inflammatory pathology (Thornhill, 2001) with autoimmune pathogenesis (Monaco *et al.*, 2004) which frequently involves the oral mucosa, either with the skin surface, or independently and precociously (Montebugnoli *et al.*, 2005). It affects about

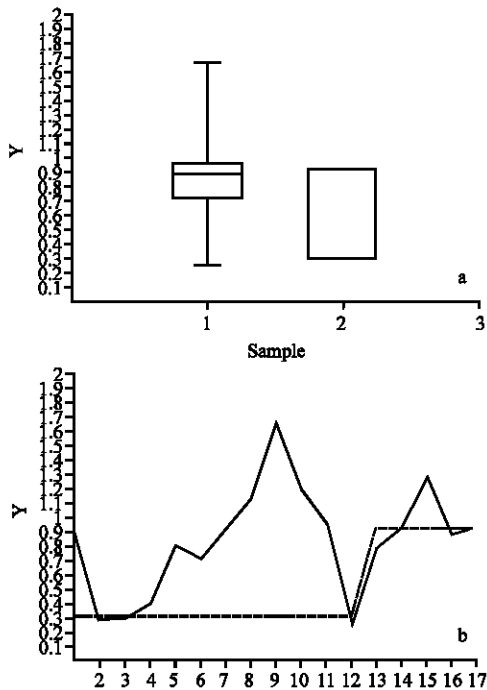


Fig. 1a, b: Box plot and graphical representation of leukoplakia data

0.5-2% of the global population (with an incidence varying according to the geographical location), mainly women; it begins at an average age between 40 and 50. Oral Lichen Planus (OLP) (Setterfield *et al.*, 2005) develops on the buccal mucosa in 60-70% of the cases. Most of the skin lesions are self-limiting, while oral lesions are chronic and rarely self-healing. The percentage of malignant evolution of lichen planus is currently controversial. From 1-1.5% of the patients are likely to undergo this evolution after 10 years. No specific risk factors have ever been identified; that has raised doubts about the evolutionary tendency of the disease and the factors which may contribute to the biological knowledge of this disease are particularly significant (Toru *et al.*, 2005).

Retinoids (vitamin A) are a very important group of molecules and they are crucial for most forms of life (Blomhoff and Blomhoff, 2005). In chordates, they have important roles in the developing nervous system and notochord and many other embryonic structures, as well as in maintenance of epithelial surfaces, immune competence and reproduction. The retinol intervenes in numerous biological mechanisms as the regulation of the epithelial differentiation. It directly acts on the immune system and on the mechanisms of the inflammation and it's considered as an chemopreventive agent for its influence on the apoptotic mechanisms and on the angiogenesis (Nagao *et al.*, 2000a-c, 2001). Experimental evidence suggests that retinoids affect gene expression both directly, by activating and/or repressing specific genes and indirectly, by interfering with different signal transduction pathways (Lippman *et al.*, 2006). Recently, a lot of molecules that belong to the family of the retinoids are employed both in the prevention and in the treatment of a lot of forms of cancer both for their function on the mechanisms of genic trasduction both for their ability of protection of the epithelia (Njar *et al.*, 2006). In lesions in which an evident variation in the epithelial layers is visible and that introduces, as the leukoplakia, a potential neoplastic transformation the use of the retinoids is important to maintain an acceptable epithelial state that doesn't favour the neoplastic progression but that rather repress it (Zanardi *et al.*, 2006). It's important to appraise if a lesion determined by a different cellular differentiation as the leukoplakia corresponds plasmatic levels altered of the vitamin A. For this reason we have conducted a study with the purpose to appraise such parameters and to determine if they are present meaningful variations of the level of the retinoids in the subjects affected by leukoplakia and oral lichen planus.

## CONCLUSION

In accord with the specific literature (Enwonwu and Meeks, 1995; Lippman *et al.*, 2006; Nagao *et al.*, 2000 b, 2001) we have not been picked a meaningful data that attests a meaningful variation of the serum levels of retinol in patients affected from leukoplakia respect normal parameters. This result suggests that low serum retinol levels are not risk factors for occurrence of leukoplakia and oral lichen planus.

## REFERENCES

- Blomhoff, R. and H.K. Blomhoff, 2006. Overview of retinoid metabolism and function. *J. Neurobiol.*, 66: 606-630.
- Enwonwu, C.O. and V.I. Meeks 1995. Bionutrition and oral cancer in humans. *Crit. Rev. Oral Biol. Med.*, 6: 5-17.
- Lippman, S.M., J.J. Lee, J.W. Martin, A.K. El-Naggar, X. Xu and D.M. Shin, 2006. Fenretinide Activity in Retinoid-Resistant Oral Leukoplakia. *Clin. Cancer Res.*, 12: 3109-3114.
- Montebugnoli, L., M. Foschini, C. Marchetti, A. Farnedi and A. Pession, 2005. Gestione del paziente affetto da manifestazioni lichenoidi. *Dental Cadmos*, 2: 3-25.
- Monaco, C., E. Andreakos, S. Kiriakidis and M. Feldman *et al.*, 2004. T-Cell-Mediated Signalling and Immune, Inflammatory and Processes: The Cascade of Events Leading to Inflammatory. *Curen Drug Targets-Inflammation and Allergy*, 3: 35-42.
- Mishra, M., J. Mohanty, S. Sengupta, S. Tripathy, 2005. Epidemiological and clinicopathological study of oral leukoplakia. *Indian J. Dermatol. Venereol. Leprol.*, 71: 161-165.
- Nagao, T., N. Ikeda and H. Fukano *et al.*, 2000a. Serum carotenoid levels in oral cancer and precancer in Japanese. *J. Pathol.*, 190: 56A.
- Nagao, T., N. Ikeda, S. Warnakulasuriya, H. Fukano, H. Yuasa, M. Yano, H. Miyazaki and Y. Ito, 2001b. Serum antioxidant micronutrients and the risk of oral leukoplakia among Japanese. *Oral. Oncol.*, 36: 466-470.
- Nagao, T., N. Ikeda, S. Warnakulasuriya, H. Fukano, H. Yuasa, M. Yano, H. Miyazaki and Y. Ito, 2000c. Outcome following a population screening programme for oral cancer and precancer in Japane. *Eur. J. Cancer B. Oral Oncol.*, 36: 340-346.
- Nagao, T., S. Warnakulasuriya, N. Ikeda, H. Fukano, S. Yamamoto, M. Yano, H. Miyazaki and Y. Ito, 2001. Serum antioxidant micronutrient levels in oral lichen planus. *J. Oral Pathol. Med.*, 30: 264-267.

- Njar, V.C., L. Gediya, P. Purushottamachar, P. Chopra, T.S. Vasaitis, A. Khandelwal, J. Mehta, C. Huynh, A. Belosay and J. Patel., 2006. Retinoic Acid Metabolism Blocking Agents (RAMBAs) for treatment of cancer and dermatological diseases. *Bioorg. Med. Chem.*, 9: 4323-4340.
- Setterfield, J.F., M.M. Black and S.J. Challacombe, 2000. The management of oral lichen planus. *Clin. Exp. Dermatol.*, pp: 25.
- Thornhill, M.H., 2001. Immune mechanisms in oral lichen planus. *Acta Odontol. Scand.*, 59: 174-177.
- Toru, N., N. Ikeda, H. Fukano, S. Hashimoto, K. Shimozato, and S. Warnakulasuriya, 2005. Incidence rates for oral leukoplakia and lichen planus in a Japanese population. *J. Oral Pathol. Med.*, 34: 532-539.
- Zanardi, S., D. Serrano, A. Argusti, M. Barile, M. Puntoni and A. Decensi, 2006. Clinical trials with retinoids for breast cancer chemoprevention. *Endocr. Relat. Cancer*, 13: 51-68.