

## Oral Manifestation of Kawasaki Disease

<sup>1</sup>G.A. Scardina, <sup>2</sup>F. Carini, <sup>2</sup>V. Valenza, <sup>1</sup>P. Messina and <sup>3</sup>E. Maresi

<sup>1</sup>Department of Oral Science, University of Palermo, Italy

<sup>2</sup>Section of Human Anatomy, Department of Experimental Medicine, University of Palermo, Italy

<sup>3</sup>Department of Pathological Anatomy, University of Palermo, Italy

**Abstract:** Kawasaki Disease (KD) is an acute systemic vasculitis, predominately affecting children under 5 years of age. KD is characterized by fever, bilateral non-exudative conjunctivitis, erythema of lip and oral mucosa, cervical lymphadenopathy, changes in the extremities and polymorphous exanthema. The major sequelae of KD are related to the cardiovascular system, especially the coronary arteries. This study analyzed the anatomical-pathological substrata of oral mucositis in one baby affected by KD.

**Key words:** Kawasaki disease, oral mucositis, vasculitis, lymphadenopathy, polymorphous exanthema

### INTRODUCTION

Kawasaki Disease (KD) is an acute systemic vasculitis which mainly involves medium calibre arteries; its origin is unknown and it affects children under the age of 5 (Maresi *et al.*, 2001; Limbach and Lindinger, 1991; Rubin and Cotton, 1998; Hamashima *et al.*, 1983; Fukushige *et al.*, 1994).

Today, KD diagnosis is formulated on the basis of a combination of distinctive clinical aspects (*diagnostic criteria*) and laboratory data (Maresi *et al.*, 2001).

The diagnostic criteria include: Feverish state, which lasts at least 5 days and does not disappear with the usual antipyretic drugs; polymorphous rash; conjunctival congestion; oropharyngeal mucositis (erythematous and cracked lips, strawberry tongue, pharyngeal erythema); periungual erythema, swelling and peeling on upper and lower limbs, laterocervical lymphadenitis (Kato *et al.*, 1994). These aspects can be associated to irritability, meningism, diarrhoea, hepatitis, hydrops of gallbladder, urethritis, otitis media and arthritis (Maresi *et al.*, 2001).

The cardiac involvement, in the forms of myocarditis, pericarditis, coronal aneurysms, valvular failure, etc., is always present-even though in the latent form in some cases-and it is responsible for the decease from occlusive thrombosis of the typical vasculitic coronal aneurysms, which often occurs during the convalescence stage of the disease (Maresi *et al.*, 2001; Amano *et al.*, 1979; Balz *et al.*, 1998).

This study analyzed the pathological substrata of oral mucositis in a baby affected by Kawasaki disease and suddenly deceased for cardiac tamponade caused by coronary aneurysm rupture (sudden cardiac death of a mechanical type).

### CASE REPORT

This case regards a 2 month-old Indian baby, born in Italy. The baby was apparently healthy until one week before hospitalization, which was necessary for the presence of rhinitis, cough, conjunctival congestion, oropharyngeal mucositis and diffuse exanthema. At admission to hospital, the exam of heart, lungs and abdomen was normal, while there were no fever, laterocervical lymphadenopathy or periungual peeling. Chest X-ray was normal: Normally transparent pulmonary lobes with no pleural effusion. Laboratory tests showed: leukocytosis (15,370 per mm<sup>3</sup>), high ESR, positive C-reactive protein, thrombocytosis (476,000 per mm<sup>3</sup>). *Klebsiella pneumoniae* was isolated from the urine; therefore, the baby was treated with antibiotic therapy (Ceftriaxone). The clinical conditions were good now, with a gradual disappearance of cutaneous manifestations, rhinitis and cough. During the follow-up laboratory data showed: leukocytes 27,590×mm<sup>3</sup>; ESR 59; platelets 895,000×mm<sup>3</sup>. Death occurred suddenly and in apparently clinical healthy conditions on the 7th day from admission.

### RESULTS

The systematic autopsy revealed that the cause of death was due to inflammatory aneurysm rupture in the anterior descending coronary, with subsequent cardiac tamponade (sudden cardiac death of a mechanical type) and that numerous foci of necrotizing microvasculitis with mixed granulo- lymphomonocytic infiltrate, which mainly involved the arteriole-capillary area, were present at both cutaneous and mucosal levels (oropharyngeal mucous membrane) (Fig. 1 and 2). The anatomical-pathological situation suggested an atypical Kawasaki disease.



Fig. 1: A diagnostic image showing coronary and cardiac pathology

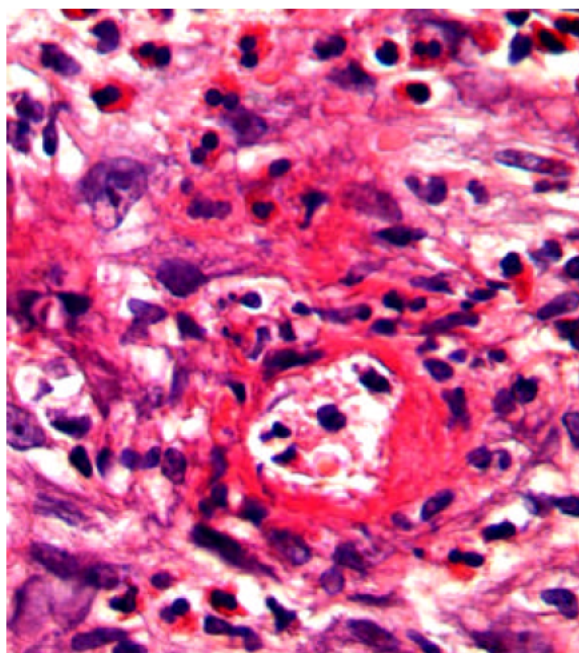


Fig. 2: Oral mucositis in a 2 month-old Indian baby affected by Kawasaki disease

#### DISCUSSION

Within Kawasaki Disease (KD), oral mucositis—represented by diffuse mucous membrane erythema, lip and tongue reddening and lingual papillae hypertrophy with subsequent development of strawberry tongue—can occur both in the acute stage of the disease (0-9 days) and in the convalescence stage (>25 days) as a consequence of the pharmacological treatment. Oral mucositis depends on the typical necrotizing microvasculitis with fibrinoid necrosis, which is common in Kawasaki disease and connected to an involvement of mucous-cutaneous and visceral systemic areas (conjunctival and pharyngeal congestion, polymorphous

rash, etc.). In the second case, it is an allergic reaction to drugs administered orally, with a different pathogenetic mechanism of the lesions, whose oral manifestation takes place in an isolated way.

The key pathological evidence of Kawasaki Disease (KD) is a multi-systemic vasculitis, which mainly involves medium calibre arteries (Rubin and Cotton, 1998; Fakushige *et al.*, 1994; Kado *et al.*, 1994). Such an involvement is particularly relevant because it affects the main coronaries leading to the development of aneurysms, which can determine decease through the formation of occlusive thrombi or wall rupture, with cardiac tamponade (Maresi *et al.*, 2001). Post-mortem morphological studies have shown how the vascular lesions vary according to the duration of the disease and the time of death. Within the first 9 days (stage I), vasculitis mainly involves microvessels (arterioles, capillaries and venules) and small arteries, at the level of both the adventitia of medium calibre muscular-elastic arteries (perivasculitis) and the systemic connective tissue (microvasculitis) (Hamashima *et al.*, 1983). Perivasculitis is responsible for the subsequent phlogistic involvement of the tunica media of muscular-elastic arteries and therefore, for the development of aneurysm, whose usual site is the subpericardial coronary arterial bed (Amano *et al.*, 1979).

On the other hand, necrotizing microvasculitis (fibrinoid necrosis) is observed in the systemic connective tissue at the cardiac level, but mainly at the cutaneous and at the mucosal levels and represents the typical morphological substratum of mucous-cutaneous and visceral clinical manifestations of the acute stage of the disease. For this reason, KD vascular lesions are defined as *systemic vasculitis* instead of *systemic arteritis*.

In the acute stage of the disease, circulation shows cytotoxic antibodies for the endothelial cells prestimulated by exposure to various cytokines (Amano *et al.*, 1979). Cytokines damage the endothelium in different ways.

Both IL and TNF elicit a proinflammatory and procoagulatory response from the endothelial cells (Amano *et al.*, 1979).

Both induce the Endothelium-Leukocyte Adhesion Molecule (ELAM1), involved in polymorphonucleate adhesion to the endothelium surface and increase the expression of the Intercellular Adhesion Molecule (ICAM1). This molecule takes part in polymorphonucleate, monocyte and lymphocyte leukocyte adhesion to endothelial cells through its interaction with leukocyte surface molecules belonging to the CD11 and CD18 complexes (Hamashima *et al.*, 1983).

Circulating cytotoxic antibodies directed towards components of neutrophil cytoplasm (ANCA, Antineutrophil Cytotoxic Antibodies), which are observed in other forms of vasculitis, such as PAN and Wegener's granulomatosis, were also observed in about one third of the children during acute KD (Hamashima *et al.*, 1983; Amano *et al.*, 1979). This evidence can sometimes help KD diagnosis, but it does not seem to be of special clinical relevance. The same can be said of the alteration of the CD4/CD8 ratio which, though notable due to the increase in CD4 and reduction in CD8, is not of a specific nature, is not directly related to the degree of severity and has no diagnostic relevance, if not within the other clinical symptoms and abnormal laboratory parameters (Amano *et al.*, 1979).

The cases of oral mucositis described in this study confirm literature data, revealing the morphological substratum constituted by microcirculation-necrotizing vasculitis.

### CONCLUSION

This study analyzed the anatomical-pathological substrata of oral mucositis in a baby affected by Kawasaki disease, revealing the morphological substratum constituted by necrotizing vasculitis.

### REFERENCES

- Amano, S., F. Hazama and Y. Hamashima, 1979. Pathology of Kawasaki disease: I. Pathology and morphogenesis of the vascular changes. *Jpn. Circ. J.*, 43: 633-643.
- Balz, D., V. Arbents and S. Fanconi, 1998. Myocarditis and coronary dilation in the 1st week of life: Neonatal incomplete Kawasaki disease? *Eur. J. Pediatr.*, 157: 589-591.
- Fukushige, J., N. Takahashi, Y. Ueda and K. Ueda, 1994. Incidence and clinical features of incomplete Kawasaki disease. *Acta Padiatr.*, 83: 1057-1060.
- Hamashima, Y., K. Takasaka and H. Fujiwara, 1983. Kawasaki's disease-its pathological features and possible pathogenesis. *Acta Padiatr.*, pp: 108-117.
- Kato, H., A. Nishiyori, T. Sugimura and Y. Sasaguri, 1994. Kawasaki vasculitis. *Nippon Rinsho*, 52: 2095-2102.
- Limbach, H.G. and A. Lindinger, 1991. Kawasaki syndrome in infants in the first 6 months of life. *Klin Padiatr.*, 203: 133-136.
- Maresi, E., R. Passantino and R. Midulla *et al.*, 2001. Sudden infant death caused by a ruptured coronary aneurysm during acute phase of atypical Kawasaki disease. *Hum. Pathol.*, 32: 1407-1409.
- Rubin, B. and D.M. Cotton, 1998. Kawasaki disease: A dangerous a cute childhood illness. *Nurse. Pract.*, 23: 34, 37-38, 44-48.