

## COX-2 Expression in the Inflamed Gingival Tissues: Immunohistochemistry, Cytochemistry and Biochemistry Tests

<sup>1</sup>Angelo Leone, Elvira <sup>2</sup>Farina-Lipari, <sup>1</sup>Aldo Gerbino,

<sup>3</sup>Francesco Burruano, <sup>3</sup>Silvia Tortorici and <sup>1</sup>Maria Buscemi

<sup>1</sup>Dipartimento di Medicina Sperimentale, Sezione di Istologia ed Embriologia<sup>1</sup>, Italy

<sup>2</sup>Sezione di Anatomia Anatomia Umana Normale, Italy

<sup>3</sup>Dipartimento di Scienze Stomatologiche, Italy

**Abstract:** Prostaglandins (PG) are chemical mediators for most physiological and pathological responses, including cytoprotection of the gastric mucosa, blood coagulation, inflammation and pain (1, 2, 3). E2 Prostaglandins (PG2) play an important role in the pathogenesis of periodontal diseases, since PG2 determines vasodilatation and increased vascular permeability, oedema and erythema. Therefore, it is not surprising to find high levels of PG2 in inflamed gingival tissues. Indeed, in inflamed gingival tissue, PG2 levels of the Gingival Fluid (GCF) are known to be higher in periodontitis than in healthy gingiva. Moreover, in different periodontitis the high PG2 level of the GCF is related to periodontal ligament loss. The pathogenesis of the periodontitis can be due to the high PG2 activation of the Matrix Metal-Protease (MMP), which is synthesized by monocytes and fibroblasts. Consequently, destruction of connective tissue on a large scale takes place. The aim of this research is two-fold: To test the COX-2 expression in the human epulis and study its involvement in the PG2 synthesis and to find an alternative therapy to treat gingival diseases.

**Key words:** COX-2, epulis, immunohistochemistry, inflamed gingival tissues, biochemistry

### INTRODUCTION

Prostaglandin (PG) synthesis begins from the arachidonic acid release from membrane phospholipid molecules by the phospholipase A2 activity. Prostaglandin synthesis occurs in many different cytotypes including the epithelial cells, the endothelial cells, macrophages and fibroblasts. Arachidonic acid is the substrate in both lipoxygenase and cyclooxygenase enzymatic ways. Prostaglandins, Tromboxane (TXB) and cyclooxygenase are synthesized from the arachidonic acid metabolism (Noguchi *et al.*, 1999). Two COX isoforms, namely COX-1 and COX-2, are known. They have two different coding genes and catalyze the same reactions. Therefore, the two isogenes have tissue specificity.

Most of the physiological activity in cells is mediated by COX-1, whereas the inflammatory effects are induced by COX-2.

COX-1 is in the constitution of all human tissues. Small quantities of COX-2 are to be found in healthy tissues whereas large quantities of COX-2 are to be found in inflamed gingival tissues. Many studies show high PGE levels in inflamed gingival tissues but it is not known if the increase of PGE2 levels is due to local COX2 expression (Tuter *et al.*, 2002; Nakao *et al.*, 2000).

The gingival fibroblasts are numerous cells which play the important role of remodeling and proliferating tissue. It has been demonstrated that fibroblasts are stimulated by cytokines and LPS produce PG2, which appears to play a role in the destruction of tissues, such as in periodontitis (Noguchi *et al.*, 1996). Literature on COX-2 expression is very limited. Some authors showed that gingival fibroblasts, stimulated by interleukins, increase the mRNA COX-2 expression (Sakurai *et al.*, 2000). By contrast COX-1 expression shows no increase. COX-2 expression increases in the gingival cells when stimulated by *Bacterium forsythus* or *Actinomyces comitans*.

### MATERIALS AND METHODS

We have used 12 Epulis taken during surgical operation from the files of the department of stomatology, Dental School, in Palermo Italy. We have used also a normal gingival specimen taken during dental extraction as negative control. The histopathological diagnosis was made in Institut of Anatomy Pathology, Medical School of Palermo Italy.

- All the specimens were fixed in Bouin's mixture and embedded in paraffin.
- Sample were stained with hematoxylin and eosin for the morphological exam.
- The immunohistochemical distribution of inducible COX(COX-2) was investigated. - Section with 5µm of thickness were collected on microscope slides 76×26 mm (Objektträger, Menzel-Glaser, Germany). The immunohistochemical staining was made using a monoclonal antibody against COX-2 (Santa-Cruz laboratories) purified rabbit anti-COX type II Pab, 150µg, 0,6ml 250 µg mL<sup>-1</sup>. The sections were processed for immunohistochemistry by the standard Streptavidin-Biotin complex method kit ultrastain polyvalent strept ABC-HRP (Y1em). After incubation period with antibody (1:200) diluted in PBS with BSA 0,1% sections were washed with PBS and Igepal. Sections were washed again in PBS and incubated with polyvalent antiserum pre-diluted for 10 min, one more washing with PBS and incubation with streptavidine POD for 20 min. The revelation of immunocomplex was obtained with 3-Amino-9Ethylcarbazole (AEC). Following immunostaining the sections were covered with water-soluble mounting medium (Dako paramount aqueous mounting medium) and observed with Leica microscope.
- Some fibroblasts were treated with IL-1 as proinflammatory agent, in a other sample was added IL-1 and specific inhibitor of COX-2, more, one sample was without proinflammatory agent, all were growing in 3D collagen type 1. After 5 days growth, the collagen was digested at 37 C for 5 min with 10 mg mL<sup>-1</sup> collagenase ( SIGMA) in PBS. The collagenase had been prewarmed to 37 C and 0.35nM CaCl added just before use. The suspension was transferred to a 50 mL conical flask and centrifuged for 5 min at 1000 g, the pellet resuspended in 5 mL PBS, repelled by another 5 min centrifugation at 1000 g, lysed and Western blotted for COX-2 ( 1:100; santa Cruz).
- Western blotting was conducted using gingival fibroblasts.

## RESULTS

**A healthy gingiva - Results of COX-2 and COX-1 immunoreactivity and negative control:** In normal healthy gingival tissue (Fig. 1), COX-2 immunopositivity is only present in some blood vessels whereas COX-1.

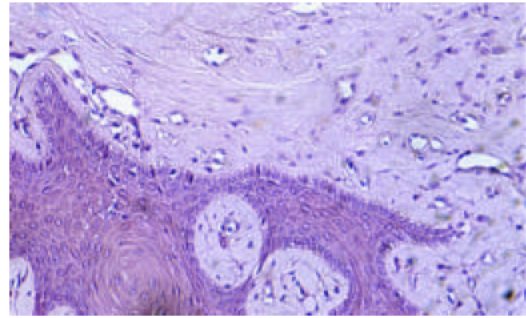


Fig. 1: Normal healthy gingival tissue COX-2 immunopositivity

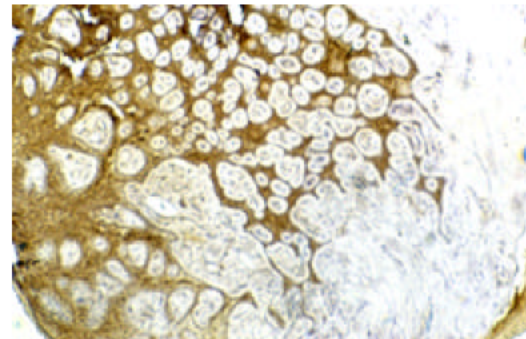


Fig. 2: Normal healthy gingival tissue COX-1 immunopositivity

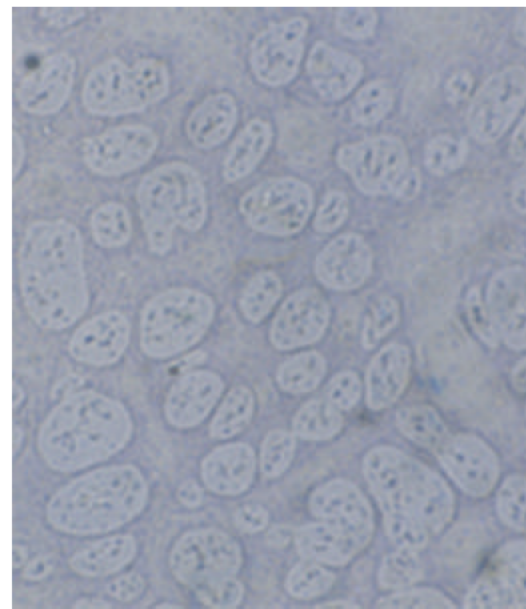


Fig. 3: The control of healthy gingiva is negative

immunopositivity is present in all cytotypes (Fig. 2) the control of healthy gingiva is negative (Fig. 3).

**Epulis:** The H.E. stained sections of Epulis shows inflammatory infiltrate (Fig. 4).

**Epulis papilloma:** The observations of the sections show strong inflammation and immunohistochemical positivity for COX-2 in the epithelial cells, stroma and endothelium (Fig. 5).

**Epulis plasmacytoma:** The H-E stained sections show an infiltrate with numerous plasma cells (Fig. 6). The immunostained sections show COX-2 immunopositivity in the epithelial cells, stroma and endothelium (Fig. 7).

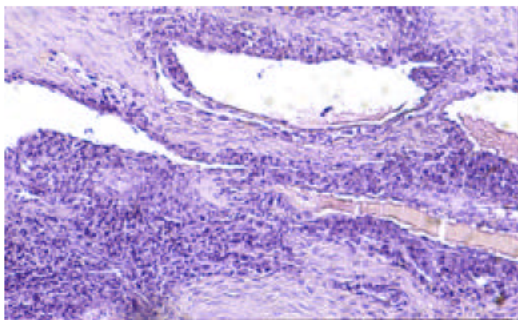


Fig. 4: The H.E. stained sections of Epulis

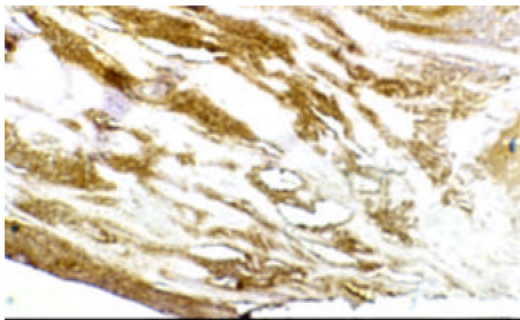


Fig. 5: Strong inflammation and immunohistochemical positivity for COX-2

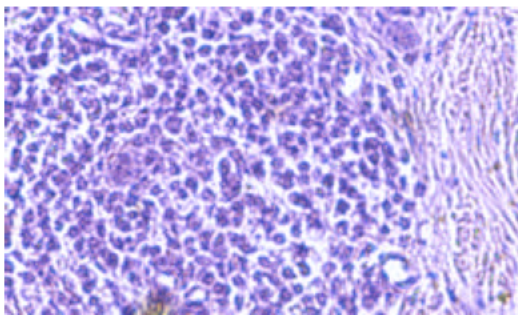


Fig. 6: An infiltrate with numerous plasma cells

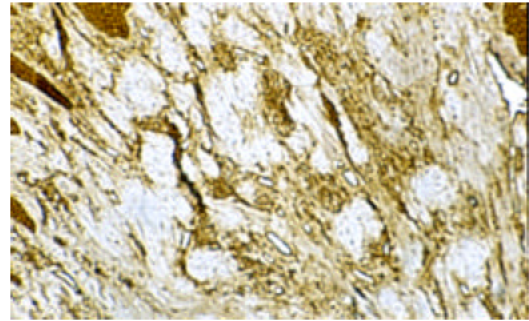
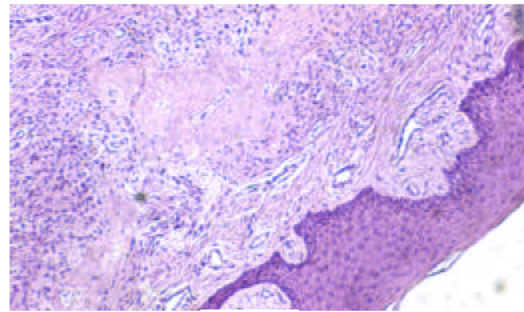
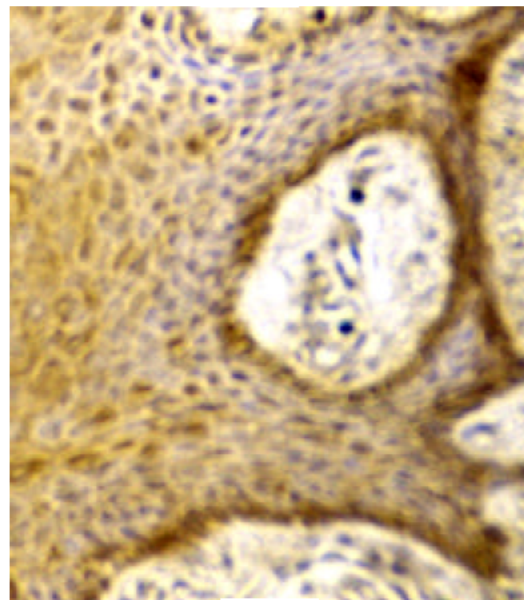


Fig. 7: COX-2 immunopositivity in the epithelial cells, stroma and endothelium



(a)



(b)

Fig. 8a, b: Calcifying structures and COX-2 immunopositivity only in the epithelium

**Peripheral ossifying fibroma:** Our observations (Fig. 8a, b) show calcifying structures and COX-2 immunopositivity only in the epithelium.

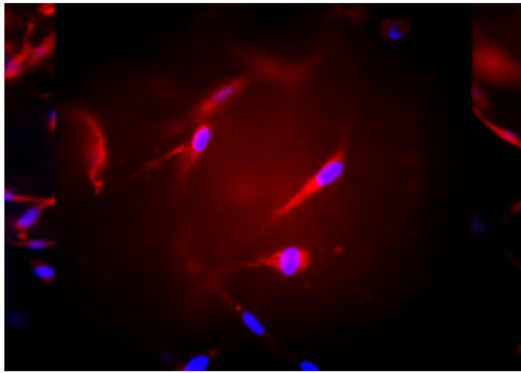


Fig. 9: COX-2 immunopositivity in 3D culture fibroblasts

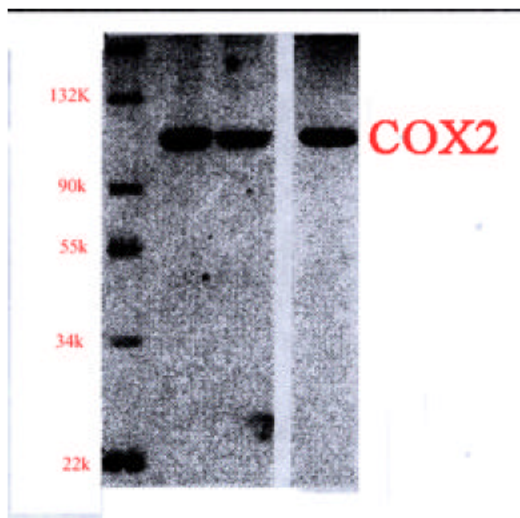


Fig. 10: Western blotting

**Fibroblasts in 3D culture:** We have tested, furthermore, COX-2 activity in the fibroblasts 3D culture to compare the cytochemical experimental data with epulis immunohistochemistry results:

- COX-2 immunopositivity in 3D culture fibroblasts is strong following treatment with interleukin B (2.0 mg/ml/24h) (Fig. 9).
- COX-2 immunostaining sections is detected in inflamed gingival tissues and is particularly intense in epithelium, endothelium and fibroblasts.

Our findings with COX-1 immunostaining are in line with the literature data. Indeed, the immunopositivity in both healthy and inflamed gingival lead us to believe that COX-1 is a ubiquitous enzyme.

**Western blotting:** It was positive using cells treated with IL-1 and negative using cells treated with IL-1 and inhibitor of COX-2 (Fig. 10).

## DISCUSSION

It is well known that the level of COX2 increases in many different inflammatory diseases, such as inflammatory diseases of the joints, intestinal and rheumatoid arthritis. This supports our findings which showed marked COX2-immunopositivity in highly inflamed tissues. Some authors found high level of COX2 in the synovial fluid of joint diseases.

The presence of prostaglandins is due to COX2 expression in prostaglandins which play an important role in the pathogenesis of inflamed diseases. It is known that prostaglandins are involved in the intestinal CI production, or regulation of cytokines production in white cells (lymphocytes and macrophages) to proliferation of the epithelial cells mucosal.

Therefore, we deduce that prostaglandins E2 are involved in the destruction of alveolo-dental ligament and alveolar bone. COX-1 and COX-2 catalyze the same reaction but are involved in different functions.

COX-1 transcripts always and keeps a constant level in many cytotypes. COX-2 transcription occurs only when necessary since COX-1 coding gene is involved in physiological conditions, whereas COX-2 coding gene is involved in the inflammatory tissues and in pain.

These data are supported by our studies carried out on gingival fibroblasts in 3D culture. Indeed, these fibroblasts showed a light COX-2 immunopositivity, whereas fibroblasts treated with proinflammatory factors such as interleukins or bacteria showed strong COX-2 immunopositivity. Therefore, it was deduced that a pathogenic mechanism of parodontal disease can be present owing to COX-2 synthesis stimulated by bacteria.

## CONCLUSION

In order to block prostaglandin synthesis in some conditions such as rheumatoid arthritis, Non Steroid Anti-Inflammatory Drugs (NSAID) are normally used. In the treatment of parodontal diseases, flurbiprofen, of the NSAID family, is used because it slows down bone loss. There are less studies on NSAID being used in the epulis. They report that administration of flurbiprofen for a long time has no therapeutic effect. This is probably due to its side effects and therefore, patients had to stop taking it.

We suggest that well be possible in future the pharmacological use of specific COX-2 inhibitors because

they might block uncontrolled increase of gingival tissue, as we demonstrated and diminish bone and connective loss, literature and might also avoid side effects such as gastrotoxicity, as known in scientific literature.

#### REFERENCES

- Naguchi, K., M. Shitashige and I. Ishikawa, 1999. Involvement of cyclooxygenase-2 in Interleukin-1 $\alpha$ - Induced Prostaglandin Production by Human Periodontal Ligament Cells. *J. Periodontol.*, 70: 902-908.
- Nakao, S., Y. Ogata, E. Shimitsu-Sasaki, M. Yamazaki, S. Furuyama and H. Sugiya, 2002. Activation of Nfkappa- $\alpha$  is necessary for IL-1 beta-induced Cyclooxygenase-2 (COX-2) expression in human gingival fibroblasts. *Mol. Cell. Biochem.*, 209: 113-118.
- Noguchi, K., M. Shitashige, M. Yanai, I. Monta and T. Nishihara, S. Murota I. Ishikawa, 1996. Prostaglandin production via induction of cyclooxygenase-2 by human gingival fibroblasts stimulated with Lipopolysaccharides. *Inflammation*, 20: 555-568.
- Sakurai, Y., Yamaguchi M., Abiko Y., 2000. Inhibitory effect of low-level laser irradiation on LPS- stimulated prostaglandin E2 production and cyclooxygenase-2 in human gingival fibroblasts. *Eur. J. Oral. Sci.*, 108: 29-34.
- Tuter, G., M.A. Serdar, M. Yalim, I.S. Gurhan and K. Balos, 2002. Evaluation of matrix metalloproteinase-1 and tissue inhibitor of metalloproteinase-1 levels in gingival fibroblasts of cyclosporin. A-treated patients. *J. Periodontol.*, 73: 1273-1278.