

Solasodine Rhamnosyl Glycosides in a Cream Formulation is Effective for Treating Large and Troublesome Skin Cancers

Bill E. Cham

Australasian Medical Research, P.O. Box 7031,
Port Vila, Republic of Vanuatu

Abstract: It is now established that solasodine rhamnosyl glycosides (BEC) are antineoplastics. Specificity of BEC to interact with particular receptors on tumour cells relative to normal cells and the involvement of the sugar rhamnose, conjugated to the glycoalkaloids BEC, as a key molecule to gain entry into cancer cells but not normal cells has been established. Once the BEC-receptor is inside the cell by the receptor-mediated endocytosis process, the complex is eventually taken up by the lysosomes. BEC then induces the lysosome to rupture causing immediate cancer cell death by apoptosis. It is now accepted that BEC formulated in a topical cream is effective for treating non-melanoma skin cancers Basal Cell Carcinoma (BCC) and Squamous Cell Carcinoma (SCC). Previous studies have described the efficacy of BEC on non-melanoma skin cancers that approximate lesion sizes of the general population. In this study, large non-melanoma skin cancers were treated with BEC as well as non-melanoma skin cancers located in areas of the body that are considered difficult to treat by any existing modality. Eight patients with BCCs and 11 patients with SCCs were treated and after treatment, were followed-up for at least 5 years. The results indicate that BEC can successfully dispose of large and difficult to treat BCCs and SCCs. Furthermore, the results demonstrate that the cosmetic effect after BEC therapy is superior to other treatment methods.

Key words: Skin cancer, solasodine glycosides, BEC, BCC, SCC, clinical, histopathology

INTRODUCTION

Skin cancer is a disease in which skin cells lose the ability to divide and grow normally. Healthy skin cells normally divide in an orderly fashion to replace dead cells and grow new skin. Abnormal cells, which can be induced by various means, can grow out of control and form a mass or "tumour". When abnormal cells originate in the skin, the mass is called a skin tumour.

A skin tumour is considered benign if it is limited to a few cell layers and does not invade surrounding tissues or organs. But, if the tumour spreads to surrounding tissues it is considered malignant or cancerous. Cancer cells crowd out and destroy nearby healthy cells forming growths called malignant tumours or skin cancers. Skin cancer can be divided into melanomic and non-melanocytic types.

Melanoma is a malignant tumour of melanocytes (cells that produce the pigment melanin) which are found predominantly in skin but also in the eye and in the bowel. It is one of the rarer types of skin cancer but causes the majority of skin cancer related deaths. Because of the high probability that this tumour may metastasize, the

treatment of choice currently is surgical removal of the tumour followed, if necessary, by chemo-, immuno- or radiation therapy.

Non-melanoma skin cancers are comprised of BCC and SCC. BCC is the most common form of cancer and represents approximately 80% of all skin cancers, with about a million new cases estimated in the United States each year. Basal cells line the deepest layer of the epidermis. BCCs are malignant growths that arise in this layer. They can be difficult to eliminate and 5-10% of BCCs can be resistant to treatment or locally aggressive, damaging the skin around them and sometimes invading bone and cartilage. SCC is the second most common form of skin cancer, with over 250,000 new cases estimated in the United States every year. It arises in the squamous cells which are located in the prickle layer of the epidermis. SCCs are more difficult to treat than BCCs and like BCCs, can cause disfigurement. A small proportion (3-5%) can spread to distant organs and become life-threatening.

As with melanoma, surgery is the most common treatment for non-melanoma skin cancers. Unfortunately, recurrence rates when surgical methods are used are very

high (30-67%) for non-melanoma skin cancers (Sussman and Liggins, 1996). Therefore, the quest for more effective modalities is much needed. BEC which is composed of solasodine rhamnosyl glycosides has antineoplastic properties against a wide variety of human cancers in cell culture, tissue culture (Badami *et al.*, 2003; Cham, 1988, 1991, 1993, 1994, 2007; Cham and Daunter, 1990 a; Cheng *et al.*, 1998; Daunter and Cham, 1990; Esteves-Souza *et al.*, 2002; Kuo *et al.*, 2000; Kuo and Lin, 1999; Lee *et al.*, 2004; Liang *et al.*, 2004; Liu *et al.*, 2004; Nakamura *et al.*, 1996; Ono *et al.*, 2003; Ono *et al.*, 2006; Roddick *et al.*, 1990; Solbec; Verpoorte, 1998; Vijayan *et al.*, 2002; Yoshikawa *et al.*, 2007) and is very effective against terminal tumours in animals (Amalfi, 2006; Cham, 1988, 1991, 1993, 1994, 2007; Cham and Daunter, 1990a; Cham *et al.*, 1987; Solbec). In addition BEC shows promise as an antineoplastic for the treatment of terminal cancers in man (Cham, 2007; Millward *et al.*, 2006; Solbec).

A cream formulation containing solasodine rhamnosyl glycosides when used topically is very effective for the treatment of non-melanoma skin cancers (Cerio and Punjabi, 2002; Cham, 1988, 1989, 1991, 1993, 1994, 2007; Cham and Daunter, 1990 b; Cham and Meares, 1987; Cham *et al.*, 1987; Cham *et al.*, 1991; Evans *et al.*, 1989; Punjabi *et al.*, 2000; Walsh, 2000). The modes of action of this preparation appears to be unique (Badami *et al.*, 2003; Cham, 1991, 1993, 1994, 2007; Cham and Daunter, 1990 a; Cham *et al.*, 1987; Cheng *et al.*, 1998; Daunter and Cham, 1990; Esteves-Souza *et al.*, 2002; Kuo *et al.*, 2000; Kuo and Lin, 1999; Lee *et al.*, 2004; Liang *et al.*, 2004; Liu *et al.*, 2004; Nakamura *et al.*, 1996; Ono *et al.*, 2003; Roddick *et al.*, 1990; Vijayan *et al.*, 2002). It has been reported, that skin cancer therapy with these solasodine glycosides when applied topically to exposed skin cancers the formulation selectively necrotises the tumour cells or induces them to undergo apoptosis or necrosis without causing damage to the surrounding healthy skin cells. Although, there is now overwhelming evidence that solasodine glycosides eliminate non-melanoma skin cancers, only limited cases have been presented in which resistant, locally aggressive, cartilage invasive BCCs and SCCs have been successfully eliminated with the solasodine glycosides cream formulation.

This communication presents cases in which the treated lesions of both BCCs and SCCs were large or were positioned in areas where surgery would most likely have resulted in serious disfigurement in addition to the expected recurrences with surgery (Sussman and Liggins, 1996).

The objective of this study, was to evaluate the efficacy of a topical formulation containing solasodine rhamnosyl glycosides in the treatment of advanced BCCs and SCCs or the treatment in areas of the body where

these skin cancers are difficult to treat by other means. No safety measurement studies were done as it was previously shown by many other studies that this preparation was extremely safe (Cerio and Punjabi, 2002; Cham, 1988, 1989, 1991, 1993, 1994, 2007; Cham and Daunter, 1990 b; Cham and Meares, 1987; Cham *et al.*, 1987; Cham *et al.*, 1991; Evans *et al.*, 1989; Punjabi *et al.*, 2000; Walsh, 2000).

MATERIALS AND METHODS

Selection of study population: This was an open study. Patients were recruited in Brisbane, Australia. Screening was conducted 2 weeks before the baseline visit. At screening for eligibility a 2 mm punch biopsy of each tumour for histological confirmation of BCC or SCC was conducted. Lesions that were considered for treatment were either limited to particular areas of the body which are considered difficult to treat by any treatment modality or for their sizes (at least 2 cm in diameter). Eight patients with BCCs and 11 patients with SCCs met the study criteria.

Treatments administered: The study medication (Curaderm) was kindly supplied by Cura Nominees Pty Ltd. Curaderm contained 0.05 mg BEC/g cream formulation (Cham *et al.*, 1991). Patients received Curaderm in 20 mL containers and a supply of occlusive dressing (paper tape, micropore). Patients received verbal and written instructions from the investigator regarding the correct application techniques to be used. The investigator administered the first dose of Curaderm so that the patient could learn the correct application techniques by example.

Before applying the cream, patients were instructed to wash the lesion and the surrounding area with a mild, non-irritating soap, to rinse with water and allow the area to dry thoroughly. Curaderm was applied to the lesions in sufficient quantity to cover each lesion. The cream did not extend more than 0.5 cm onto the apparently normal skin surrounding the edge of the lesion. Each lesion was covered with the paper tape (micropore) occlusive dressing until the next application of Curaderm cream. The cream was applied to each lesion using the dropper lid of the container twice daily, i.e. every 12 h until clinical healing of the treated lesion was observed. At the end of the treatment periods 2 mm punch biopsies were taken to establish effectiveness of the treatment. In addition, the treated patients were followed-up for at least 5 years post treatment for clinical evaluation of possible recurrences.

RESULTS AND DISCUSSION

Histological analyses of the biopsies confirmed the clinical evaluation. Eight patients were confirmed with BCCs and 11 patients were confirmed with SCCs. Seven

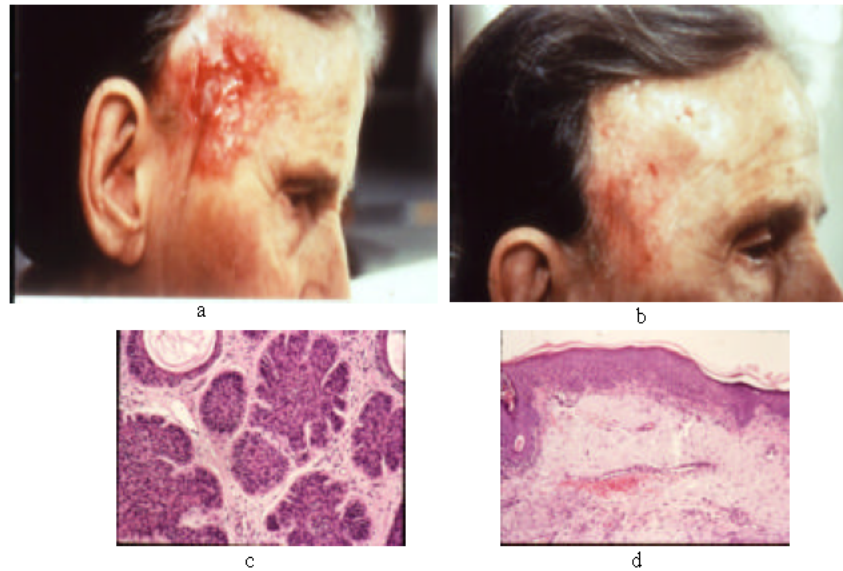


Fig. 1: Large BCC on the temple of a woman (a). This BCC had been surgically removed and skin grafts applied on two previous occasions only to return. Four weeks treatment with Curaderm resulted in full regression (b). Note the cosmetic result. The clinical diagnosis was confirmed histologically by punch biopsy (c). After completion of the therapy histopathology determined that no residual cancer was present (d). Clinical assessment 5 years post treatment revealed that there was no recurrence

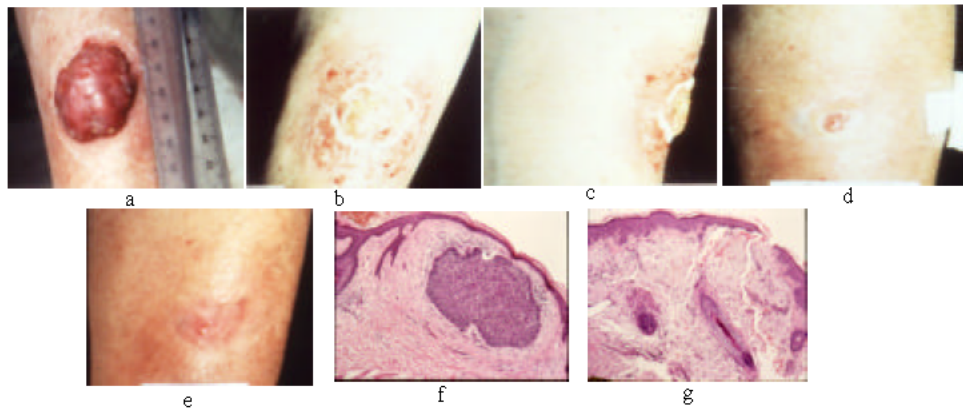


Fig. 2: Large BCC on the leg (a). Note how rapid the cancer was being destroyed by Curaderm during treatment (b - d) and how rapid the wound healed after 5 weeks of Curaderm therapy (e). The clinical diagnosis was confirmed histologically by punch biopsy (f). After completion of the therapy histopathology determined that no residual cancer was present (g). Clinical assessment 5 years post treatment revealed that there was no recurrence

women, 4 of which had BCCs (mean age 58.5; range 52-67 years) and 3 had SCCs (mean age 52.3; range 44-57 years); and 12 men, 4 had BCCs (mean age 60.4; range 49-69 years) and 8 had SCCs (mean age 59.4; range 49-68 years) participated in the study. All treated patients were Caucasians and completed the study regime.

Figure 1-19 show the clinical and histological evaluations of all the patients. The duration of the

Curaderm therapy varied depending on the type and size of the particular lesion. The mean treatment period for BCCs were 8.5 weeks (range 4 – 16 weeks). For SCCs the mean treatment periods were 9 weeks (range 5 - 16 weeks). In all cases complete regression of treated lesion was obtained as shown histologically by analyses of biopsies at the completion of treatment period and clinical assessment 5 years post treatment.

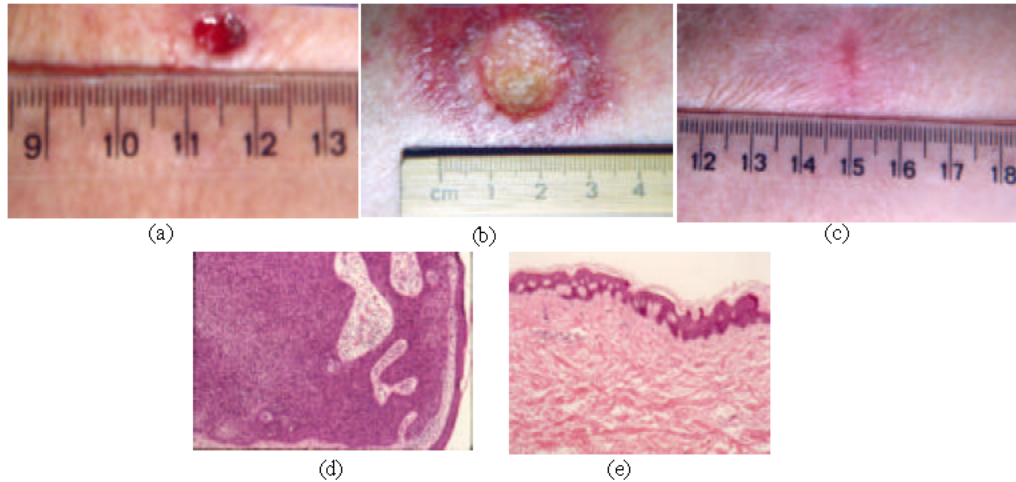


Fig. 3: BCC on the arm. Note initially how small the lesion appeared before curaderm therapy (a). During therapy it is clear that Curaderm was attacking and killing all the cancerous cells (b), which prior to Curaderm treatment were not apparent. Curaderm exposes the clinically unnoticed cancer cells and eliminates them (c). Treatment period for this patient was 8 weeks. The clinical diagnosis was confirmed histologically by punch biopsy (d). After completion of the therapy histopathology determined that no residual cancer was present (e). Clinical assessment 5 years post treatment revealed that there was no recurrence

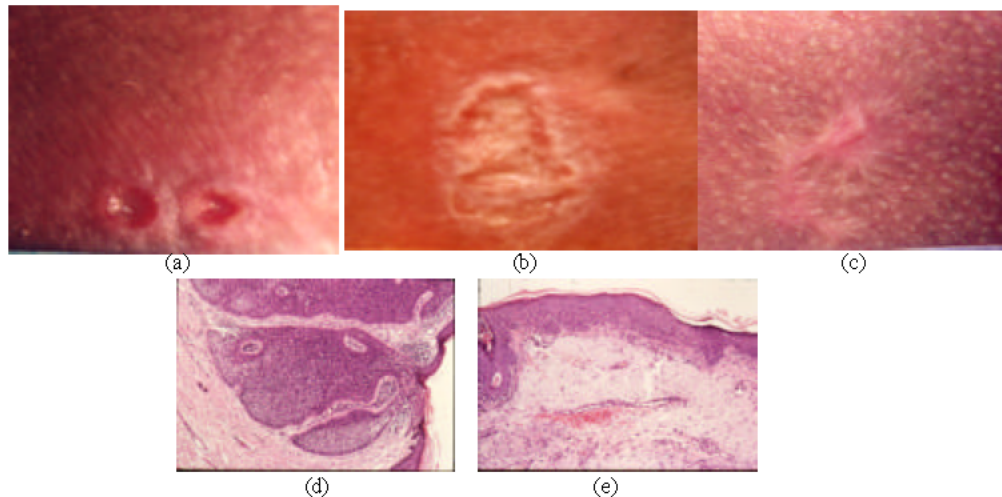


Fig. 4: A clinically diagnosed BCC before treatment which appears to be two distinct lesions (a). During treatment Curaderm shows that it is one large BCC (3cm x 4cm) (b). After treatment the lesion is completely ablated and some scar tissue can be seen (c). Treatment period was 16 weeks. Histological analysis before Curaderm therapy shows characteristic infiltrated cancer cells well within the dermis (d); after Curaderm therapy there are no cancer cells (e). Clinical assessment 5 years post treatment revealed that there was no recurrence

In all but one case follow-up periods of at least five years revealed that there were no recurrences as assessed by clinical evaluation. One male patient who was treated for an SCC on his head (Fig. 16) visited his dermatologist after Curaderm treatment because he had bumped his head accidentally. During the consultation his dermatologist questioned the patient's participation in the

Curaderm study and convinced the patient that Curaderm was unproven and that surgery was now necessary involving a skin graft on the Curaderm treated lesion site. The patient agreed to the surgery and requested the histological evidence that the SCC was still present after Curaderm therapy. After the surgery was completed six areas of the surgically removed tissue representing the

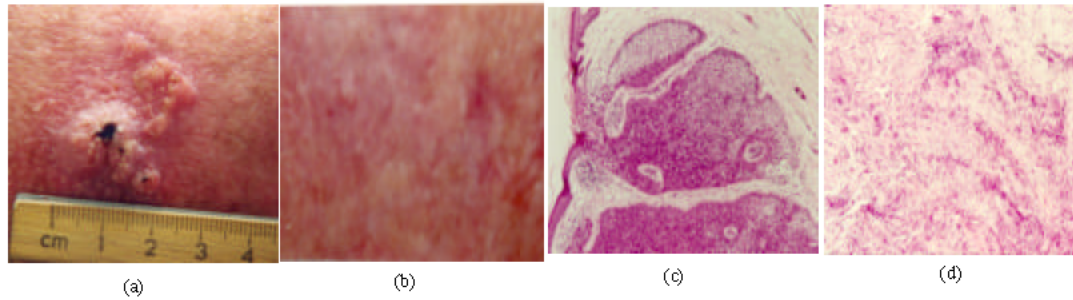


Fig. 5: BCC before treatment (a) and after 8 weeks of Curaderm treatment (b). The clinical diagnosis was confirmed histologically by punch biopsy (c). After completion of the therapy histopathology determined that no residual cancer was present (d). Clinical assessment 5 years post treatment revealed that there was no recurrence

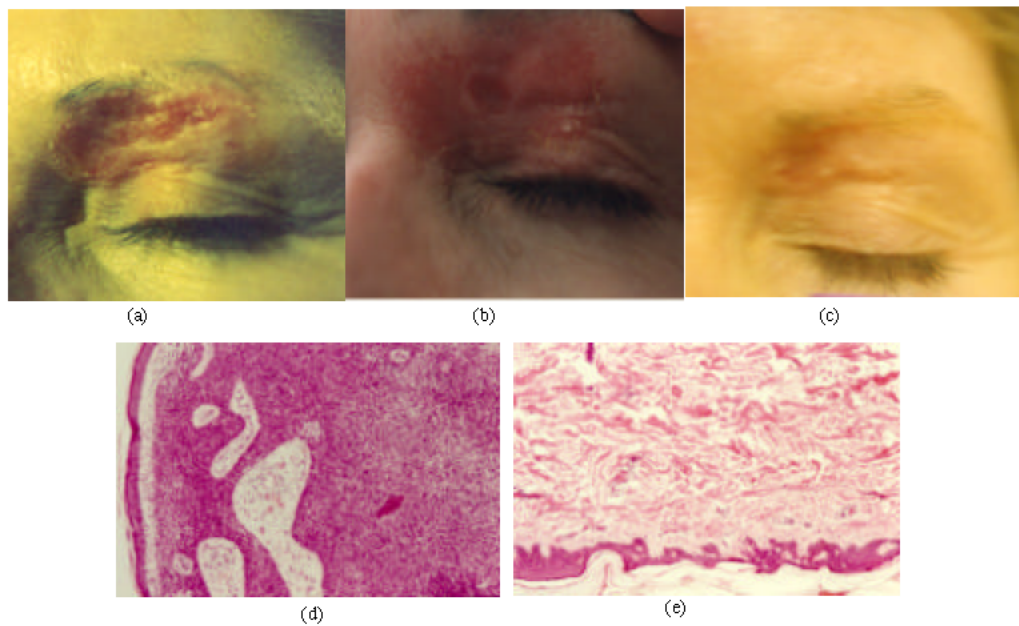


Fig. 6: BCC over the left eye of a patient before (a), during (b) and after curaderm treatment (c). Careful application of uraderm was required to ensure that the cream did not enter the eye. During Curaderm therapy the distinct tumor can be seen surrounded by some inflammation. After treatment there was no trace of the BCC. Confirmation by histological analysis of the BCC before treatment (d) and after treatment (e) are shown. The total treatment period was 9 weeks. Clinical assessment 5 years post treatment revealed that there was no recurrence

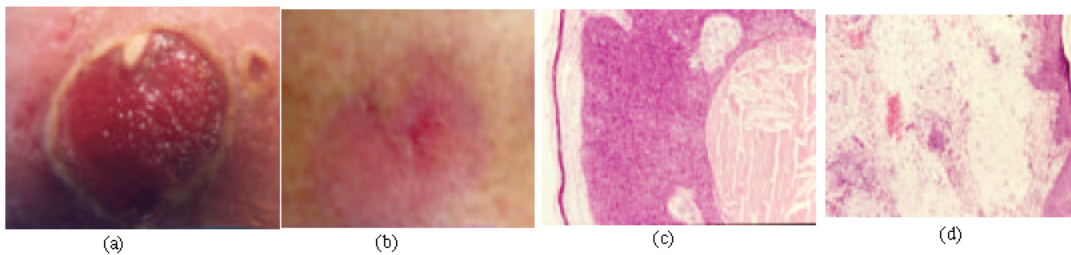


Fig. 7: Clinical (a) and histological (c) diagnosed BCC before Curaderm treatment. The diameter of the lesion was 5cm. Clinical (b) and histological (d) analyses after treatment. Duration of treatment was 8 weeks. Clinical assessment 5 years post treatment revealed that there was no recurrence

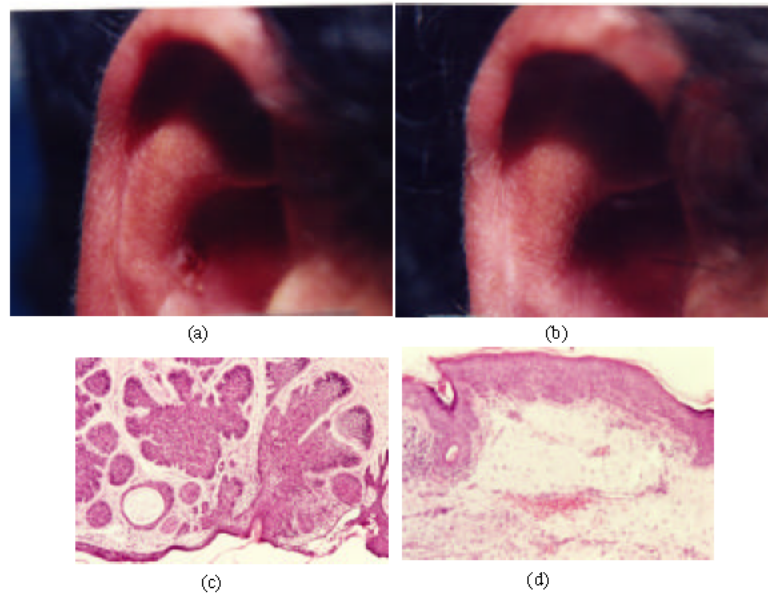


Fig. 8: Clinical (a) and histological (c) diagnosed BCC in the ear of a patient before Curaderm treatment. Clinical (b) and histological (d) analyses after treatment. Duration of treatment was 10 weeks. Clinical assessment 5 years post treatment revealed that there was no recurrence

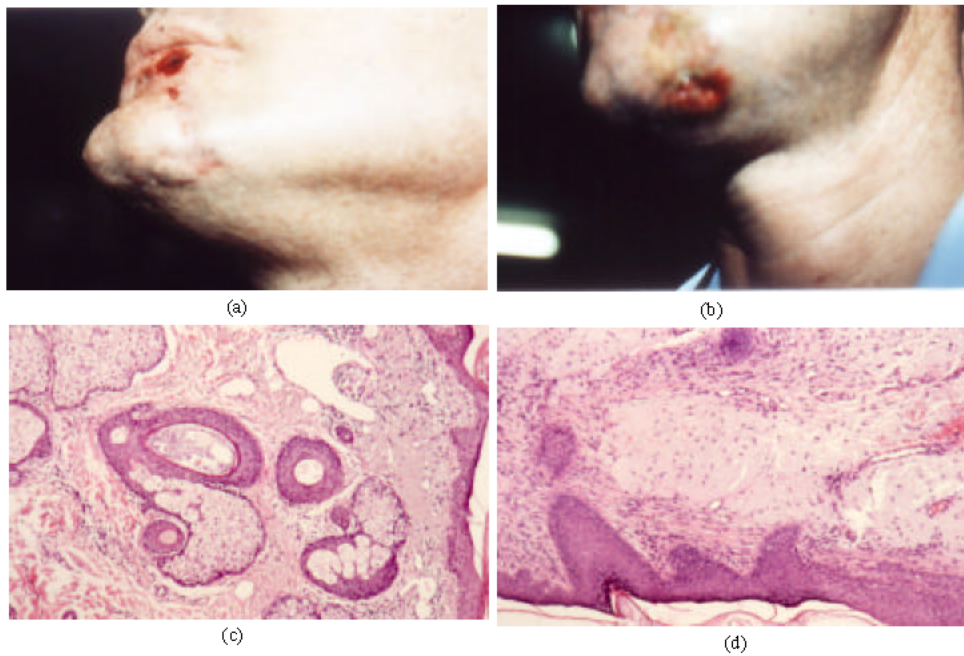


Fig. 9: This patient had a deep seated SCC under the chin (a). After 6 weeks treatment with Curaderm the cancer cleared up (b). The clinical diagnosis was confirmed histologically by punch biopsy (c). After completion of the therapy histopathology determined that no residual cancer was present (d). Clinical assessment 5 years post treatment revealed that there was no recurrence

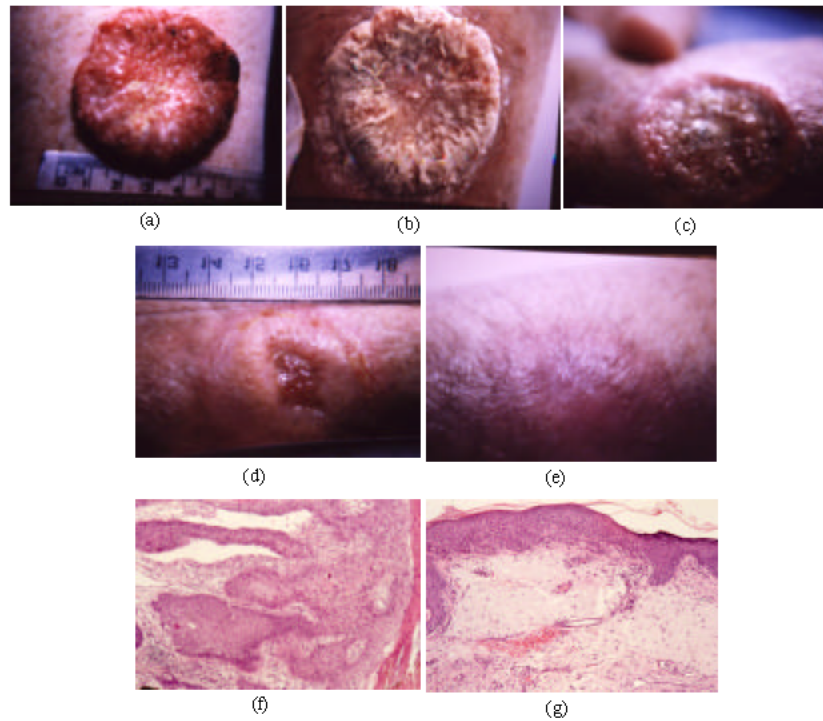


Fig. 10: A very large SCC, 6cm in diameter, before (a), during (b – d), and after (e) treatment with uraderm. The treatment period was for 12 weeks. Note the specificity of Curaderm for the cancer cells and the regrowth of normal cells during Curaderm therapy. The clinical diagnosis was confirmed histologically by punch biopsy (f). After completion of the therapy histopathology determined that no residual cancer was present (g). Clinical assessment 5 years post treatment revealed that there was no recurrence

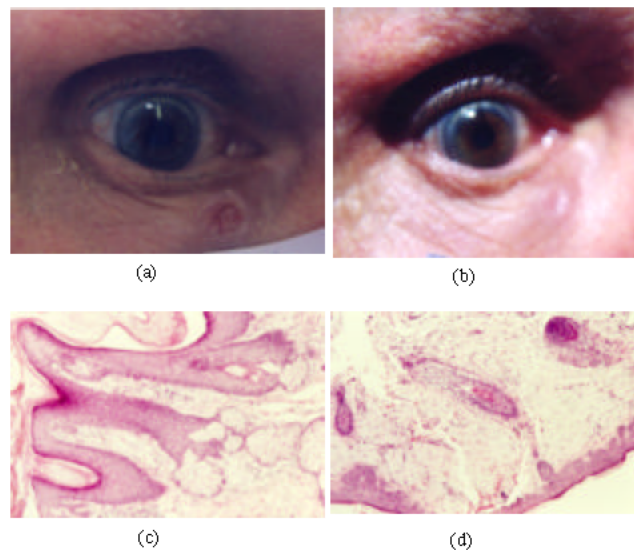


Fig. 11: SCC under the right eye of a patient before (a) and after Curaderm treatment (b). Careful application of Curaderm was required to ensure that the cream did not enter the eye. After treatment there was no trace of the SCC. Confirmation by histological analysis of the SCC before treatment (c) and after treatment (d) are shown. The total treatment period was 14 weeks. Clinical assessment 5 years post treatment revealed that there was no recurrence

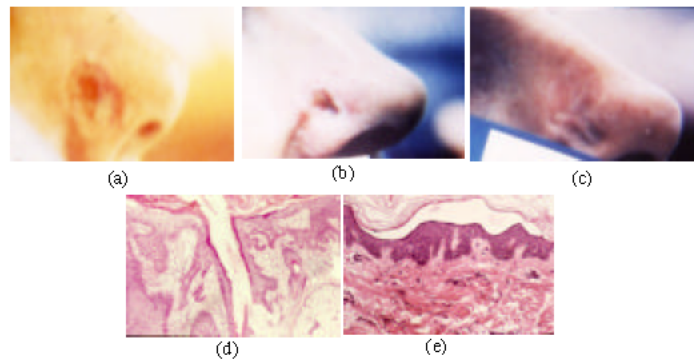


Fig. 12: SCC on the nose of a patient before (a), during (b) and after treatment with Curaderm (c). Treatment duration was 16 weeks. The clinical diagnosis was confirmed histologically by punch biopsy (d). After completion of the therapy histopathology determined that no residual cancer was present (e). Clinical assessment 5 years post treatment revealed that there was no recurrence

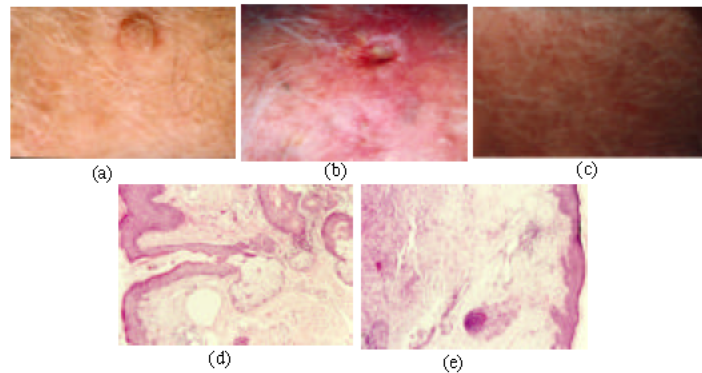


Fig. 13: SCC on the head of a patient before (a), during (b) and after Curaderm treatment (c). Treatment duration was 6 weeks. The clinical diagnosis was confirmed histologically by punch biopsy (d). After completion of the therapy histopathology determined that no residual cancer was present (e). Clinical assessment 5 years post treatment revealed that there was no recurrence

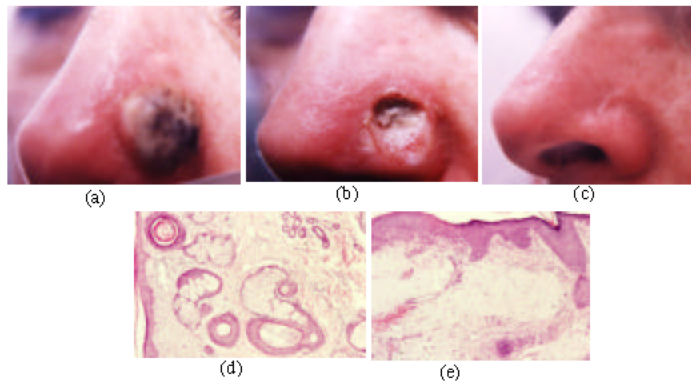


Fig. 14: SCC on the nose of a patient before (a), during (b) and after Curaderm treatment (c). Curaderm was applied for 5 weeks. Note the depth of the cancer as cartilage was exposed during treatment. The clinical diagnosis was confirmed histologically by punch biopsy (d). After completion of the therapy histopathology determined that no residual cancer was present (e). Clinical assessment 5 years post treatment revealed that there was no recurrence

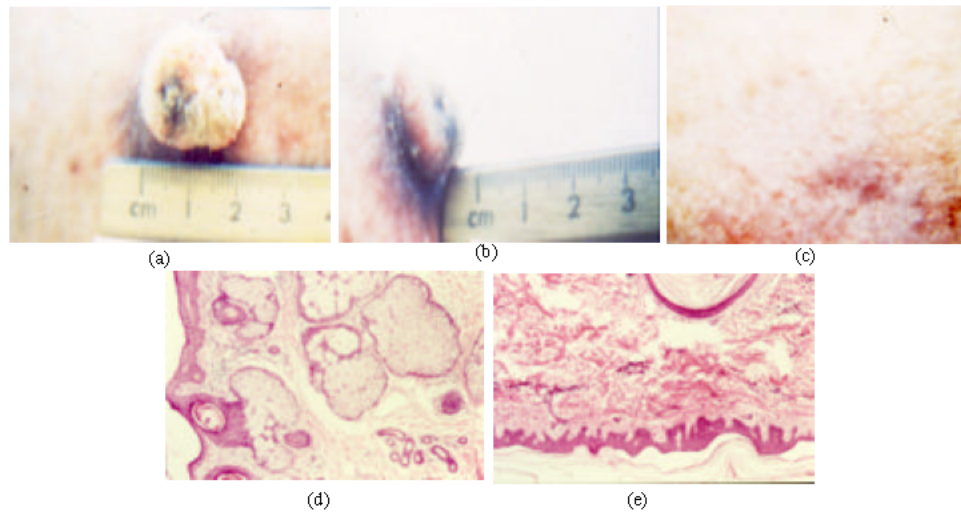


Fig. 15: A protruding SCC before (a, b) and after Curaderm therapy (c). Treatment duration was 8 weeks. The clinical diagnosis was confirmed histologically by punch biopsy (d). After completion of the therapy histopathology determined that no residual cancer was present (e). Clinical assessment 5 years post treatment revealed that there was no recurrence

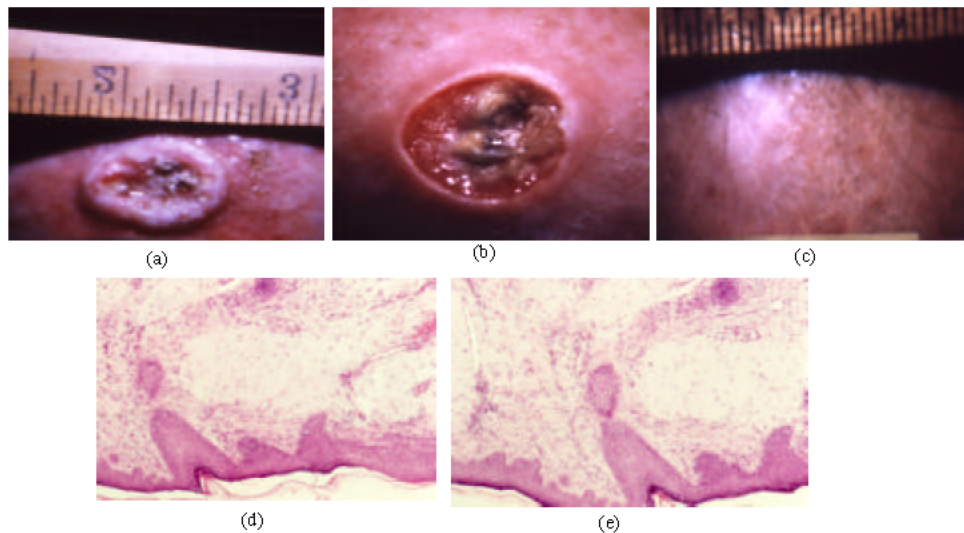


Fig. 16: SCC showing the effectiveness of Curaderm to specifically target cancer cells without affecting normal cells. Before Curaderm treatment (a), during Curaderm treatment (b) and after treatment (c). Treatment duration was 8 weeks. The clinical diagnosis was confirmed histologically by punch biopsy (d). After completion of the therapy histopathology determined that no residual cancer was present (e)

entire area of the surgically excised skin were analysed histologically. There were no traces of residual SCC in the surgically removed tissue. Thus, Curaderm had already removed the cancer altogether. Figure 20 shows the unnecessary surgically treated area containing no cancer

with concomitant skin grafting. Table 1 shows the histopathological analyses of the surgically removed tissue.

Large aggressive invasive BCCs and SCCs have been successfully treated with BEC. In addition, similar lesions

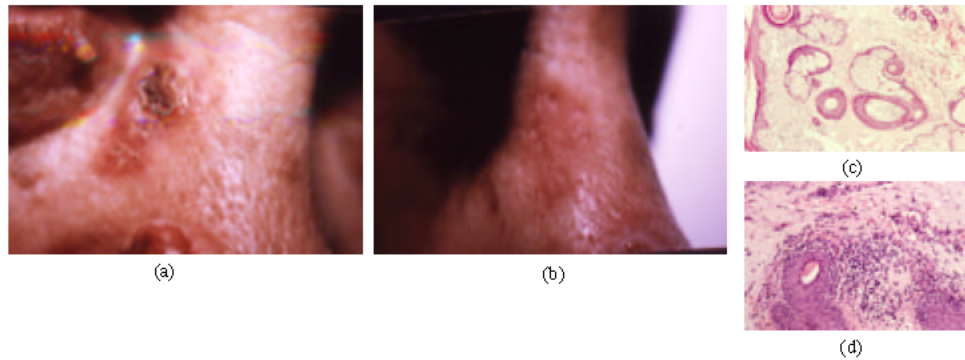


Fig. 17: SCC on the nose close to the eye (a). This SCC was starting to impair the vision of the patient. After Curaderm therapy the lesion was ablated (b). After completion on treatment the vision was restored. Treatment duration was 10 weeks. The clinical diagnosis was confirmed histologically by punch biopsy (c). After completion of the therapy histopathology determined that no residual cancer was present (d). Clinical assessment 5 years post treatment revealed that there was no recurrence

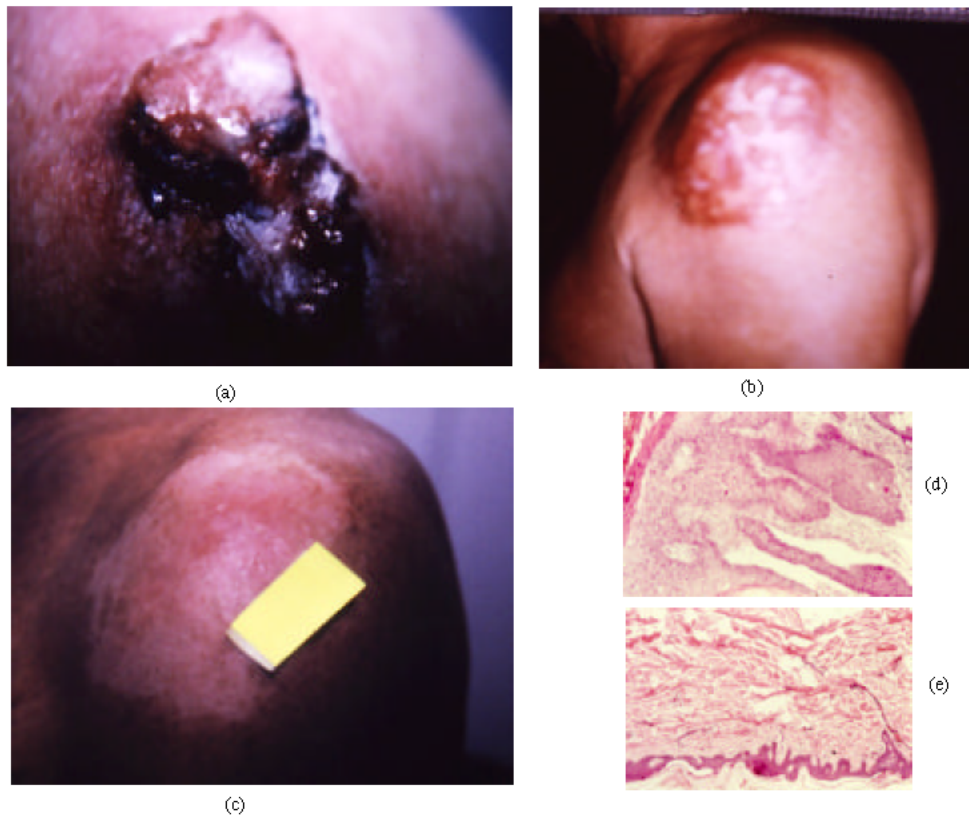


Fig. 18: A large SCC (approximately 8cm x 6cm) on the shoulder of a patient before (a), during (b) and after (c) treatment with Curaderm. After 10 weeks the tumour was completely healed. The clinical diagnosis was confirmed histologically by punch biopsy (d). After completion of the therapy histopathology determined that no residual cancer was present (e). Clinical assessment 5 years post treatment revealed that there was no recurrence

at areas considered difficult to treat such as around the eyes, in the ear and on the nose were equally successfully

treated. The period of treatments observed with the current studies were longer than previously reported

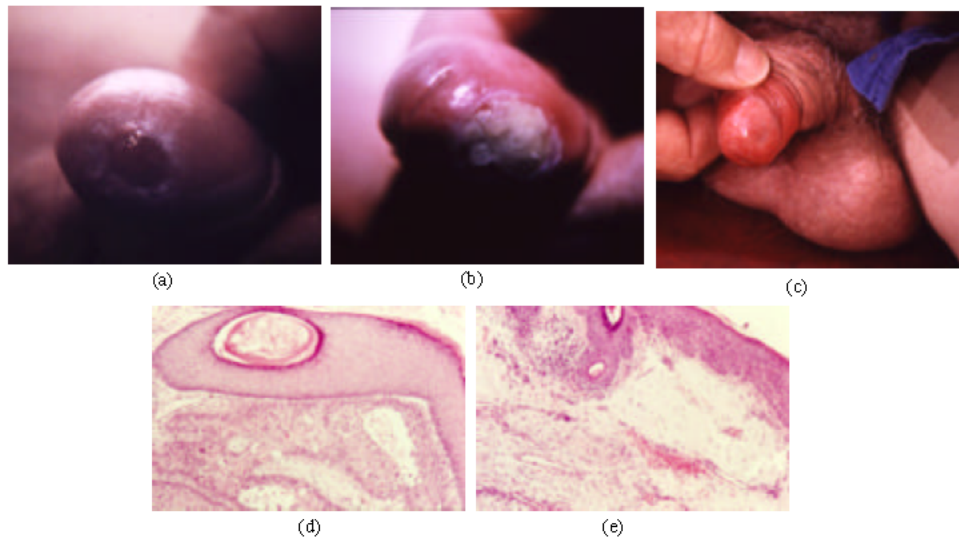


Fig. 19: An intra-epithelial SCC on the penis of a patient before (a), during (b) and after Curaderm therapy (c). The prognosis of this patient before treatment with Curaderm was amputation. Treatment period was 6 weeks. The clinical diagnosis was confirmed histologically by biopsy (d). After completion of the therapy histopathology determined that no residual cancer was present (e). Clinical assessment 5 years post treatment revealed that there was no recurrence

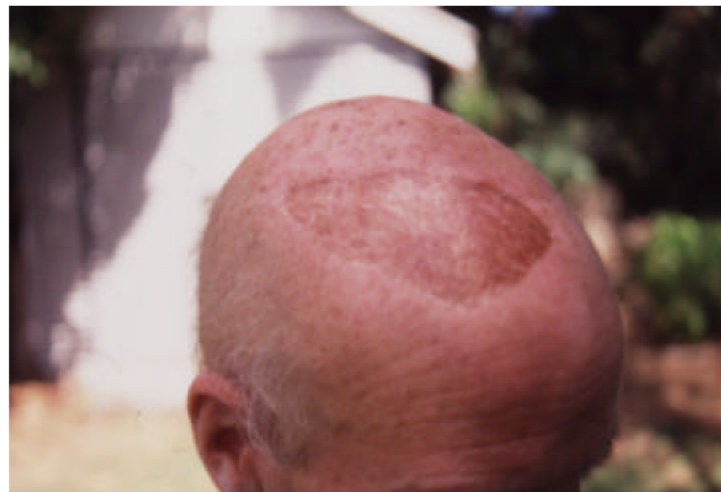

Fig. 20: Skin graft of a surgically removed area which the dermatologist assumed had residual cancer after Curaderm therapy. This patient is represented by Fig. 16. Analysis of the surgically removed area of the skin revealed that there was no residual cancer present (see Table 1), thus this patient underwent unnecessary surgery and skin grafting. Curaderm had already successfully removed all cancer cells prior to skin graft surgery

studies (Cerio and Punjabi, 2002; Cham and Meares, 1987; Cham *et al.*, 1991; Punjabi *et al.*, 2000). This is not surprising because the lesions in this study were much larger than those previously reported. Follow-up periods for over 5 years strongly indicate that the lesions were completely removed by Curaderm therapy. All treated

lesions were effectively treated with Curaderm. No side effects were observed during Curaderm therapy. The cosmetic end result was excellent.

These studies confirm previous efficacy and safety studies of Curaderm (Cerio and Punjabi, 2002; Cham, 1988, 1989, 1991, 1993, 1994, 2007; Cham and Daunter, 1990 b;

Table 1: Histopathology report of the patient described in Fig.16 and 20
Queensland health pathology service-princess alexandra hospital

Patient locatlnn consultant	A3 - Cllnl's Theile, David R. (PAH)	UR no Name	PA813681roberts
Requesting MO	Dr David R. Theile Princess Alexandra Ipswich Road Wooloongabba Q 4102	Given Name DOB Patient Address	Alan Leslie 18-Jun-1944 Boundary Creek Road Bentley NSW 2480 I
Collected	17-Dec-99	Lab No 1922-4391	
Histopathology report	Biopsy No:		
Macroscopic by Dr T Robertson	Clinical notes: Frozen sections SCC poorly differentiated? J~ateral margin clear- Macroscopic descript,ron:6 specimens received. Specimen labelled "right anterior" and consists of a skin ellipse meas. 20×3×5 mm. Blocked in toto block A for froz. Sect. Frozen sections diagnosis: IB/RAA no evidence of malignancy. Specunen 2 labelled "right posterior" and consists of skin ellipse meas. 25×3×3 mm. Blocked in toto block B for frozen sect. Frozen sections diagnosis: IBfRAA no evidence of malignancy. Specimen 3 labelled "left anterior" and consists of a skin ellipse meas. 25×3×5mm. Blocked in toto block C for frozen sect. Frozen sections diagnosis: IB/RAA no evjdence of malignancy. Specimen 4 labelled "left posterior" alld consjsts of a skin ellipse meas. 25×3×51nffi. Blocked in toto block D for frozen sect. Frozen sections diagnosis: IB/RAA no evidence of malignancy. Specimen 5 labelled "SCC scalp, long anterior, short right lateral" and consists of a tear drop shaped portion of skin meas. 85mm anterior to posterior by 45mm right to left. In the centre of the specimen is an irregular shaped elongated focally ulcerated plaque mea.!. 63×28mm. The specimen is inked in blue and the right lateral margin scored. Sectioning the tissue reveals poorly defined induration which appears to extend into subcutis. Sunlmary of sects. E 3 LS-12 o'clock; F to L 7 TS blocked from anterior to posterior; M 2 LS to 6 o'clock. Specimen 6 labelled "skin lesion posterior scalp" and consists of an ovalofskill meas. 50×42×4mm with a central poorly defined area of induration showing depression meas. 35×22mm. A marker suture is present at Olle point which is orientated to posterior (6 o'clock). The 12 o'clock margin is scored. Summary of sccs. N-P 3 TS; Q 3 LS to 3 o'clock; R 3LS to 9 o'clock. (bp) Microscopic description: 1-4. Paraffin sections confirm the frozen section diagnosis and show no evidence of malignancy in any of the 4 specimens. 5. Tile sections show an extensjve area of superficial ulceration of the skin with scale crust and intense subjacent chronic inflammation with numerous plasna cells a.'sociated with dennial scarring. Focal solar keretosis is present on the adjacent skin. There is no evidence of any malignancy in several 6. The sections show foci of superficial ulceration with scale crust and subjacent mild to moderate chronic inflammation and scarring. Tllere is no evidence of malignancy in several sections. Summary: Non-specific chronic ulceration of skin of scalp. No evidence of malignancy. {ra) Dr TE Robertson, Dr RA Axelsen		

Cham and Meares, 1987; Cham *et al.*, 1987; Cham *et al.*, 1991; Evans *et al.*, 1989; Punjabi *et al.*, 2000; Walsh, 2000) and extend the scope of treatment for non-melanoma skin cancers with this preparation. These studies also corroborate previous studies where Curaderm was applied topically to exposed skin cancers and selectively necrotized the tumour cells or induced them to undergo apoptosis or necrosis without causing damage to the surrounding healthy skin cells. The current observations authenticate cell, tissue and whole animal studies where it was shown that solasodine rhamnosyl glycosides were specific for killing cancer cells without harming normal cells due to unique modes of action.

CONCLUSION

Solasodine rhamnosyl glycosides in a cream formulation is very effective for treating BCCs and SCCs. The cosmetic end results are excellent. The reasons for efficacy and cosmetic superiority when compared to other treatment modalities, such as surgery as shown in this communication, are the specificities these glycoalkaloids have for killing cancer cells without adversely affecting normal cells.

ACKNOWLEDGEMENT

I thank Ms. T.R. Chase for secretarial research.

REFERENCES

- Amalfi, C., 2006. The little mouse who wouldn't say die. *Cosmos Mag.*, pp: 471.
- Badami, S., S.A. Manohara Reddy, E.P. Kumar, P. Vijayan and B. Suresh, 2003. Antitumour activity of total alkaloid fraction of *Solanum pseudocapsicum* leaves. *Phytother. Res.*, 17: 1001-1004.
- Cerio, R. and S. Punjabi, 2002. Clinical appraisal of BEC5. *Barts and The London NHS.*
- Cham, B.E., 1988. Monograph on the compound BEC. *Drugs of the Future*, 13: 714-716.
- Cham, B.E., 1989. Plants yield skin cancer cure. *Aus. Tech. Rev.*, 2: 53.
- Cham, B.E., 1989. Curaderm (antineoplastic). Launched in Australia. *Drug News and Perspec.*, 2: 112.
- Cham, B.E., 1991. Solasodine Glycosides: A New Modality for Cancer. In *Proc. 2nd Oceania Symposium. (Ed.) Mark S. Walker. Bioconcepts Publ.*, pp: 30-36.

- Cham, B.E., 1993. Efficacy and Mode of Action of Solasodine Glycosides (BEC) on Cancer Cells. In Proc. 4th Oceania Symposium. Mark S. (Ed.), Walker. Bioconcepts Publ., pp: 41-51.
- Cham, B.E., 1994. Solasodine glycosides as anti-cancer agents: Pre-clinical and clinical studies. Asia Pacif. J. Pharmacol., 9: 113-118.
- Cham, B.E., 2007. Solasodine rhamnosyl glycosides specifically bind cancer cell receptors and induce apoptosis and necrosis. Treatment for skin cancer and hope for internal cancers. Res. J. Biol. Sci., 2: 503-514.
- Cham, B.E. and B. Daunter, 1990 a. Solasodine glycosides. Selective cytotoxicity for cancer cells and inhibition of cytotoxicity by rhamnose in mice with sarcoma 180. Cancer Lett., 55: 221-225.
- Cham, B.E. and B. Daunter, 1990b. Topical treatment of pre-malignant and malignant skin cancers with Curaderm. Drugs of Today, 26: 55-58.
- Cham, B. E., B. Daunter and R. Evans, 1991. Topical treatment of malignant and premalignant skin cancers by very low concentrations of a standard mixture of solasodine glycosides. Cancer Lett., 59: 183-192.
- Cham, B.E. and H.M. Meares, 1987. Glycoalkaloids from *Solanum sodomaeum* L. are effective in the treatment of skin cancers in man. Cancer Lett., 36: 111-118.
- Chang, L.C., T.R. Tsai, J.J. Wang, C.N. Lin and K.W. Kuo, 1998. The rhamnose moiety of solamargine plays a crucial role in triggering cell death by apoptosis. Biochem. Biophys. Res. Commun., 242: 21-25.
- Daunter, B. and B.E. Cham, 1990. Solasodine glycosides. *In vitro* preferential cytotoxicity for human cancer cells. Cancer Lett., 55: 209-220.
- Esteves-Souza, A., T. Sarmento da Silva, C.C.F. Aloes, M. Carvalho, R. Braz-Filho and A. Echevarria, 2002. Cytotoxic activities against Ehrlich carcinoma, Human K562 Leukaemia of alkaloids and flavonoids from two *Solanum* species. J. Braz. Chem. Soc., 13: 838-842.
- Evans, R., B.E. Cham and B. Daunter, 1989. Letter to the Editor. Your Pharmacy.
- Kuo, K.W., S.H. Hsu, Y.P. Li, W.L. Lin, L.F. Liu, L.C. Chang, C.C. Lin, C.N. Lin and H.M. Sheu, 2000. Anticancer activity evaluation of the *Solanum* glycoalkaloid solamargine. Triggering apoptosis in human hepatoma cells. Biochem. Pharmacol., 60: 1865-1873.
- Kuo, K.W. and C.N. Lin, 1999. Pharmacological composition for treating cancer cells. United states Patent, 6: 214, 803.
- Lee, K.R., N. Kozukue, J.S. Han, J.H. Park, E.Y. Chang, E.J. Back, J.S. Chang and M. Friedman, 2004. Glycoalkaloids and metabolites inhibit the growth of human colon (HT29) and liver (HepG2) cancer cells. J. Agric. Food. Chem., 52: 2832-2839.
- Liang, C.H., L.F. Liu, L.Y. Shiu, Y.S. Huang, L.C. Chang and K.W. Kuo, 2004. Action of Solamargine on TNFs and cisplatin-resistant human lung cancer cells. Biochem. Biophys. Res. Commun., 322: 751-758.
- Liu, L.F., C.H. Liang, L.Y. Shiu, W.L. Lin, C.C. Lin and K.W. Kuo, 2004. Action of Solamargine on human lung cancer cells-enhancement of the susceptibility of cancer cells to TNFs. FEBS. Lett., 577: 67-74.
- Millward, M., A. Powell, P. Daly, S. Tyson, R. Ferguson and S. Carter, 2006. Results of phase I clinical trials of coramsine in patients with advanced solid tumors. J. Clin. Oncol., 24: 2070.
- Nakamura, T., C. Komori, Y. Lee, F. Hashimoto, S. Yahara, T. Nohara and A. Ejina, 1996. Cytotoxic activities of *Solanum* steroidal glycosides. Biol. Biopharm. Bull., 19: 564-566.
- Ono, K., S.O. Kin and J. Han, 2003. Susceptibility of lysosomes to rupture is a determinant for plasma membrane disruption in tumor necrosis factor alpha-induced cell death. Mol. Cell. Biol., 23: 665-676.
- Punjabi, S., I. Cook, P. Kersey, R. Marks, A. Finlay and G. Sharpe *et al.*, 2000. A double blind, multi-centre parallel group study of BEC-5 cream in basal cell carcinoma. Eur. Acad. Dermatol. Venereol. 14: 47-60.
- Roddick, J.G., A.L. R yrenber and M. Weissenber, 1990. Membrane-disrupting properties of the steroidal glycoalkaloids Solasonine and Solamargine. Phyto. Chem., 29: 1513-1518.
- Roddick, J.G., M. Weissenberg and A.L. Leonard, 2001. Membrane-disruption and enzyme inhibition by naturally-occurring and modified chaco-triose-containing *Solanum* steroidal glycoalkaloids. Phyto. Chem., 58: 603-610.
- Solbec Pty Ltd. <http://www.solbec.com.au>.
- Sussman, L.A.E. and D.F. Liggins, 1996. Incompletely excised basal cell carcinoma: A management dilemma? Aus. NZ. J. Surg., 66: 276-278.
- Verpoorte, R., 1998. Exploration of nature's chemodiversity: The role of secondary metabolites as leads in drug development. Drug Discov. Today, 3: 232-238.
- Vijayan, P., S. Vinod Kumar, S.A. Dhanaraj, S. Badami and B. Suresh, 2002. *In vitro* Cytotoxicity and Anti-tumour Properties of the Total Alkaloid Fraction of Unripe Fruits of *Solanum pseudocapsicum*. Pharmaceut. Biol., 40: 456-460.
- Walsh, N., 2000. Promising Topical Therapy for Actinic Keratoses-Brief Article Dr S Punjabi. Uni. Liverpool. Family Practice News.
- Yoshikawa, M., S. Nakamura, K. Ozaki, A. Kumahara, T. Morikawa and H. Matsada, 2007. Structures of steroidal alkaloid oligoglycosides, robencosides A and B and antidiabetogenic constituents from the Brazilian medicinal plant *Solanum lycocarpum*. J. Natl. Prod., 70: 210-214.