

Evaluation of Characteristics of Patients with Pilomatricoma in Mazandaran Province, 1996-2006

Masoud Golpour

Department of Dermatology, BooAli-Sina Hospital,
Mazandaran University of Medical Science, Sari, Iran

Abstract: Pilomatricomas are benign cutaneous neoplasm that occur frequently in children and usually present as slow-growing, firm, dermal nodules. About 60% said to arise in patients less than 20 years of age. In this study, 46 case of pilomatricoma, with asymptomatic, single and firm nodule referred to dermatology clinic of Boo-Ali Sina hospital in Sari (1996-2006). A biopsy was taken from suspicious lesions and histopathology assessments were done for cases with pilomatricoma impression. 69.56% patients were female. Mean age of the patients was 20.1 years. The most frequent sites of the tumor were the forearm (41.30%).

Key words: Evaluation, characteristics of patientsm pilomatvicoma, biopsy, histopathology

INTRODUCTION

Pilomatricoma is a benign cutaneous neoplasm with differentiation toward hair matrix, that occurs frequently in children (Kaddu *et al.*, 1994; Holme *et al.*, 2001). Pilomatricoma usually manifests as a solitary, asymptomatic and firm nodule, but some reported pain during episodes of inflammation (Rao and Lin, 2006). Internationally, 15 patients with pilomatricoma were seen in a pediatric surgery clinic in Turkey from 1984-1994 (Demircan and Balik, 1997). Cigliano presents 83 patients with pilomatricoma during a 7-year period (1996-2002) at the departments of Pediatrics, University Hospital "Federico II", Naples, Italy (Cigliano *et al.*, 2005). Kaddu *et al.* (1994) studied 118 patients admitted at department of dermatology in Australia between "1980-1990". Diagnosis of pilomatricoma is difficult and the final confirmation is by histological examination (Punia *et al.*, 2001). Because preoperative diagnosis of pilomatricoma is usually incorrect, careful clinical examination and a high index of suspicion would result in a more accurate diagnosis (Lan *et al.*, 2003). This study presents 46 cases of pilomatricoma. Principle characteristic clinical presentations of this tumor are discussed.

MATERIALS AND METHODS

In this descriptive study, patients with asymptomatic, single and firm nodule referred to dermatology clinic of boo-Ali Sina hospital in Sari, Iran (1996- 2006) were assessed. Biopsy was taken from suspicious lesions and histopathology assessments were done for cases with pilomatricoma impression (Fig. 1 and 2). Demographic data, clinical finding, the site, size, color and malignant

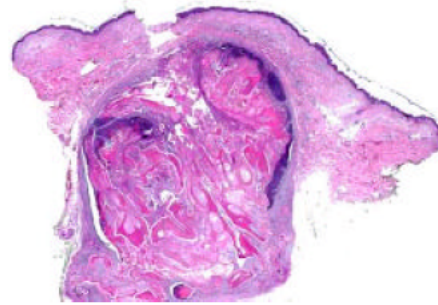


Fig. 1: Very low power view (direct scan of glass slide). Multiple types of keratinization plus a mixture of epithelial elements produce a swirled or geographic appearance at this power

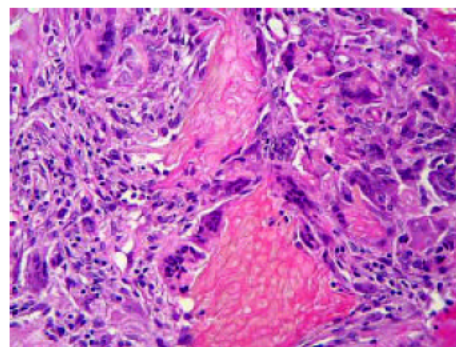


Fig. 2: A high power view. Ghost cells (shadow cells) are associated with a granulomatous reaction. The ghost cells have a yellowish cast and this is common in this type of keratin

deformity of lesions were evaluated. The results were descriptively analyzed using χ^2 test with SPSS11.

Table 1: Frequency distribution of the location in 46 cases with pilomatricoma referred to Boo Ali Sina hospital, Sari, Iran during 1996-2006

Location	Frequency
Forearm	19(41.3%)
Arm	8(17.39%)
Neck	4(8.69%)
Eyelid	2(4.34%)
Face	2(4.34%)
Leg	2(4.34%)
Thigh	2(4.34%)
Scalp	1(2.17)
Others	4(8.69%)

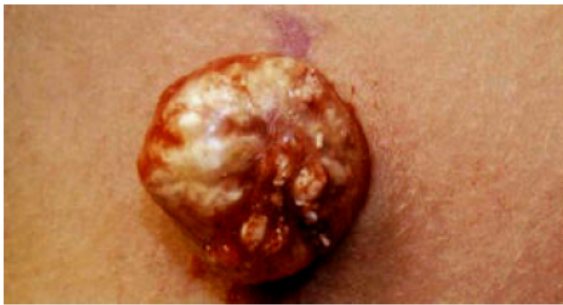

Fig. 3: The most common lesions color was cream

RESULTS

In this study, we presented 46 cases of pilomatricoma. These cases were recognized from a total of 2470 dermal biopsies taken in dermatology ward of Boo-Ali Sina hospital sari, Iran from 1996- 2006. Thirty two (69.56%) patients were female and 14 (30.44%) male. Mean age of the patients was 20.1 years (range 2- 68 years). The most common age group was 11-20 years. The most frequent sites of the tumor were the forearm (41.30%) arm (17.39%). (Table 1).

The color of lesions was cream 12 (26.08%) (Fig 3), brown 6 (13.04), light cream 9 (19.56%), gray 9 (19.56%); skin color 4 (8.6%), light red 1 (2.1%), brown 1 (2.1%) and white 1 (2.1%).

The size of most of the lesions was 0.85 cm, the largest size was 4cm and the smallest was 0.1 cm seen in scalp and arm, respectively. In biopsy study, 22 cases had calcification. None of the cases had malignancy.

DISCUSSION

Pilomatricoma is a skin appendage tumor that frequently involves the skin of the head, neck and upper extremities in young children (Demircan *et al.*, 1997). In a study by Cigliano, female/male ratio was 2: 1 (Cigliano *et al.*, 2005) and in Jjaggi's review article, female to male ratio in 209 cases was 1.5: 1 (Demircan *et al.*, 1997),

but Lan *et al.* (2003) reported 0.97:1. In our study, this ratio was 2.5 pilomatricoma can occur at any age (Lan *et al.*, 2003). However, most reported cases have occurred in children (1-4) and it is a rather uncommon neoplasm in middle- age and old patients (Behnke *et al.*, 1998). Mean age in our study was 20.1 years (range: 2y- 68y). The most common age group was 11- 20 y. Jaggi found a bidominal pattern for age presentation: The first peak beings at 5-15 years and the second beings at 50- 65 years (Kaddu *et al.*, 1994; Rao and Lin, 2006).

Based on the literature the tumors occur mainly on the head and neck regions (Pulvermacker *et al.*, 2006; Pirouzmanesh *et al.*, 2005; Rao and Lin, 2006; Darwish *et al.*, 2001; Punia *et al.*, 2001) which is similar to our results. Head and neck were the most common location of the tumor reported by kumaran 73.31% and cigliano 56.5% (Kumaran *et al.*, 2006; Cigliano *et al.*, 2005). In our study, the most common site was upper limb though (58.69%).

The lesions have usually normal skin color but reddish purple lesions were observed (probably resulting from hemorrhage) (Rao and Lin, 2006). In this study, the cream was the most common color (26%).

In several studies, tumor size ranged between 3-43 mm (Kumaran *et al.*, 2006; Lan *et al.*, 2003; Darwish *et al.*, 2001; Rao *et al.*, 2006), we obtained a result. Varying amount of calcification was recorded in other studies (Darwish *et al.*, 2001). Demircan claimed that all cases had calcification in histopathology examination (Demircan *et al.*, 1997) but Kumaran and Jjaggy reported 91 and 75%, respectively. (Kumaran *et al.*, 2006; Rao and Lin, 2006). In the subjects of this study was 49%. Pilomatrical carcinoma is uncommon (Rao and Lin, 2006). No invasive or malignancy lesion was observed by light microscopy (Demircan *et al.*, 1997). In our study, no malignancy observed too.

Because preoperative diagnosis of pilomatricoma is usually difficult, careful clinical examination and a high index of suspicion would result in a more accurate diagnosis. Complete surgical excision is the treatment of choice.

CONCLUSION

We concluded, because the pilomatricoma is a benign cutaneous neoplasm with differentiation toward hair matrix, so that it is not seen in palm or plantar surface, but could present in any other area. Since, few of pilomatricoma lesions converted to malignant, so that it is better we resects total lesion by surgical excision.

REFERENCES

- Behnke, N., K. Schulte, T. Ruzicka and M. Megahed, 1998. Case Report Pilomatricoma in Elderly Individuals. *Dermatology*, 197: 391-93.
- Cigliano, B., N. Baltogiannis, M. De Marco, E. Faviou, A. Settimi and S. Tilemis *et al.*, 2005. Pilomatricoma in childhood: A retrospective study from three European paediatric centres. *Eur. J. Pediatr.*, 164: 673-677.
- Darwish, A.H., E.K. Al-Jalahema, A.K. Dhiman and K.A. Al-Khalifa, 2001. Clinicopathological study of pilomatricoma. *Saudi Med. J.*, 22: 268-271.
- Demircan, M. and E. Balik, 1997. Pilomatricoma in children: A prospective study. *Pediatr. Dermatol.*, 14: 430-432.
- Holme, S.A., S. Varma and P.J. Holt, 2001. The first case of exophytic pilomatricoma in an Asian male. *Pediatr. Dermatol.*, 18: 498-500.
- Kaddu, S., H.P. Soyer, L. Cerroni, W. Salmhofer and S. Hodl, 1994. Clinical and histopathologic spectrum of pilomatricomas in adul. *Int. J. Dermatol.*, 33: 705-708.
- Kumaran, N., A. Azmy, R. Carachi, P.A. Raine, J.H. Macfarlane and A.G. Howatson, 2006. Pilomatricoma: Accuracy of clinical diagnosis. *J. Pediatr. Surg.*, 41: 1755-1758.
- Lan, M.Y., M.C. Lan, C.Y. Ho, W.Y. Li and C.Z. Lin, 2003. Pilomatricoma of the head and neck: A retrospective review of 179 cases. *Arch. Otolaryngol. Head Neck Surg.*, 9: 1327-1330.
- Pirouzmanesh, A., J.F. Reinisch, I. Gonzalez-Gomez, E.M. Smith and J.G. Meara, 2005. Pilomatricoma: A review of 346 cases. *Plast. Reconst. Surg.*, 115: 1783.
- Pulvermacker, B., D. Seroussi, R. Haddad and M. Mitrofanoff, 2006. Pilomatricoma or calcifying epithelioma of Malherbe. A pediatric review of 89 cases. *Ann Chir. Plast. Esthet.*, [Epub ahead of print].
- Punia, R.P., A. Palta, A.J. Kanwar, G.P. Thami, R. Nada and H. Mohan, 2001. Pilomatricoma-a retrospective analysis of 18 cases. *Ind. J. Pathol. Microbiol.*, 44: 321-424.
- Rao, J. and L. Lin, 2006. Pilomatricoma. *Health on the Net Foundation*, pp: 1-10.