

Cerebral Lesions Diagnosed by Fluid Attenuated Inversion Recovery (FLAIR) Imaging in Epileptic Patients

¹M. Pourissa, ²S. Refahi, ¹K. Hosseinzadeh and ²M.H. Dehghan

¹Tabriz University of Medical Sciences, Tabriz, Iran

²Ardebil University of Medical Sciences, Ardebil, Iran

Abstract: The purpose of this study was to illustrate the spectrum of cerebral lesions diagnosed by Fluid Attenuated Inversion Recovery (FLAIR) imaging in patients with epilepsy. A retrospective study was conducted on 104 patients with epilepsy who had undergone brain MRI with fluid attenuated inversion recovery sequence at the MRI center of Sheikholraisi clinic, Tabriz, Iran. Abnormalities scans were acquired in 66(63.5%) patients. Space Occupying Tumors (SOT) was detected in 25(24%) patients, Vascular Malformations (VM) in 17(16.35%) patients, hippocampal sclerosis in 7(6.8%) patients, Scars of Old Lesions (SOL) in 7(6.8%) patients, multiple sclerosis in 4(3.85%) patients, malformations of cortical development in 2(1.9%) patients and other in 4(3.85%) patients. The most frequent lesions were Space Occupying Tumors (SOT), followed, in decreasing order by Vascular Malformations (VM) and Hippocampal Sclerosis (HS). The most common tumors were low-grade gliomas.

Key words: Fluid Attenuated Inversion Recovery (FLAIR), epilepsy, cerebral lesions

INTRODUCTION

Epilepsies represent frequent neurologic disorders that affect approximately 1% of the population worldwide (Fisher *et al.*, 2005; Elger, 2002). Neuroimaging has an important role in the investigation and treatment of patients with epilepsy. Neuroimaging techniques include Computed Tomography (CT) and Magnetic Resonance Imaging (MRI), although CT has a diminished role for diagnosis, MRI is the most appropriate imaging technique in the initial investigation of patients with epilepsy (Kuzniecky and Knowlton, 2002). The imaging of epilepsy has vastly changed in the last 15 years (Erasmio and Ramon, 2006). Fluid Attenuated Inversion Recovery (FLAIR) images can identify structural abnormalities such as Hippocampal Sclerosis (HS) and Malformations of Cortical Development (MCD) in up to 80% of patients with epilepsy (Salmenpera *et al.*, 2007). The use of Fluid Attenuated Inversion Recovery (FLAIR) MRI has been recommended in the presurgical evaluation of patients with epilepsy (Diehl *et al.*, 1999). Detection of structural brain abnormalities is a main aim of physicians. The focus of this study was to demonstrate cerebral lesions in epileptic patients using FLAIR MRI.

MATERIALS AND METHODS

From Mars 2006-Mars 2007, 4760 patients were referred to MRI center of the Sheikholraisi clinic, Tabriz,

Iran. We retrospective collected data of 158 patients had a history of seizure. Among these patients, 104 patients had MRI for the brain performed with Fluid Attenuated Inversion Recovery (FLAIR) sequence and 54 were excluded on the basis of MRI examinations of other organs else of brain. Selected patients were 58 (56%) men, 46 (44%) women and their age ranged from 5 to 83 years with an average age of 32.6 years. FLAIR MR imaging was performed using a Hitachi IRIS II MRI unit with a 0.3 Tesla magnet. Scanning was performed in the sagittal and coronal plane with 5 mm thickness slices and 2 mm interslice gaps. Each MRI was assessed by two reviewers, one a neurologist and the other a neuroradiologist. Both reviewers assessed the images together during a single session. The FLAIR MRI findings summarized in the part of results.

RESULTS

We studied medical reports of 104 patients with a history of seizure (58M, 46F; M/F ratio, 1.26:1), with a mean age of 32.6 (5-83) years. Chief Complaint (CC) was seizure in 74 (71.2%) cases and headache, vertigo, Cerebrovascular Accident (CVA) in 30 (28.8%) cases. In total, 38 of 104 patients (36.5%) had no visible abnormalities on MR images. MRI findings were abnormal in 66 out of 104 patients (63.5%). Lesions distribution according to age the of patients illustrated in (Fig. 1).

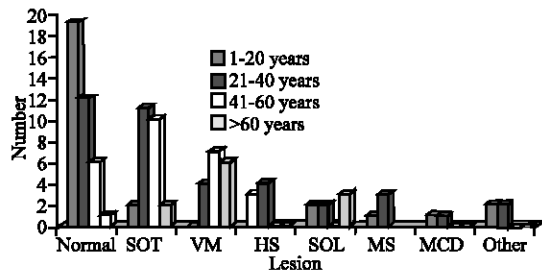


Fig. 1: Distribution of lesions according to age of patients SOT: Space Occupying Tumors, VM; Vascular Malformations, HS: Hippocampal Sclerosis, SOL: Scars of Old Lesions, MS: Multiple Sclerosis, MCD: Malformations of Cortical Development

Table 1: Lesion categories

Lesion category	n	(%)
Space Occupying Tumors (SOT)	25	24.03
Vascular Malformations (VM)	17	16.35
Hippocampal Sclerosis (HS)	7	6.73
Scars of Old Lesions (SOL)	7	6.73
Multiple Sclerosis (MS)	4	3.85
Malformations of Cortical Development (MCD)	2	1.92
Other	4	3.85
No lesions	38	36.53

With respect to the MRI diagnoses we divided the lesions into the following categories (Table 1). Our results showed that space occupying tumors were the most common finding on MR images, followed by vascular malformation, hippocampal sclerosis and scars of old lesions.

The details of space occupying tumors were as followed: Low-grade glioma in 8/25 (32%) cases, glioblastoma multiform in 1/25 (8%) cases, post operative changes in 2/25 (8%), meningioma in 2/25 (8%) cases, cystic lesions in 3/25 (12%) cases (arachnoid cyst in two cases and interventricular cyst in one case), cerebellum tumors in 2/25 (8%) cases, hemorrhagic calcificated mass in 1/25 (4%) case, metastasis tumors in 2/25 (8%) cases and recurrence tumor in 4/25 (16%) cases.

Space occupying tumors were located on the frontal lobes in 7 (28%) cases, parietal lobes in 5 (20%) cases, temporal lobes in 3 (12%) cases, frontoparietal lobes in 4 (16%) cases, cerebellum in 2 (8%) cases, left lateral ventricle in 2 (8%) cases and middle fossa in one (4%) case.

DISCUSSION

Epilepsy is the most common neurological disorders: at and one time 7 in 1000 people in the general population have epilepsy. Prompt, accurate diagnosis with appropriate social and medical management will optimize the situation (Blume and Warren, 2003). For many years, electroclinical findings were used to help in diagnosing

and managing patients with epilepsy. The advent of modern neuroimaging techniques has reversed this situation and improved the ability to detect the structural basis of the seizure disorder (Mohamed *et al.*, 2006). FLAIR MRI an important neuroimaging technique in the assessment of epilepsy but is not available in all imaging centers. The structural abnormalities detected on MRI can be categorized into tumors, cortical dysgenesis, vascular malformations, hippocampal sclerosis, infarct/gliososis and other miscellaneous findings (Spencer, 1994). In our study 63.5% of patients had abnormal scans. In the previous studies rate abnormalities were accounted in 51% (Wieshmann, 2003), 40% (Taillibert *et al.*, 1999) and 56% (Bergin *et al.*, 1995). In this approach cerebral space occupying tumors were detected in 25 patients (24%). In seven of twenty five patients, tumors were located in the frontal lobes (28%). Low-grade glioma was the most common tumors. Erasmo and Ramon (2006) in their studies showed that rate of tumors was 20% and include low-grade astrocytic tumors, oligodendroglioma and ganglioglioma (Erasmo and Ramon, 2006). In another study, in UK tumors made up 9.9% of abnormalities in epileptic patients (Wieshmann, 2003). In article reported by Lefkopoulos *et al.* (2005) cerebral tumoral, mass lesions were detected in 10% of patients. Half of them were located in the temporal lobe (50%) (Lefkopoulos *et al.*, 2005). In another study, that focused on epileptic patients, tumors only represented 16.7% of the total lesions (Li *et al.*, 1994). King *et al.* (1998) found that 50% of lesions detected on MRI were tumors (King *et al.*, 1998). The other findings observed in our study were a high rate of vascular malformations (16.35%). Lefkopoulos (2005) reported vascular malformation in 7.5% of patients that include arteriovenous Angiomas (AVMs) and Cavernous Angiomas (CAs) (Lefkopoulos *et al.*, 2005). Correlative studies showed vascular abnormalities in 10.7, 9.52% cases (Wieshmann, 2003; Urbach *et al.*, 2007). Hippocampal sclerosis is routinely seen on T1 sequences (as atrophy and loss of volume), on T2 sequences (as high signal) and on Fluid Attenuated Inversion Recovery (FLAIR) imaging (Stefan *et al.*, 2001). Hippocampal atrophy and increased signal are not always seen together in the epileptic patients. For example, some patients have increase FLAIR signal or T2 signal without accompanying atrophy (Erasmo and Ramon, 2006). Lefkopoulos *et al.* (2005) and Erasmo and Ramon (2006) reported rate HS in their patients by 25% (Lefkopoulos *et al.*, 2005; Erasmo and Ramon, 2006). Sensitivity of FLAIR MRI in detecting of HS reported 90% (Lefkopoulos *et al.*, 2005). In Wieshmann's (2003) study HS were detected in one-third of all patients with epilepsy (Wieshmann, 2003). Lehericy *et al.* (1997) found that 55% of 222 epileptic patients had HS (Lehericy *et al.*, 1997). Current research showed that hippocampal sclerosis was observed in 6.73% cases. All of them were located on the right side of brain.

Malformations of cortical development in our results were seen in low percentage of patients (1.92%) that consisted of heterotopy and pachygyria. In Erasmo and Ramon's study (2006) this lesion was presented in 21% of cases (Erasmo and Ramon, 2006) and in Wieshmann's (2003) study in 5.15% cases (Wieshmann, 2003). In the other study, done by Lefkopoulos *et al.* (2005) 19.23% of cases showed malformations of cortical development that consisted of cortical dysplasias, pachygyrias, polymicrogyrias, subcortical heterotopias, tuberous sclerosis (Lefkopoulos *et al.*, 2005). Scars of old lesions in our study accounted for 6.73% patients. In another study rate of scars of old lesions reported for 9.5% epileptic patients (Urbach *et al.*, 2007). In the present study, we detected multiple sclerosis in 3.85% patients. Other lesions in our study consisted of vasculitis, thrombosis of cavernous sinus, aqueductal stenosis and chial malformation.

CONCLUSION

In conclusion, present study illustrated the most common cerebral lesions in epileptic patients were space occupying tumors, followed by vascular malformations and hippocampal sclerosis.

REFERENCES

- Bergin, P.S., D.R. Fish, S.D. Shorvan, A. Oatridge, N.M. Desouza and G.M. Bydder, 1995. Magnetic resonance imaging in partial epilepsy: Additional abnormalities shown with the Fluid Attenuated Inversion Recovery (FLAIR) pulse sequence. *J. Neurol. Neurosurg. Psychiatry*, 58: 439-43.
- Blume and T. Warren, 2003. Diagnosis and management of epilepsy. *CMAJ Canadian Med. Assoc. J.*, 168: 441-448.
- Beate, D., R. Paul, N. Imad, M. Armin, B. Thomas, Y. Zhong and W. Elaine, 1999. Fluid-Attenuated Inversion-Recovery (FLAIR) MRI Signal Abnormalities Are Correlated with Hippocampal Cell Densities in Patients with Hippocampal Sclerosis and Dual Temporal Lobe Pathology. *Neurol.*, 52 Supplement, 2: A17.
- Elger, C.E., 2002. Epilepsy: Disease and model to study human brain function. *Brain Pathol.*, 12: 193-198.
- Erasmo, A.P. and D.A. Ramon, Neuroimaging in epilepsy surgery. Available in <http://www.emedicine.com/neuro/topic251.htm>.
- Fisher, R.S., W. Van Emde Boas, W. Blume, C. Elger, P. Genton, P. Lee and J. Engel, 2005. Epileptic seizures and epilepsy: Definitions proposed by the International League Against Epilepsy (ILAE) and the International Bureau for Epilepsy (IBE). *Epilepsia*, 46: 470-472.
- King, M.A., M.R. Newton, G.D. Jackson, G.J. Fitt, L.A. Mitchell, M.J. Silvapulle and S.F. Berkovic, 1998. Epileptology of the first-seizure presentation: A clinical, electroencephalographic and magnetic resonance imaging study of 300 Consecutive patients. *Lance.*, 26: 1007-1011.
- Kuzniecky, R.I. and R.C. Knowlton, 2002. Neuroimaging of epilepsy. *Semin Neurol.*, 22: 279-288.
- Lefkopoulos, A., A. Haritanti, E. Papadopoulou, D. Karanikolas, N. Fotiadis and A.S. Dimitriadis, 2005. Magnetic resonance imaging in 120 patients with intractable partial seizures: A preoperative assessment. *Neuroradiology*, 47: 352-361.
- Lehericy, S., F. Semah, D. Hasboun, D. Dormont, S. Clemenceau, O. Granat, C. Marsault and M. Baulac, 1997. Temporal lobe epilepsy with varying severity: MRI study 222 patients. *Neuroradiology*, 39: 788-796.
- Li, L.M., D.R. Fish, S.M. Sisodiya, S.D. Shorvon, N. Alsanjari and J.M. Stevens, 1994. High resolution magnetic resonance imaging in adults with partial or secondary generalized epilepsy attending a tertiary referral unit. *J. Neurol. Neurosurg. Psychiatry*, 59: 384-387.
- Mohamed, Y., N.N. Alias, I.L. Shuaib, J. Tharakan, J. Abdullah, A.H. Munawir, N.N. Naing, 2006. Referral of epileptic patients in North East Coast of West Malaysia an area with poor MRI coverage: An analysis. *Southeast Asian J. Trop. Med. Pub. Health*, 37: 1199-208.
- Salmenpera, T.M., M.R. Symms, F.J. Rugg-Gunn, P.A. Boulby, S.L. Free, G.J. Barker, T.A. Yousry, J.S. Duncan, 2007. Evaluation of quantitative magnetic resonance imaging contrasts in MRI-negative refractory focal epilepsy. *Epilepsia*, 48: 229-237.
- Spencer, S.S., 1994. The relative contributions of MRI, SPECT and PET imaging in epilepsy. *Epilepsia*, 35 Suppl, 6: S72-89.
- Stefan, H., P. Halasz, A. Gil-Nagel, S. Shorvon, G. Bauer, E. Ben-Menachem, E. Perucca, H.G. Wieser and O. Steinlein, 2001. Recent advances in the diagnosis and treatment of epilepsy. *Eur. J. Neurol.*, 8: 519-539.
- Taillibert, S., C. Oppenheim, M. Baulac, D. Dormont, C. Marsault, E.A. Cabanis and A. Tourbah, 1999. Yield of fluid-attenuated inversion recovery in drug-resistant focal epilepsy with noninformative conventional magnetic resonance imaging. *Eur. Neurol.*, 41: 64-72.
- Urbach, H., D. Binder, M. von Lehe, M. Podliger, C.G. Bien, A. Becker, J. Schramm, T. Kral and H. Clusmann, 2007. Correlation of MRI and histopathology in epileptogenic parietal and occipital lobe lesions. *Seizure*. [Epub ahead of print].
- Wieshmann, U.C., 2003. Clinical application of neuroimaging in epilepsy. *J. Neurol. Neurosurg. Psychiatry*, 74: 466-70.