

The Relationship of Age, Gender and Injection Side with Positive Blood Aspiration During the Inferior Alveolar Nerve Block

¹Bargrizan Majid, ¹Tadayon Nikoo and ²Ghasemi Amir

¹Department of Pediatric, ²Department of Restorative,
Dental School, Shahid Beheshti University of Medical Sciences (SBMU), Tehran, Iran

Abstract: The Inferior Alveolar Nerve Block (IANB) is the most frequently used injection technique in dentistry and has the greatest risk of accidental intravascular injection. This study conducted to determine the possible differences in blood aspiration during IANB between different ages, genders and injection sides. Four hundred and thirty four IANB were performed in 2-18 year-old patients by the principal author. Blood aspiration was accepted only if a blood jet rose forcefully along the cartridge on aspiration. Multiple logistic regression analysis was used to estimate the relationship of age, gender and injection side with incidence of positive blood aspiration with alpha value set at 0.05. No significant differences ($p < 0.05$) were observed on contrasting the incidence of positive blood aspiration with the age. However, significant differences were seen on correlating aspiration to the gender and injection side. Blood aspiration was observed in 12.9% of cases. The high incidence of intravascular injection during IANB that we found proves aspiration is necessary regardless of the age of the patient.

Key words: Inferior alveolar nerve block, aspiration, injection side, gender, age

INTRODUCTION

Successful treatment of patients, especially pediatric patients, in terms of allaying their anxiety and discomfort during restorative and surgical procedures is facilitated by profound local anesthesia (Wilson and Montgomery, 2005). The inferior alveolar nerve block (IANB), commonly (but inaccurately) referred to as the mandibular nerve block, is the most frequently used and possibly the most important injection technique in dentistry (Malamed, 2004). When deep operative or surgical procedures are undertaken for the mandibular primary or permanent teeth, the inferior alveolar nerve must be blocked (Mc Donald *et al.*, 2004). The target area for IANB is the inferior alveolar nerve as it passes downward toward the mandibular foramen but before it enters into the foramen. In this injection the inferior alveolar, incisive, mental and lingual nerves are anesthetized (Malamed, 2004). The mandibular foramen, located between 2/3rd-3/4th the distance from the anterior border of the ramus to its posterior border on the medial surface (Bremer, 1952). Other studies of the anteroposterior location of the mandibular foramen have provided differing locations. Hayward and associates found the foramen most often in the third quadrant from the anterior part of ramus

(Hayward *et al.*, 1977). Whereas, Heston and associates locate it at 55% cases distal to the anterior ramus (Heston *et al.*, 1988). The height of this foramen varies greatly, ranging from 1 to 19 mm or more above the level of the occlusal plane (Hayward *et al.*, 1977).

Immediate complications of local anesthesia administration include positive blood aspiration, blanching of the tissue and burning sensation on impingement of the nerve (Lustig and Zusman, 1999). A drug overdose reaction is caused by a level of a drug in the blood sufficiently high to produce adverse effect in various organs and tissues of the body in which the drug exerts a clinical action (Malamed, 2004). A factor in local anesthetic overdose in dentistry is inadvertent intravascular injection. Extremely high drug levels can be reached in a short time, leading to serious overdose reactions. The greater the vascularity of the injection site, the more rapid the absorption of the drug from that area into the circulation. The site for IANB is one of the most highly vascular areas of the entire body (Malamed, 2004).

Although, overdose can occur in persons of any age, individuals at either end of the age spectrum experience a higher incidence of such reaction. The functions of absorption, metabolism and excretion may be imperfectly developed in young persons, thereby increasing the half-

time of the drug, elevating circulating blood levels and increasing the risk of overdose (Prince *et al.*, 1992). Furthermore, the less the body weights of a patient, the smaller the dose of a drug that can be tolerated before overdose reactions occur (Malamed, 2004).

According to some authors, aspiration is not necessary because intravascular injection of local anesthetic is rare (frequency 0.5%). These authors maintained that even if that does happen, the amount of solution contained in 1 anesthetic cartridge (2%, 1.8 mL) is not enough to be toxic (Martiz *et al.*, 1986). However, most authors do not agree with this, however, consider aspiration before an inferior alveolar nerve block to be necessary.

The haemodynamic effects of a local anesthetic with 1:100,000 vasoconstrictor have been studied in healthy people. This concentration does not cause substantial changes to the cardiovascular system when intravascular injection of the local anesthetic is avoided (Chernow *et al.*, 1983). However, greater concentrations (>1:50000), or even the rapid intravascular injection of the cartridge of anesthetic solution, may have dangerous haemodynamic effects in patients with cardiovascular disease (Malamed, 2004).

The blood aspiration technique before the injection of a local anesthetic solution is an essential procedure, because it prevents the possible systemic complications resulting from the intravascular injection of local anesthetics (Gay-Escoda *et al.*, 1986; Berini-Aytes, 2000; Piesold and Muller, 1998; Meechan and Blair, 1989; Delgado *et al.*, 1999; Cooly and Robison, 1979; Watson and Colman, 1976; Lopez and Rosello, 1995; Danieelsson *et al.*, 1984). It is the obligation of the dentist to avoid the risks associated with such accidental injection (Berini-Aytes and Gay-Escoda, 2000). However, even when this safety measure is adopted, it is not absolutely certain that the needle is not located intravascularly. On the other hand, it is essential to perform several aspirations in the course of anesthetic infiltration to ascertain that the needle has not displaced and that local anesthetic is not being injected into a blood vessel (Gay-Escoda *et al.*, 1986; Berini-Aytes, 2000; Piesold and Muller, 1998; Meechan and Blair, 1989; Delgado *et al.*, 1999; Cooly and Robison, 1979; Watson and Colman, 1976; Lopez and Rosello, 1995; Danieelsson *et al.*, 1984).

By definition, true blood aspiration occurs when a stream of blood rises through the cartridge with sufficient strength to mix with the anesthetic solution. In such situations the clinician must withdraw the needle, replace the cartridge and repeat the anesthetic technique from the start. However, it should be taken into account that false-positive and false-negative results may be obtained even

when a careful aspiration technique is performed. A *false-positive* result is defined as the penetration of blood within the carpule, producing a slight pinkish stain in its anterior portion. This phenomenon may occur as a result of damage to anatomic structures such as muscle or small blood vessels during needle insertion, with minor blood extravasations. Another possible cause is the presence of blood trapped within the needle lumen as a result of previous blood vessel penetration along the insertion trajectory (Berini-Aytes and Gay-Escoda, 2000; Delgado *et al.*, 1999; Cooly and Robison, 1979; Watson and Colman, 1976; Lopez and Rosello, 1995; Danieelsson *et al.*, 1984; Lehtinen and Oksala, 1979; Lehtinen, 1983). In such situations, no true blood aspiration is observed, although, in case of doubt as to whether the needle is located within a blood vessel, the needle should be withdrawn, followed by replacement of the carpule and repetition of the anesthetic technique. In addition, this measure allows the correct identification of any posterior blood aspirations.

On the other hand, a *false-negative* aspiration may be observed (i.e., the absence of blood aspiration even though the needle tip is located within a blood vessel). This can occur when the needle level is imprinted against the vascular endothelium, as a result of which the endothelium obstructs the needle lumen on aspiration. The pressure subsequently exerted to inject the anesthetic solution rejects the endothelial layer, thereby giving rise to intravascular administration of the anesthetic. Another possible cause is the collapse of a small vessel (with a caliber of under 1.5 mm) due to excessively intense aspiration. Consequently, negative aspiration is not a total guarantee that intravascular injection of the anesthetic solution has not occurred, in the same way that the presence of blood within the carpule does not always imply location of the needle tip within a blood vessel (Delgado *et al.*, 1999; Cooly and Robison, 1979; Watson and Colman, 1976; Delgado *et al.*, 2003).

According to Malamed, truncal block of the inferior alveolar nerve is the technique with the greatest risk of accidental intravascular injection, with an estimated incidence of 10-15% (Malamed, 2004). Due to paucity in the literature about relationship of age, gender and injection side with incidence of positive blood aspiration, this study was conducted.

MATERIALS AND METHODS

Four hundred and thirty four IANB in 2-18 year patients between August 2005 and July 2006 were studied at the private clinic of the principal author, Tehran, Iran.

All the injections were performed by the principal author using an aspirating syringe (Scullape, Germany) with a 27-guage needle 25 mm long (Fuji, Japan).

The patients had no contraindications for IANB such as infection or acute inflammation in the area of injection (Malamed, 2004). The patient was positioned supine and the mouth was opened wide. For a right IANB, the administrator set at the 8 o'clock position and for a left IANB at the 10 o'clock position (Malamed, 2004). IANBs were performed using indirect technique. The ball of the thumb was positioned on the coronoid notch of the anterior border of the ramus and the fingers were placed on the posterior border of the ramus. The needle was inserted between the internal oblique ridge and the pterygomandibular raphe. The barrel of the syringe overlay the 2 primary mandibular molars or premolars on the opposite side of the arch and parallels the occlusal plane (Wilson and Montgomery, 2005). The height of the injection was determined according to, the age of the patient. The needle was advanced until bone contact was established, followed by slight withdrawal (1 mm) and aspiration was performed. Hematic aspiration was accepted only if a blood jet rose forcefully along the cartridge on aspiration. The following data were recorded for each IANB: blood aspiration (either positive or negative), gender, age (up to the day of injection) and injection side.

The SPSS for PC, version 9, computer program was used in the analysis. Multiple logistic regression analysis with stepwise technique was used to estimate the relationship of age, gender and injection side with incidence of positive blood aspiration, using age and injection side as the binominal variable in regression and age as a quantative variable. The alpha value was set at 0.05.

RESULTS AND DISCUSSION

A total of 434 IANB were performed. The participants belonged to the 2-18-year-old group and the median age of the subjects was 6 years. The gender distribution was 199(45.9%) boys and 235(54.1%) girls. Of the aspirations performed, 211(48.6%) were on right side, whereas 223(51.4%) were on the left side. The total incidence of blood aspiration was 12.9%. The incidence of positive blood aspiration was regressed on age, using multiple logistic regression analysis. No significant differences (p<0.05) were observed on contrasting the incidence of positive blood aspiration with the age.

Table 1 depicts the aspiration results in regard to gender and injection side. Table 2 shows the results of multiple logistic regression analysis with positive

Table 1: Aspiration results in regard to gender and injection side

Variable	Number of positive aspirations	Percentage
Boys, left side	23	21.5
Boys, right side	13	14.1
Girls, left side	14	12.1
Girls, right side	6	5.0
Boys and girls, both sides	56	12.9

Table 2: The effect of gender and injection side on incidence of positive aspiration

Factor	Unstandardized coefficients (B±SE)	Standardized coefficients	p-value
gender	0.09±0.03	0.138	0.004
Injection side	-0.07±0.03	-0.017	0.025
Constant	1.84±0.07		<0.001

Table 3: Incidence of positive blood aspiration in IANB: comparison of the results of the present study with previous studies

Authors	Year of publication	Positive blood aspiration (%)
Harris	1957	3.6
Forrest	1959	4.2
Schiano and Strambi	1964	11.0
Cohen <i>et al.</i>	1969	10.6
Rood	1972	19.0
Barlett	1972	11.7
Corkery and Barrett	1973	16.8
Persson <i>et al.</i>	1974	8.2
Adams and Mount	1976	17.4
Lehtinen and Oksala	1979	13.2
Danielsson <i>et al.</i>	1984	11.3
Kuster and Udin	1985	3.1
Meechan and Blair	1989	18.9
Donker <i>et al.</i>	1990	22.0
Lopez and Rosello	1995	4.0
Lehtinen and Aarnisalo	1997	4.7
Delgado-Molina <i>et al.</i>	1999	8.9
Delgado-Molina <i>et al.</i>	2003	8.7
Frangiskos <i>et al.</i>	2003	20
Present study	2007	12.9

blood aspiration was regressed on gender and injection side. The incidence of positive blood aspiration was significantly higher among boys as compared to the girls (p<0.05). Significantly higher blood aspiration was also observed on left side as compared to right side (p<0.05).

According to Table 3 the percentage of blood aspirations reported in the literature is highly variable (3.6-22%). We observed positive blood aspiration in 12.9% cases. Frangiskos *et al.* (2003) observed that aspirating of blood was significantly more common in patients aged 9-19 years than all others (Frangiskos *et al.*, 2003). Kuster and Udin observed the higher percentage of hematic aspirations in 8-10 years old group (Kuster and Udin, 1985). However, we found no significant differences on correlating blood aspiration to the age. Regarding the incidence of positive blood aspiration and the injection side, Meechan and Blair (1989) and Delgado-Molina *et al.* (2003) recorded no statistically significant differences that are not in coincidence with our

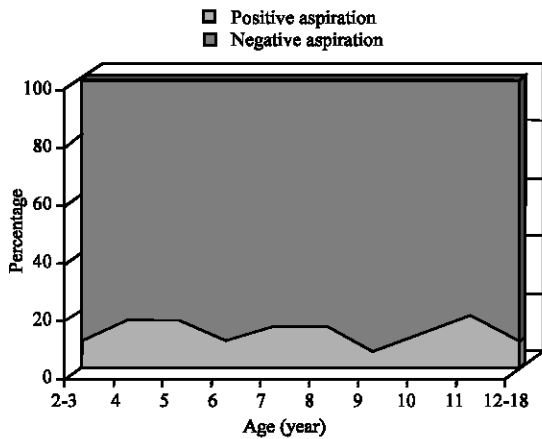


Fig. 1: Aspiration results in regard to age

own findings. Delgado-Molina *et al.* (2003) had found no significant differences with respect to patient's sex (Delgado-Molina *et al.*, 1999).

Further studies are warranted to assess the relationship of age, gender and injection side with positive blood aspiration. Such studies should consist of larger sample sizes. Furthermore, investigators should attempt to determine if a relationship exists between the operator technique and incidence of positive blood aspiration on different injection sides and genders Fig. 1.

CONCLUSION

The high incidence of intravascular injection during inferior alveolar nerve block that we found in pediatric population proves that aspiration is necessary because of increased likelihood of serious systemic complications, which may even endanger the life of the patient.

ACKNOWLEDGMENT

The authors thank Dr. Kazem Mehrdad for his insightful contributions during this study's development and Dr. Kaveh Alavi for his statistical advice.

REFERENCES

Adams, R.A. and G.J. Mount, 1976. The clinical effectiveness of a disposable aspirating syringe. *Aust. Dent. J.*, 21: 258.
 Barlett, S.Z., 1972. Clinical observations on the effects of injections of local anesthetics preceded by aspiration. *Oral. Surg. Oral. Med. Oral. Pathol.*, 33: 520.

Berini-Aytes, L. and C. Gay-Escoda, 2000. *Anestesia Odontologica*. 2nd Edn. Madrid: Avances, pp: 161-92.
 Bremer, G., 1952. Measurements of special significance in connection with anesthesia of inf alv nerve. *Oral. Surg.*, 5: 966-988.
 Chernow, B., F. Balestrieri, C.D. Ferguson, G.T. Terezhalmay, J.R. Fletcher and C.R. Lake, 1983. Local dental anesthesia with epinephrine: Minimal effects on the sympathetic nervous system or on hemodynamic variables. *Arch. Int. Med.*, 143 (11): 2141-2143.
 Cohen, M.B., L.A. Gravitz and T.A. Knappe, 1969. 25 versus 27 gauge needles. *J. Am. Dent. Assoc.*, 78: 1312.
 Cooly, R.L. and S.F. Robison, 1979. Comparative evaluation of the 30-guage dental needle. *Oral. Surg. Oral. Med. Oral. Pathol.*, 48: 400.
 Corkery, P.F. and B.E. Barrett, 1973. Aspiration using local anesthetic cartridges with an elastic recoil diaphragm. *J. Dent.*, 2: 72.
 Danieelsson, K., H. Evers and A. Nordenram, 1984. Aspiration in oral local anesthesia. Frequency of blood in cartridges in an undergraduate student material. *Swed Dent. J.*, 8 (6): 265-269.
 Delgado-Molina, E., M. Tamarit-Borras, L. Berimi-Aytes and C. Gay-Escoda, 2003. Evaluation and comparison of 2 needle models in terms of blood aspiration during truncal block of the inferior alveolar nerve. *J. Oral. Maxillofac Surg.*, 61 (9): 1011-1015.
 Delgado-Molina, E., S. Bueno-Lafuente, L. Berini-Aytes and C. Gay-Escoda, 1999. Comparative study of different syringes in positive aspiration during inferior alveolar nerve block. *Oral. Surg. Oral. Med. Oral. Pathol.*, 88 (5): 557-560.
 Donker, P., J. Wong and A. Punmia-Moorthy, 1990. An evaluation of closed mouth mandibular block technique. *Int. J. Oral. Maxillofac Surg.*, 19: 216.
 Forrest, J.O., 1959. Notes on aspiration before injection of local anesthesia using dental cartridges. *Br. Dent. J.*, 107: 259.
 Frangiskos, F., E. Stavrou, N. Merenditis, H. Tsitsogianis and E. Vardas, 2003. Antonopoulou I. Incidence of penetration of a blood vessel during inferior nerve dental block. *Br. J. Oral. Maxillofac. Surg.*, 41(3): 188-189.
 Gay-Escoda, C. and M.A. Sanchez-Garces, 1986. Coplicaciones in situ de los anesteticos locales en cirugia de la region oral. *Estomodeo.*, 20: 18.
 Harris, S.C., 1957. Aspiration before injection of local anesthetic. *J. Oral. Surg.*, 15: 299.
 Hayward, J., E.R. Richardson and S.K. Malhortra, 1977. The mandibular foramen: Its anteroposterior position. *Oral. Surg.*, 44: 837-843.

- Hetson, G., J. Share, J. Frommer and J.H. Kronman, 1988. Statistical evaluation of the position of the mandibular foramen. *Oral. Surg. Oral. Med. Oral. Pathol.*, 65: 32-34.
- Kuster, C.G. and R.D. Udin, 1985. Frequency of accidental intravascular injection of local anesthetics in children. *ACDS J. Dent. Child.*, 52 (3): 183-187.
- Lehtinen, R. and E. Oksala, 1979. Penetration of disposable needles. *Int. J. Oral. Surg.*, 8: 145.
- Lehtinen, R. and T. Aarnisalo, 1997. Coparison between disposable self-aspirating and usual syringes. *Acta Odontol. Scand.*, 35 (1): 9-11.
- Lehtinen, R., 1983. Penetration of 27 and 30-gauge dental needles. *Int. J. Oral. Surg.*, 12: 444.
- Lopez, J.L. and X. Rosello, 1995. Anestesia troncular del nervio dentario inferior. Procentaje de aspiraciones positivas. *Rev. Eur. Odontoestomatol.*, 6: 353.
- Lustig, J.P. and S.P. Zusman, 1999. Immediate complications of local anesthetic administrated to 1007 consecutive patients. *J. Am. Dent. Assoc.*, 130: 496-499.
- Malamed, S.F., 2004. *Handbook of Local Anesthesia*. 5th Edn. St. Louis: Mosby, pp: 171-332.
- Martiz, C., E. Karabouta-Voulgaropoulou and K. Marti, 1986. Aspiration in inferior alveolar nerve block. *Stomatoplogia*, 43: 273-278.
- Mc Donald, R.E., D.R. Avery and J.A. Dean, 2004. Local Anesthesia and Pain Control for the Child and Adolescent. In: Mc Donald, R.E., D.R. Avery and J.A. Dean (Eds.), *Dentistry for the Child and Adolescent*. 8th Edn. St. Louis: Mosby, pp: 270-284.
- Meechan, J.G. and G.S. Blair, 1989. Clinical experience in oral surgery with 2 different automatic aspirating syringes. *Int. J. Oral. Maxillofac Surg.*, 18: 87.
- Persson, G., E. Keskitalo and H. Evers, 1974. Clinical experiences in oral surgery using a new self-aspirating injection system. *Int. J. Oral. Surg.*, 3: 428.
- Piesold, J. and J.D. Muller, 1998. An experimental study on the aspirating reliability of different types of injection syringes with regard to the formation of punch cylinders. *Br. J. Oral. Maxillofac Surg.*, 36: 39.
- Prince, B.S., C.M. Goetz, T.L. Rihn and M. Olsky, 1992. Drug-related emergency department visits and hospital admissions. *Am. J. Hosp. Pharm.*, 49 (7): 1696-1700.
- Rood, J.P., 1972. Inferior nerve dental block: Routine aspiration and a modified technique. *Br. Dent. J.*, 132: 103.
- Schiano, A.M. and R.C. Strambi, 1964. Frequency of accidental intravascular injection of local anesthetics in dental practice. *Oral. Surg. Oral. Med. Oral. Pathol.*, 17: 178.
- Watson, J.E. and R.S. Colman, 1976. Interpretation of aspiration tests in local anesthetic injections. *J. Oral. Surg.*, 34: 1069.
- Wilson, S. and R.D. Montgomery, 2005. Local Anesthesia and Oral Surgery in Children. In: Pinkham, J.R., P.S. Casamassimo, H.W. Fields, D.J. McTigue and A.J. Nowak (Eds.), *Pediatric Dentistry, Infancy through Adolescence*. 4th Edn. Philadelphia: WB Saunders, pp: 447-462.