

Assessment of Adenoid Size in Children

¹Shahin Abdollahi-Fakhim, ¹Masood Naderpoor, ¹Nikzad Shahid, ²Reza Javadrashid,
³Omid Mashrabi and ¹Majid Ravaghi

¹Department of Otolaryngology, Head and Neck Surgery in Tabriz,
University of Medical Sciences, Tabriz, Iran

²Department of Radiology, Tabriz University of Medical Sciences, Tabriz, Iran

³Family Medicine (MD) in Health Center, Ajabshir, East Azarbayjan Province, Iran

Abstract: Adenoid hypertrophy is one of the most common diseases in the pediatric population, and can cause nasal obstruction, snoring, mouth breathing, and alteration in facial development in children. Flexible fiberoptic nasolaryngoscopy was the gold standard method for evaluation of adenoid and nasopharyngeal obstruction. The aim of this study was evaluation results and agreement of flexible flexible fiberoptic nasolaryngoscopy, Adenoid lateral x-ray and intraoperative observation diagnosis of adenoid hypertrophy and its intensity. In a cross-sectional and descriptive-analytical study, 50 pediatric patients who had suffered from nasal obstruction and mouth breathing were selected in this study to undergo adenoidectomy. The size of adenoid measured by flexible fiberoptic nasolaryngoscopy, lateral neck radiography and intraoperative observation of adenoid size. Results of three studied methods in diagnosis of adenoid hypertrophy and its severity were compared. Twenty two of patients were boy and 28 of them were girl. Mean age of patients was 6.26 ± 1.81 year in the range of 3-12 year. The agreement rate of Lateral Neck Radiography in determination of adenoid hypertrophy with intraoperative observation of adenoid size and flexible fiberoptic nasolaryngoscopy was 70 and 50%, respectively and between flexible fiberoptic nasolaryngoscopy and intraoperative observation of adenoid size was 72% and between three methods was 48%. The agreement rate of each three methods in diagnosis of adenoid hypertrophy was 100%. Significantly strong correlation was found between intraoperative observation of adenoid size with lateral neck radiography and flexible fiberoptic nasolaryngoscopy and poor correlation was found between Lateral Neck Radiography and flexible fiberoptic nasolaryngoscopy.

Key words: Flexible fiberoptic nasolaryngoscopy, adenoid hypertrophy, lateral neck radiography

INTRODUCTION

The adenoid (pharyngeal tonsil) is one of the peripheral lymphoepithelial organs, which play an important role in the immune system where a variety of microorganisms and antigens present in food and inhaled air first come in contact with the body. However, its complete function has remained unknown (Kim *et al.*, 1995; Woo *et al.*, 1995).

The most important diagnostic techniques are recording of obstructive symptoms by transoral posterior rhinoscopic examination, radiological evaluation, such as lateral radiography of the adenoid and nasopharyngeal magnetic resonance imaging, transnasal fiberoptic examination, acoustic rhinometry and others (Modrzyński *et al.*, 2004).

Recently, flexible fiberoptic nasolaryngoscopy was the gold standard method for evaluation of adenoid and

nasopharyngeal obstruction (Kubba and Bingham, 2001; Wormald and Prescott, 1992; Chisholm *et al.*, 2005).

Adenoid hypertrophy is one of the most common diseases in the pediatric population, and can cause nasal obstruction, snoring, mouth breathing and alteration in facial development in children.

The aim of this study was evaluation results and agreement of flexible flexible fiberoptic nasolaryngoscopy, Adenoid lateral x-ray and intraoperative observation diagnosis of adenoid hypertrophy and its intensity.

MATERIALS AND METHODS

In a cross-sectional and descriptive-analytical study, 50 pediatric patients who had suffered from nasal obstruction and mouth breathing were selected in this study to undergo adenoidectomy (Fig. 1).

The size of adenoid measured by flexible fiberoptic nasolaryngoscopy, lateral neck radiography and intraoperative observation of adenoid size.

Results of three studied methods in diagnosis of adenoid hypertrophy and its severity were compared.

To evaluate the size of the adenoids, the patients were examined by fibrescopy in the sitting position. The size of the adenoid was classified into 4 categories according to the degree to which the adenoid occupied the nasopharyngeal airway.

Mild: Adenoid occupying 25% or less of the nasopharyngeal airway.

Moderate: Adenoid occupying 25-50% of the nasopharyngeal airway.

Moderately severe: Adenoid occupying 50-75% of the nasopharyngeal airway.

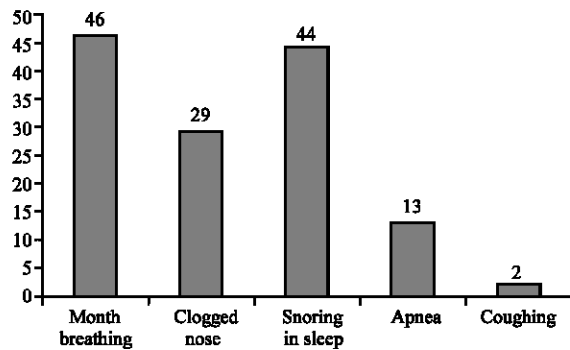


Fig. 1: Frequency of patients signs

Table 1: Results of three studied method in determination intensity of Adenoid Hypertrophy

	Intensity of adenoid hypertrophy			
	Complete	Sever	Moderate	Mild
Lateral Neck Radiography	6	42	50	2
Flexible Fiberoptic Nasolaryngoscopy	22	54	24	0
Intraoperative Observation of Adenoid Size	12	58	30	0

Table 2: Evaluation intensity of Adenoid Hypertrophy by lateral neck radiography

	Intensity of adenoid hypertrophy		
	Moderate hypertrophy	Sever hypertrophy	Complete obstruction
True positive	11	13	1
False positive	14	8	2
True negative	24	15	37
False negative	1	14	10
Sensitivity	91.6%	61.9%	9%
Specificity	63.1%	65.2%	94.8%

Table 3: Evaluation intensity of Adenoid Hypertrophy by intraoperative observation of adenoid size

	Intensity of adenoid hypertrophy		
	Moderate hypertrophy	Sever Hypertrophy	Complete obstruction
True positive	11	21	4
False positive	4	8	2
True negative	34	15	37
False negative	1	6	7
Sensitivity	91.6%	77.7%	36.3%
Specificity	89.4%	55.5%	94.8%

Severe: Adenoid occupying 75% or more of the nasopharyngeal airway.

As the gold standard method, flexible fiberoptic nasolaryngoscopy was compared with other methods.

RESULTS

Mean age of patients was 6.26±1.81 year in the rage of 3-12 year and 22 of patients were boy and 28 of them were girl. History of allergy in patients, parents and first degree family were 14, 8 and 2%, respectively.

The agreement rate of each three methods in diagnosis of adenoid hypertrophy was 100% and the agreement rate studied methods in determined of hypertrophy intensity were showed in Table 1.

The agreement rate of lateral neck radiography in determination of adenoid hypertrophy with intraoperative observation of adenoid size and flexible fiberoptic nasolaryngoscopy was 70 and 50%, respectively and between flexible fiberoptic nasolaryngoscopy and intraoperative observation of adenoid size was 72% (Table 2).

Significant strong correlation was found between result of intraoperative observation of adenoid size with radiological finding ($p < 0.001$ and $R = 0.586$) and flexible fiberoptic nasolaryngoscopy ($p < 0.001$ and $R = 0.702$) (Table 3). The significant poor correlation was found between result of radiological finding and flexible fiberoptic nasolaryngoscopy ($p = 0.014$ and $R = 0.347$).

DISCUSSION

After several studies, many authors found that flexible fiber optic nasolaryngoscopy is the best and the most exact method in diagnosis of adenoid hypertrophy (Kubba and Bingham, 2001; Wormald and Prescott, 1992; Chisholm *et al.*, 2005; Kurien *et al.*, 2005).

Dr. Snow and his colleagues introduced flexible fiberoptic nasolaryngoscopy as gold standard method for evaluation of adenoid hypertrophy (Snow and Bllenger, 2003).

In our study, a strongly significant correlation was found between Tran's operative examination and flexible fiberoptic nasolaryngoscopy.

Chisholm and his colleagues reported a poor significant correlation between intraoperative observation of adenoid size and flexible fiberoptic nasolaryngoscopy (Chisholm *et al.*, 2005).

In the study of Cohen and his colleagues, a poor significant correlation has been reported between intraoperative observation of adenoid size and lateral adenoid x-Ray finding and lateral adenoid. X-ray was not enough for preoperative evaluation of patient with adenoid hypertrophy (Cohen *et al.*, 1992).

But in our study, we found a strongly significant correlation between intraoperative observation of adenoid size and lateral adenoid x-ray due to more attention of our surgeons.

Warmald and his colleagues reported lateral x-ray has a great ability in diagnosis of adenoid hypertrophy but not enough effectiveness in determination of the intensity of adenoid hypertrophy (Warmald and Prescott, 1992).

Paradise JL and his colleagues, Said that lateral x-ray of adenoid was not successful in determination of intensity of adenoid hypertrophy (Paradise *et al.*, 1998).

In our study lateral adenoid x-ray have high potency in diagnosis of adenoid hypertrophy but not enough potency in diagnosis intensity of adenoid hypertrophy.

Modrzyasky M and his colleagues reported that lateral adenoid x-ray is more effective in diagnosis of adenoid hypertrophy (Modrzybski *et al.*, 2004).

In our study also sensitivity of lateral adenoid x-ray in diagnosis of adenoid hypertrophy was 100%.

The radiological method that best correlated with the endoscopic findings was that of Cohen and Konak (1985). However, obstructive symptomatology had the overall highest correlation to endoscopic findings (Warmald and Prescott, 1992). There was good agreement between the X-ray and endoscopy findings.

Lateral skull radiograph is a noninvasive procedure which is well tolerated by children, unlike a flexible fibroptic scope. In recent years fibroptic scopy has been quoted to have more information about the adenoid hypertrophy than lateral skull radiography (Kurien *et al.*, 2005). Our study has shown that there is a significant relationship between endoscopic and radiological findings of the children.

CONCLUSION

Three methods studied had the same more effectiveness in diagnosis of adenoid hypertrophy, but regarding diagnosis of intensity of adenoid hypertrophy, sensitivity of flexible fiberoptic nasolaryngoscopy was higher than that of other 2 methods flexible fiberoptic

nasolaryngoscopy is the gold standard method in diagnosis of adenoid hypertrophy and determination of its intensity.

With attention to finding results, for evolution of adenoid hypertrophy intensity at the first step, lateral adenoid x-ray was recommended and flexible fiberoptic nasolaryngoscopy was recommended for determination of adenoid hypertrophy intensity.

REFERENCES

- Chisholm, E.J., S. Lew-Gor and H. Hajioff, 2005. Adenoid size assessment: A comparison of palpation, nasendoscopy and mirror examination. *Clin. Otolaryngol.*, 30 (1): 39-11.
- Cohen, L.M., P.J. Koltai and J.R. Scot, 1992. Lateral cervical radiographs and adenoid size: Do they correlate? *Ear Nose Throat J.*, 71 (12): 638-642.
- Kim, Y.K., J.H. Kang, Y.S. Yoo, 1995. The change of the cross sectional area and the volume of the nasal cavity and the nasopharynx after tonsillectomy and adenoidectomy. *Korean J. Otolaryngol. Head and Neck*, 38 (1): 105-109.
- Kubba, K. and B.J.G. Bingham, 2001. Endoscopy in the assessment in the children with nasal obstruction. *J. Laryngol. Otol.*, 115 (14): 380-384.
- Kurien, M., A. Lepcha, J. Mathew, A. Ali and L. Jeyaseelan, 2005. X-rays in the evaluation of adenoid hypertrophy: It's role in the endoscopic era. *Indian J. Otolaryngol. Head Neck Surg.*, 57: 45-47.
- Modrzybski, M., J. Mierzwiński, E. Zawisz, A. Piziewicz, 2004. Additional diagnostic methods for recording of adenoid hypertrophy in children with allergic rhinitis. *Przegl Lek*, 61 (2): 74-77.
- Modrzyński, M., J. Mierzwiński, E. Zawisza and A. Piziewicz, 2004. Additional diagnostic methods for recording of adenoid hypertrophy in children with allergic rhinitis. *Przegl Lek*, 61 (2): 74-77.
- Paradise, J.L., B.S. Bernard, D.K. Colborn and J.E. Janodky, 1998. Roentgenographic Findings Assessment of Adenoidal Obstruction in Children: Clinical Signs Versus PEDLATRICES, 101 (6): 979-986.
- Snow, J.B. and J.I. Bllenger, 2003. Ballenger's Otorhinolaryngology, Head and Neck Surgery. 16th Edn. BC Decker, USA, 12: 1015.
- Woo, H.Y., H.S. Cheong, I.H. Kang and I.T. Kim, 1995. Changes in nasal airway after adenotonsillectomy using acoustic rhinometry and Wright mini flowmeter. *Korean J. Otolaryngol. Head and Neck Surg.*, 38 (12): 1988-1992.
- Warmald, P.J. and C.A. Prescott, 1992. Adenoids. Comparison of radiological assessment methods with clinical and endoscopic findings. *J. Laryngol. Otol.*, 106 (4): 32-344.