

Comparison of Vertebroplasty Versus Conservative Treatment in Osteoporotic Compression Fractures

M. Shakeri Bavil

Department of Neurological Surgery, Tabriz University of Medical Sciences, Tabriz, Iran

Abstract: To compare clinical and radiological results between vertebroplasty and conservative treatment in osteoporotic compression fractures of thoracolumbar spine, 34 patients were reviewed with at least 1 year follow up. Vertebroplasty was used in 14 and conservative treatment was done in 20 fractures. Our retrospective analysis demonstrated that vertebroplasty provided significant pain relief, improvement of motion and reduction of analgesic usage and also provided considerable spinal stabilization that prevented further Kyphosis and collapse.

Key words: Vertebroplasty, conservative treatment, fractures, patient

INTRODUCTION

While, it is a general rule to apply early ambulation by reduction of fracture and internal fixation in treating patients with osteoporotic fractures of wrist and hip joints, conservative treatment has been widely employed in the case of thoracolumbar compression fractures to date (Amar *et al.*, 2001). In 1987, vertebroplasty was first applied by Galibert in the treatment of patients with vertebral body hemangioma (Barr *et al.*, 2000). Vertebroplasty has since been expanded to the treatment of patients with hemangioma, osteoporotic compression fracture and malignant tumor (Do *et al.*, 2002). It has been reported that infusing cement in the vertebral body of such patients can greatly reduce pain as well as ensure spinal stability (Gold and Lyles, 1999; Silverman, 1992). The authors of this research purported to investigate the effects of vertebroplasty as opposed to conservative treatment by using the clinical and radiological follow-up results of these 2 treatment methods, when applied to patients with osteoporotic compression fractures of thoracolumbar spine.

MATERIALS AND METHODS

Thirty four patients were reviewed with at least 1 year follow up. Vertebroplasty was used in 14 and conservative treatment was done in 20 fractures. These groups were compared by clinical results which were evaluated by the scoring system according to pain, mobility and analgesic usage at preoperative, post operative 1 month and postoperative 1 year. And also compared by the increment of kyphosis and loss of

vertebral body height in lateral films at the same time. We compared duration of hospitalization between 2 groups.

RESULTS AND DISCUSSION

Vertebroplasty showed statistically significant less pain and mobility than conservative treatment ($p < 0.05$), but there were no differences in analgesic usage at postoperative 1 year while significant difference at 1 month. In radiological comparison, vertebroplasty showed less increment of kyphosis and loss of body height significantly ($p < 0.05$). Also vertebroplasty had shorter hospitalization stay significantly ($p < 0.05$) (Fig. 1 and 2).

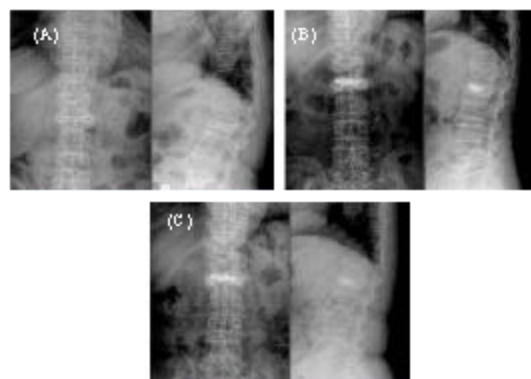


Fig. 1: A 69-year-old woman with recent compression fracture on L2. A: A preoperative radiograph shows 43.3% height loss and 26.2° kyphosis of L2, B: A postoperative radiograph shows 20.6% height loss and 12.1° kyphosis of L2, C: 1 year after operation, radiographs shows 24.9% height loss and 14.0° kyphosis of L2

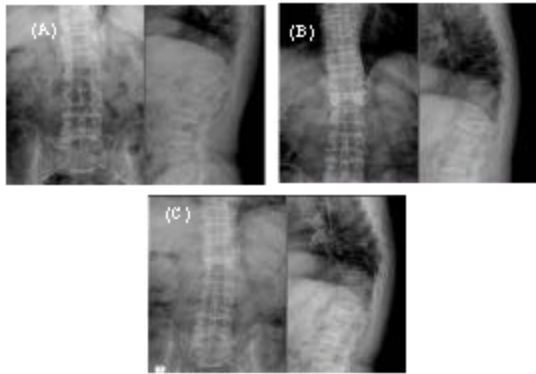


Fig. 2: A 65-year-old man with compression fracture on L1, A: Post-trauma radiograph shows 10.5% height loss and 8.5° kyphosis of L1, B: After 3 months-conservative treatment, radiograph shows 28.7% height loss and 17.2° kyphosis of L1, C: 1 year after trauma radiograph shows 34.0% height loss and 22.2° kyphosis of L1

CONCLUSION

Our retrospective analysis demonstrated that vertebroplasty provided significant pain relief, improv-

ement of motion and reduction of analgesic usage and also provided considerable spinal stabilization that prevented further kyphosis and collapse.

REFERENCES

- Amar, A.P., D.W. Larsen and N. Esnaashari, 2001. Albuquerque FC, Lavine SD and Teitelbaum GP Percutaneous transpedicular polymethylmethacrylate vertebroplasty for the treatment of spinal compression fractures. *Neurosurg. Discussion*, 14-5, 49: 1105-1114.
- Barr, J.D., M.S. Barr and T.J. Lemley, 2000. Percutaneous vertebroplasty for pain relief and spinal stabilization. *Spine*, 15: 923-928.
- Do, H.M., M.L. Marcellus, R.U. Weir and M.P. Marks, 2002. Percutaneous vertebroplasty versus medical therapy for treatment of acute vertebral body compression fracture: A prospective randomized study, *Proceedings of the ASNR and Proceedings of the AUR*.
- Gold, D.T. and K.W. Lyles, 1999. *Fractures, Effects on Quality of Life*, San Diego, London, Academic.
- Silverman, S.L., 1992. The clinical consequences vertebral compression fracture. *Bone*, 13 (Suppl. 2): 27-31.