

## **Maxillary Bone Necrosis Following the Use of Bisphosphonates in Patients with Cancer: Management and Case Series**

Silvia Tortorici, Francesco Burrano, Luigi Caradonna, Maria Lidia Buzzanca and Paolo Difalco  
Department of Stomatological Science “G.Messina”, University of Palermo, Palermo, Italy

**Abstract:** Bisphosphonates are bone-turnover modulating drugs used to treat various diseases such as certain cancers, bone metastasis, bone- and calcium-related disorders, Paget's disease, osteoporosis and osteopenia. Recently, several preliminary reports have reported the insurgence of osteonecrosis of the mandible and/or maxilla, associated with intravenously administered bisphosphonates. This case series describes the effects of bisphosphonates used in the treatment of certain cancers on oral bone tissues.

**Key words:** Bisphosphonates, bone necrosis, avascular necrosis of the jaw, cancer, case series

### **INTRODUCTION**

The bisphosphonates are bone-turnover modulating drugs used to treat various diseases such as certain cancers, bone metastasis, bone- and calcium-related disorders, Paget's disease, osteoporosis and osteopenia (Merigo *et al.*, 2006; Estefenia *et al.*, 2006).

These drugs are non-metabolized pyrophosphate analogues which inhibit osteoclastic activity and reduce bone remodelling. The bone turnover alteration result in increased bone-mineral density.

Recently, bisphosphonate has received attention in dental literature because the drug (particularly when administered intravenously) inhibits tooth orthodontic movement and can increase serious osteonecrosis risks in the alveolar bones of the maxilla and the mandible (Merigo *et al.*, 2006; Rinchuse *et al.*, 2007; Zahrowski, 2007; Mortensen *et al.*, 2007).

The exact mechanism of bisphosphonate leading to osteonecrosis of the jaw is unknown. Probably this complication is due to anti-angiogenic properties and contributes to progressive disappearance of bony micro-vascular blood supply (Merigo *et al.*, 2006).

Clinical presentations include absent or delayed soft tissue healing with bony exposure following dental extraction or spontaneous gum dehiscence.

Although, it is often associated with a recent dental surgical procedure, spontaneous osteonecrosis of the jaw can also occur (Van and Estilo, 2006; Scully *et al.*, 2006). Patients are usually asymptomatic but may develop pain, paresthesia, foetor ex ore, loosening of teeth, swelling and suppuration if the bone becomes secondarily infected (Elad *et al.*, 2006).

The management of patients with bisphosphonate-related jaw necrosis remains extremely difficult and includes surgical debridements, bone curettage, local irrigation and or hyperbaric oxygen therapy (Eckert *et al.*, 2007).

Unfortunately, these therapies have proven to be unsuccessful.

This study describes the effects on the periodontal and bone tissues of the bisphosphonates used in patients with cancers.

### **CASE REPORTS**

**Case 1:** A 66 years old male patient was referred to our department for a non-healing ulcer of the mandible. He presented bony sequestrum associated with previous tooth extraction in the right mandibular molar region.

Five months earlier, he had visited his dentist for a severe pain associated with the teeth 36 (LR6) and 37 (LR6). Those teeth had been extracted and a piece of jawbone exposed, causing pain, bleeding and paresthesia of the lower lip.

During the medical anamnesis the patient revealed that he had been treated for prostate cancer with multiple bone metastases. Treatment of prostate cancer was carried out with combined surgical and chemo therapy.

Chemo therapy, with intravenously administered bisphosphonates (Zoledronate) in association with hormones (Cyproterone acetate and Bicalutamide), was used to control hypercalcaemia.

Zoledronate (Zometa®) at a dose of 4 mg was administered intravenously monthly for 2 years (infusion over a period of 15 min).

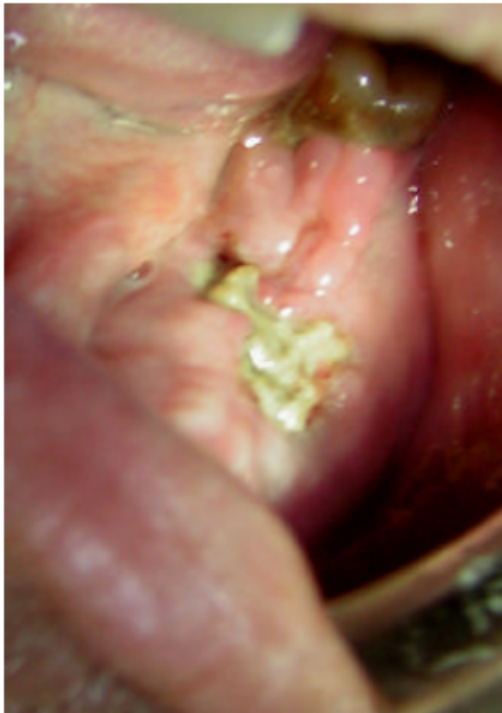

Fig. 1: Areas of exposed bone with surrounding erythema on the posterior left mandible



Fig. 2: Orthopantomography shows extension of bony sequestrum

Clinical examination revealed areas of exposed bone with surrounding erythema on the posterior left mandible (Fig. 1). Orthopantomography showed extension of bony sequestrum (Fig. 2). The diagnosis was osteonecrosis of the jaw bone due to bisphosphonates.

The treatment consisted of light local debridement and administration of oral antibiotics (500 mg of Amoxicillin and 500 mg of Metronidazole three times a day for 10 days) and a disinfectant mouthwash (0.2% Chlorhexidine gluconate).

**Case 2:** A 60-years old female, with breast cancer history, was referred for assesment. She had been treated with Zoledronic acid (Zometa®) as an adjuvant therapy for the prevention of bone metastasis. Zoledronic acid at 4 mg

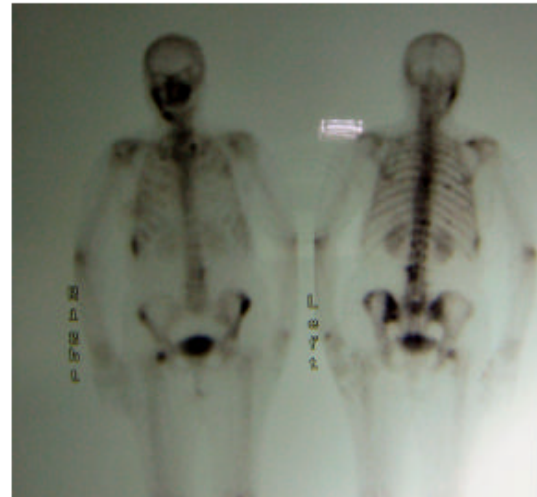


Fig. 3: Bone scintigram shows a hot spot on the right side of the mandible

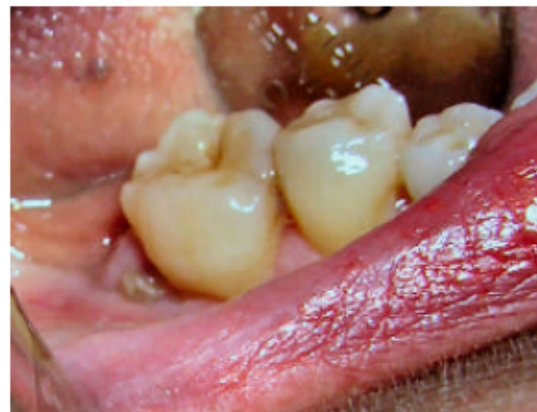

Fig. 4: Gingival swelling on the right side of the mandible associated with exposed necrotic bone distal tooth 46 (LR6)

was administered intravenously, via a short 15 min infusion every 3 weeks, for 2 years.

In January 2007, she complained of mild right mandibular pain and bone scintigram showed a hot spot on the right side of the mandible (Fig. 3). The patient revealed that a month earlier she had been treated for periodontitis with scaling and root planning of the distal root surface of tooth 46 (LR6). Oral examination showed gingival swelling on the right side of the mandible associated with exposed necrotic bone distal tooth 46 (LR6) (Fig. 4).

Treatment was carried out with a disinfectant mouthwash (0.2% Chlorhexidine gluconate) and systemic antibiotics consisting of 500 mg of Amoxicillin and 500 mg

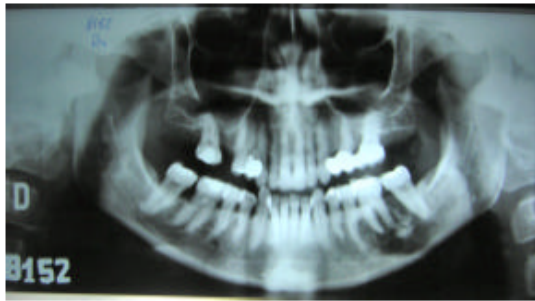


Fig. 5: Orthopantomography shows extension of bony sequestrum

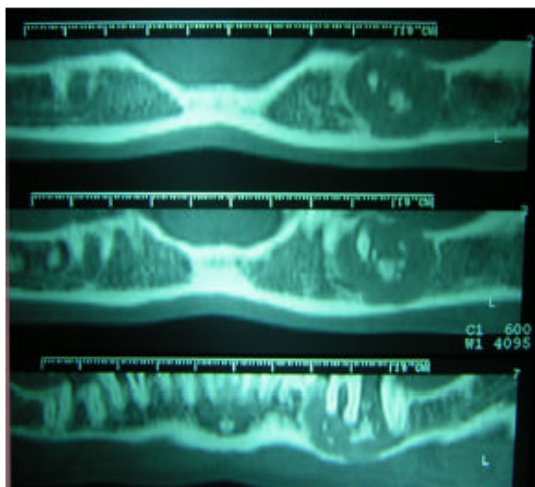


Fig. 6: Computed tomography shows extension of bony sequestrum

of Metronidazole three times a day for 10 days. This therapy achieved clinically significant short-term improvements in clinical parameters.

**Case 3:** A 50-year-old female was referred to our department by her oncologist. The patient presented a 1-month history of severe jaw pain. Patient also reported history of IgG myeloma, complicated by hypercalcemia, that was being treated with VAD (vincristine, adriamycin and dexamethasone) regimen. In addition to direct treatment of the plasma cell proliferation, Pamidronate was administered, at a dose of 90 mg every month for 21 cycles, to prevent fractures and erythropoietin to treat anemia.

Clinical examination revealed areas of exposed bone with surrounding erythema on the right side of the mandible. Orthopantomography and Computed Tomography showed extension of bone sequestrum (Fig. 5 and 6).

She had no known bone involvement from her myeloma, but she recalled that a month earlier she had been treated for periodontitis with scaling and root planning of the distal root surface of teeth 36 (LL6) and 3.7 (LL7).

A diagnosis of bisphosphonate-associated osteonecrosis of the jaw was made. She was treated with light local debridement, administration of systemic antibiotics (500 mg of Amoxicillin and 500 mg of Metronidazole three times a day for 10 days) and 0.2% Chlorhexidine gluconate. This therapy achieved clinically significant short-term improvements in clinical parameters.

## DISCUSSION

Bisphosphonates have proven beneficial in the treatment of cancer-related hypercalcemia and bone involvement resulting from multiple myeloma and solid tumors (Mortensen *et al.*, 2007; Bamias *et al.*, 2005). Intravenous bisphosphonates such as Pamidronate and Zoledronate demonstrated reduction in skeletal complications. Although, bisphosphonates recently associated with osteonecrosis of the jaw, they are generally well tolerated and cause minimal adverse effects (Berenson *et al.*, 2006; Zarychanski *et al.*, 2006).

Osteonecrosis of the jaw in patients treated with bisphosphonates has been first reported in 2003. It has also been described occasionally in cancer patients after chemotherapy and radiotherapy (Bamias *et al.*, 2005). The exact mechanism of bisphosphonates-induced osteonecrosis of the jaw is unclear.

Several predisposing factors have been identified. Osteonecrosis of the jaws is more common with the intravenous form of the drugs (Gutta and Louis, 2007) although in intravenous treatment it depends on the agent used and the length of time administered. It appears to be associated with long term treatment with Pamidronate or Zoledronate (Purcell and Boyd, 2005).

Many patients developed spontaneous bone necrosis after bisphosphonates treatment (Basu and Reid, 2007). In most cases osteonecrosis of the jaws in cancer patients receiving bisphosphonates treatment appears after dental extraction, periodontal treatment (scaling and root planning) or oral surgery (Basu and Reid, 2007). Other possible etiologic or precipitating factors are microtraumas or orthodontic movements as bisphosphonates inhibit bone turnover and result in poorly or no healing (Rinchuse *et al.*, 2007; Zahrowski, 2007; Mehrotra and Riggiero, 2006).

Probably osteonecrosis of the jaws is due to anti-angiogenic properties and contribute to progressive disappearance of bony micro-vascular blood supply (Merigo *et al.*, 2006). Also, vascular insufficiency and an underlying hypercoagulable state resulting from an underlying malignancy appear to be associated with bisphosphonates-induced osteonecrosis. At last, immunosuppression, induced by corticosteroid therapy and immune-compromised state predispose to increased risk of infection after minor trauma; this contribute to progressive osteonecrosis.

Although, as explained above, there have been several reports indicating that osteonecrosis is due to bisphosphonates anti-angiogenic properties. Bamias *et al.* (2005) studied the effect of thalidomide (an agent with antiangiogenic properties) and they found no association of thalidomide use with the development of osteonecrosis.

Today the management of patients with bisphosphonate-related jaw necrosis remains extremely difficult and includes surgical debridements, bone curettage, local irrigation and or hyperbaric oxygen therapy (Eckert *et al.*, 2007). Unfortunately, these therapies have proven to be unsuccessful and often result in a recurring or even progressing lesion. Antibiotics are indicated only to treat secondary infection. In the presence of concomitant super-infection, microbial cultures may help identify and direct appropriate antimicrobial therapy.

Osteonecrosis of the jaw poses a significant problem because no therapy is effective. For this reason oncologists need to inform the patients and closely consult with dentists and oral and maxillofacial surgeons before administrating bisphosphonates.

During treatment with bisphosphonates the prevention of osteonecrosis of the jaw depends on a minimization of dental and surgical interventions (Eckert *et al.*, 2007).

Before prescribing bisphosphonate therapy a careful oral examination is recommended. Dentogenic foci, gingivitis, periodontal disease are be recognized and treated, before starting intravenous bisphosphonates.

Oral professional hygiene, dental reconstruction and, in toothless patients, a well-fitting dental prosthesis are recommended as well as optimal oral hygiene, regular dental check-ups and care are necessary during treatment with bisphosphonates.

According to Mehrotra and Ruggiero (2006) there are currently no data available to recommend discontinuing, maintaining or temporarily interrupting bisphosphonate therapy once osteonecrosis of the jaw has developed.

Therefore, the interruption of the treatment with bisphosphonates after osteonecrosis has developed does not appear to be useful.

As of today further research into bisphosphonates-induced osteonecrosis of the jaw pathophysiology is necessary for the management of this complication.

## REFERENCES

- Bamias, A., E. Kastritis, C. Bamia, L.A. Mouloupoulos, I. Melakopoulos, G. Bozas, V. Koutsoukou, D. Gika, A. Anagnostopoulos, C. Papadimitriou, Terpos and M.A. Dimopoulos, 2005. Osteonecrosis of the Jaw in Cancer After Treatment With Bisphosphonates: Incidence and Risk Factors. *J. Clin. Oncol.*, 23: 8580-8587.
- Basu, N. and D.M. Reid, 2007. Bisphosphonate-associated osteonecrosis of the jaw. *Menopause Int.*, 13: 56-59.
- Berenson, J.R., L. Rajdev and M. Broder, 2006. Treatment strategies for skeletal complications of cancer. *Cancer Biol. Ther.*, 5: 1074-1077.
- Eckert, A.W., P. Maurer, L. Meyer, M.S. Kriwalsky, R. Rohrberg, D. Schneider, U. Bilkenroth and J. Schubert, 2007. Bisphosphonate-related jaw necrosis severe complication in maxillofacial surgery. *Cancer Treat. Rev.*, 33: 58-63.
- Elad, S., N. Yarom, W. Hamed, S. Ayalon, R. Yahalom and E. Regev, 2006. Osteomyelitis and necrosis of the jaw in patients treated with bisphosphonates: A comparative study focused on multiple myeloma. *Clin. Lab. Haematol.*, 28: 393-398.
- Estefania, F.R., R.P. Fernandez and J.M. Aguirre Urizar, 2006. Bisphosphonates and oral pathology II. Osteonecrosis of the jaws: Review of the literature before 2005. *Med. Oral. Patol. Oral. Cir. Bucal.*, 11: 456-461.
- Gutta, R. and P.J. Louis, 2007. Bisphosphonates and osteonecrosis of the jaws: Science and rationale. *Oral. Surg. Oral. Med. Oral. Pathol. Oral. Radiol. Endod.*
- Mehrotra, B. and S.L. Ruggiero, 2006. Bisphosphonate Complications Including Osteonecrosis of the Jaw. *Hematology Am. Soc. Hematol. Edu. Program*, pp: 356-60.
- Merigo, E., M. Manfredi, M. Meleti, R. Guidotti, A. Ripasarti, E. Zanzucchi, P. D'Aleo, D. Corradi, L. Corcione, E. Sesenna, S. Ferrari, T. Poli, M. Bonaninil and P. Vescovi, 2006. Bone necrosis of the jaws associated with bisphosphonate treatment: A report of twenty-nine cases. *Acta Biomed.*, 77: 109-117.

- Mortensen, M., W. Lawson and A. Montazem, 2007. Osteonecrosis of the jaw associated with bisphosphonate use: Presentation of seven cases and literature review. *Laryngoscope*, 117: 30-34.
- Purcell, P.M. and I.W. Boyd, 2005. Bisphosphonates and osteonecrosis of the jaw. *MJA*, 182: 417-418.
- Rinchuse, D.J., D.J. Rinchuse, M.F. Sosovicka, J.M. Robison and R. Pendleton, 2007. Orthodontic treatment of patients using bisphosphonates: A report of 2 cases. *Am. J. Orthod. Dentofacial Orthop.*, 131: 321-326.
- Scully, C., C. Madrid and J. Bagan, 2006. Dental endosseous implants in patients on bisphosphonate therapy. *Implant. Dent.*, 15: 212-284.
- Van Poznak, C. and C. Estilo, 2006. Osteonecrosis of the jaw in cancer patients receiving IV bisphosphonates. *Oncology (Williston Park)*, 20: 1053-1062.
- Zahrowski, J.J., 2007. Bisphosphonate treatment: An orthodontic concern calling for a proactive approach. *Am. J. Orthod. Dentofacial Orthop.*, 131: 311-320.
- Zarychanski, R., E. Elphee, P. Walton and J. Johnston, 2006. Osteonecrosis of the jaw associated with pamidronate therapy. *Am. J. Hematol.*, 81: 73-75.