

Infraocclusion of Primary Molars and Associated Dental Anomalies

K. Salem and B. Mirzaee

Department of pediatric dentistry, Faculty of Dentistry,
Guilan University of Medical Sciences, Rasht, Iran

Abstract: The purpose of present study was to investigate the prevalence of primary molar's ankylosis and associated dental anomalies in a group of Iranian children. After gaining parental consent, periapical radiographs were taken among those with ankylosis to determine missing premolars. During next two years a follow-up examination with the aid pantomograms took place to determine other clinical anomalies in permanent dentition. The prevalence of ankylosis was 15% (13.4% in males, 16.6% in females). More than 60% had more than one ankylosis tooth. The most common ankylosis tooth was the lower first primary molar. Missing was observed among 3 of ankylosed subjects, however none of the controls showed missing premolars. Other observed anomalies consisted of: hypoplastic defects on central incisors (5 vs. 2), macrodontia of upper incisors (3 vs 1), ectopic eruption of upper canines (23 vs. 5). The Radiographic examination confirmed ankylosis in 10.03% of cases. Annual follow up during the next two years showed spontaneous mobility or exfoliation in 98% of first primary molars. The chi-square test was used for analysis.

Key words: Dental ankylosis, aplasia, missing, ectopic eruption, prevalence, macrodontia

INTRODUCTION

Tooth ankylosis, the fusion of cementum or dentin to alveolar bone is an abnormality of tooth eruption. (Andesson *et al.*, 1984). It can occur at any time during eruption (Sidhu and Ali, 2001) or even after the establishment of occlusal contact (Becktor *et al.*, 2005). Clinically ankylosed teeth present infra-occlusion since they remain static whereas adjacent teeth move vertically because of the growth and development of the alveolar process (Araha *et al.*, 2004). The exact mechanism of ankylosis is unknown but it is probably due to developmental disturbance in the periodontium. Changes in distribution of Epithelial Rests of Malassez in the periodontium of ankylosed deciduous molars have been noted and thought to be to be aetiologically relevant to subsequent ankylosis (Winter *et al.*, 1997). It has been stated that ERM plays a significant role in maintaining periodontal ligament space, thereby preventing ankylosis (Becktor *et al.*, 2007).

As the epithelial rests of Malassez are histologically derived from the fusion of inner and outer enamel epithelium and dental follicle, enamel, cementum and PDL are all ectodermally derived, it is possible that a biological/genetic dysfunction of ectoderm might influence both tooth development and eruption (Becktor *et al.*, 2007). Research has indicated a close relationship between infra-occlusion of deciduous molars,

ectopic eruption of permanent teeth and certain types of anomaly such as aplasia (Winter *et al.*, 1997). The purpose of this study was to examine the relationship between dental ankylosis and aplasia of successor's tooth bud and ectopic eruption of maxillary canines to elucidate if ankylosis of primary molars can be a predictor of more complicated dental or eruptional abnormalities.

MATERIALS AND METHODS

The participants of this study were 1023 primary school children, aged 7-9 from both genders in the city of Rasht, Iran. All examinations performed by one operator with 85% inter-examiner reliability at selected schools. The study accomplished in 3 stages. At first stage, ankylosis was diagnosed clinically according to:

- Presence of at least 1 mm infraocclusion from the intact marginal ridge of adjacent normal tooth

In cases with difficult diagnosis, adjunct criteria were considered, including:

- Lack of occlusal contact
- Immobility

Teeth with defective marginal ridge, extensive carious lesions or large restoration includes stainless steel

crowns, were excluded from the study. According to above mentioned criteria. About 153 subjects (15%) showed dental ankylosis. At the second stage after gaining parental consent, periapical radiographs using bisecting angle technique, were taken from 139 ankylosed and their age and sex matched controls from the patients attending for regular visits and dental treatments at dental school. A later follow up performed at age 9 with taking Orthopantomographs to determine the status of maxillary permanent canine and other probable anomalies in permanent dentition as the third stage. Chi-square test used for analysis.

RESULTS AND DISCUSSION

A total of 1023 subject; 532 (52%) females and 491 (48%) males participated in this study. There were 153 subjects with 299 ankylosed teeth. Prevalence of primary molar's ankylosis was 15% for total sample with no significant difference between two genders $p = 0.19$. Considering the age, highest prevalence was found at age 9 (15.5%), although the difference between ages 7, 8 and 9 was not significant ($p = 0.08$).

Lower first primary molar were the most affected teeth, followed by lower second, upper first and upper second primary molar. More than 60% had more than one ankylosed primary molar. In regard of severity, 84.1% of ankylosed teeth were rated as slight, 14.4% as moderate (Fig 1) and 1.5% showed severe ankylosis (ankylosed teeth located at the level of gingiva). At the second stage, there were 139 subjects with ankylosis and 141 controls. It was found that girls have a higher chance to show ankylosis although, the difference between two genders was not significant (Odds Ratio = 1.06 (95% CI 0.66-1.06), (Table 1). Periapical radiographs at the site of ankylosis were taken from these subjects. Aplasia of successors was reported in 3 subjects (2.1%) with 6 ankylosed second primary molars bilaterally. Missing second premolars, included 2 of upper and 4 of lower second premolars. No missing premolars was observed in control group ($p < 0.05$). The difference was not significant. Radiographically, ankylosis was confirmed in 30 (10.03%) of clinically detected ankylosis.

Other observed anomalies in ankylosed group included: hypoplastic defects on central incisors, macrodontia of upper incisors, ectopic eruption of upper canines. Follow-up during the next two years revealed spontaneous mobility or exfoliation in 98% of first primary molars. The significant variables were Ectopically erupted canines $p < 0.001$ OR = 5.78 (95% CI 2.1-15/86), Hypoplastic defects on enamel (Table 2). Among 23 ectopically erupted canines in ankylosed group 16 were unilaterally.

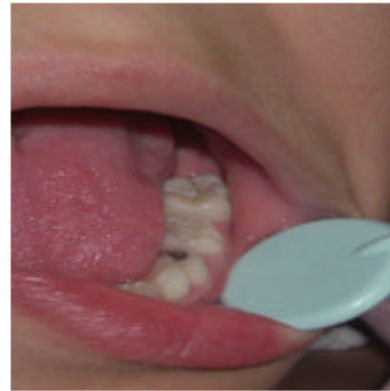

Fig. 1: Moderate ankylosis in lower primary molars

Table 1: Distribution according to gender in study groups at second stage of study

Status/Gender	Case (ankylosed)	Control	p-Value*
Male	62 (44.6)	61 (43.3)	$p = 0.81$
Female	77 (55.4)	80 (56.7)	Odds ratio = 1.06 (95% CI: 0.66-1.69)
Total	139 (100)	141 (100)	

*Chi square

Table 2: Distribution of observed anomalies in Ankylosed group in compare to controls

Status of ankylosis/Anomaly	case	control	Total	p-value
Aplasia of successor	3	0	3	NS
Ectopic canine	23	5	28	Sig $p < 0.001$
Macrodontia	3	1	4	NS
Supernumerary	1	1	2	NS
Hypoplastic defects on enamel	5	2	7	Sig ($p = 0.054$)

The criteria for detection ectopic eruption was eruption of canines from a more medial position in dental arch and with amore horizontal path of eruption (an average of 10 degrees) and overlapping the permanent lateral incisors (Fig. 2). (Camilleri *et al.*, 2008). Dental ankylosis is a common anomaly in primary dentition. In present study, the total prevalence was 15%, among 7-9 years of age children. Prevalence has been reported from 8-14% in 6-11 age group (Camilleri *et al.*, 2008) to 38.5% in some ethnic groups. The difference can be attributed to different ethnic and races and also according to different evaluation criteria (Koyoumdjisky and Steigman, 1982; Winter *et al.*, 1997). A previous study in Iranian children has showed a prevalence of 11.4% in 6-12 age group (Fallahinejad *et al.*, 1996). In this study, we selected our samples in the age range 7-9, because this can be a slice of population which they have a relative stabilization in dental arch that makes diagnosis more accurate and also a better visualization (Araba *et al.*, 2004). This age range has reported to have highest range of ankylosis by other investigations. (Koyoumdjisky-Kaye and Steigman, 1982).

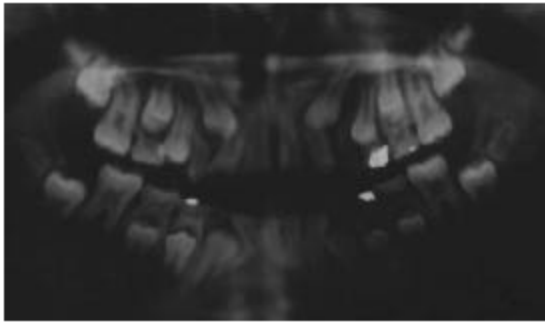


Fig. 2: Bilateral Ectopic Eruption of upper canines

In relation to gender, there was not significantly difference between males and females, however there was a more chance to have an ankylosed tooth. This is in agreement with many similar results are reported that a degree of gender linkage may be present in dental anomalies (Araha *et al.*, 2004; Beक्टर *et al.*, 2007; Fallahinejad *et al.*, 1996). Some discrepancies in developing occlusion are attributed to dental ankylosis such as delayed eruption rotated premolars, loss of arch length, tongue habits (Kuroi, 1985). In present study, we found none of these except slight rotation of premolars, however it was interesting to find increasing the arch length, may be due to reduced mesial drift and preserving the leeway space.

Similar results are also reported by Kuroi and Olson (1991), Camilleri *et al.* (2008), however persisting of second primary molars leads to anterior crowding in some cases because of not exchanging between primary and permanent premolar. It should be noticed that the majority of the cases rated as slight ankylosis and degree of ankylosis can be a determining factor in related occlusal disturbances (Kuroi and Olson, 1991). Ankylosis of primary molars has been reported to be associated with various anomalies in permanent dentition, such as taurodontism of first permanent molar, as well as impaction of succedaneous tooth, ectopic eruption of premolars/carine, aplasia of second premolars, tipping of the adjacent teeth and increased susceptibility to caries and periodontal disease (Suprabha and Pai, 2006).

Among these anomalies, we found aplasia of second premolars, Ectopic canines, Macrodonia, Supernumerary and Hypoplastic defects on enamel in association with ankylosed primary molar but the only significant variables were ectopic eruption of maxillary canines and hypoplastic incisors.

Hypoplastic defects on enamel of incisors showed a weak significant relationship. A close relationship between infraocclusion of deciduous molars, ectopic eruption of permanent teeth and certain types of anomaly such as dental aplasia has been showed previously (Winter *et al.*, 1997).

The prominent finding of canine ectopic eruption is important because of possible sequelae of ectopic canines. Impaction, root resorption in adjacent incisors, dentigerous cyst formation, infection and referred pain are among these sequelae. It is possible that the genes responsible for palatally displaced canines are those involved with the control of eruption (Camilleri, 2005; Casamassimo, 2005). The ectopic canines are found more frequently in females (Ericson and Kuroi, 2000) and this is in agreement with our findings. Resorption of adjacent roots has been reported in 48% of patients. We didn't found resorption on incisors may because of age of the patients at the time of Radiographic examination (age 9). In addition, routine extra and intra-oral views are underestimated the amount of root resorption and other techniques such as CT scan have better diagnostic value (Beक्टर *et al.*, 2005). We didn't found any case of ectopic eruption of maxillary first molars because of the age or spontaneous correction at the time of examination or low prevalence in our population. Some researchers report a close relationship between ectopic canines and molars (Bjerkkin *et al.*, 2008). Hypoplastic defects on central incisors showed a weak significant relationship with ankylosis, although it may relate with previous undiagnosed trauma to anterior teeth but it should be noticed that dental follicle, enamel, cementum and PDL are ectodermally derived. It is therefore possible that a biologic/genetic dysfunction of the ectoderm might influence both tooth development and tooth eruption. A biologically weak PDL would increase the risk of pathological root Resorption (Beक्टर *et al.*, 2005). Crown morphogenesis progresses through a series of stages known as bud, cap and bell. When crown formation is complete, the outer and inner dental epithelium fuses to form Hertwig's epithelial root sheat. HERS is believed to send an inductive message, probably by secreting enamel proteins to the facing ectomesenchymal pulp cells. These cells differentiate to odontoblasts and produce a layer of pre-dentin. The next event is taking place is formation of cementum on the root surface. HERS cells probably transform to cementoblasts, thus not only crown development but also development of the root and the periodontal membrane are influenced by these epithelial and ectomesenchymal interactions. Epithelial abnormalities therefore influence the morphology and function of root and PDM. The epithelial rests of Malassez (ERM) are developmental residues of HERS. They have a possible role in maintenance and remodeling of PDM, thereby preventing ankylosis. They might protect root from resorption and it is likely that continued eruption after mucosal penetration is dependent on remodeling activity in PDM (Beक्टर *et al.*, 2005).

CONCLUSION

We didn't find any relationship with aplasia and ankylosis, however it is reported that second premolar aplasia demonstrate significant association with infraocclusion, small maxillary laterals, enamel hypoplasia and palatal displacement of canines (Bjerklin *et al.*, 2008). Etiology of ectopic canines may be genetic and associated with other genetically interrelated dental anomalies. A single dominant gene is responsible for ectopic canines with incomplete penetration and highly variable expression (Winter *et al.*, 1997). Different dental anomalies may be the expressions of one syndrome with incomplete penetrance and each with variable expressivity (Sidhu and Ali, 2001).

REFERENCES

- Andesson, L., L. Blomlof, S. Lindskog and L. Hammarstrom, 1984. Tooth ankylosis, clinical, radiographic and histological assessments. *Int. J. Oral Surg.*, 13: 423-431.
- Aranha, A., C. Duque, J. Silva, C. Carvalho, B. Costa and M. Gomedia, 2004. Tooth ankylosis in deciduous teeth of children with cleft lip and/or palate. *Braz. Oral Res.*, 18: 329-332.
- Becktor, K.B., D. Nolting, J.P. Becktor and I. Kjær, 2007. Association between ectopic eruption of maxillary canines and first molars. *Eur. J. Orthod.*, 29: 350-353.
- Becktor, K.B., K. Steiniche and I. Kjær, 2005. Association between ectopic eruption of maxillary canines and first molars. *Eur. J. Orthod.*, 27: 186-189.
- Bjerklin, K., M. Al-Najjar, H. Karestedt and A. Andren, 2008. Agenesis of mandibular second premolars with retained primary molars. *Eur. J. Orthod.*, 30: 254-261.
- Camilleri, S., 2005. Maxillary canine anomalies and tooth agenesis. *Eur. J. Orthod.*, 27: 450-456.
- Camilleri, S., C.M. Lewis and F. MacDonald, 2008. Ectopic maxillary canines: Segregation analysis and twin study. *J. Dent. Res.*, 87: 580-583.
- Casamassimo, P.S., 2005. Examination, Diagnosis and Treatment Planning. In: *Pediatric Dentistry, Infancy Through Adolescence*, Casamassimo, P. and N. McTigue (Eds.). W.B. Saunders Co., Philadelphia, PA., USA., pp: 485-486.
- Ericson, S. and J. Kurol, 2000. Resorption of incisors after ectopic eruption of maxillary canines: A CT study. *Online Angle Orthod.*, 70: 415-423.
- Fallahinejad, M., M. Vaheed and N. Valaee, 1996. Epidemiologic assessment of primary molar's ankylosis in the city of Tehran (1994). *J. Dent.*, 27: 5-13.
- Koyoumdjisky-Kaye, E. and S. Steigman, 1982. Ethnic Variability in the prevalence of submerged primary molars. *J. Dent. Res.*, 61: 1401-1404.
- Kurol, J. and L. Olson, 1991. Ankylosis of primary molars - a future periodontal threat to the first permanent molars? *Eur. J. Orthod.*, 13: 404-409.
- Kurol, J., 1985. The effect of extraction of infraoccluded deciduous molars: A longitudinal study. *Am. J. Orthod.*, 87: 46-55.
- Sidhu, H.K. and A. Ali, 2001. Hypodontia, ankylosis and infraocclusion: Report of case restored with a fibre-reinforced ceramic bridge. *Br. Dent. J.*, 191: 613-616.
- Suprabha, B.S. and S.M. Pai, 2006. Ankylosis of primary molar along with congenitally missing first permanent molar. *J. Indian Soc. Pedod Prev. Dent.*, 24: 35-37.
- Winter, G.B., M.J. Gelibier and J.R. Goodman, 1997. Severe infra-occlusion and failed eruption of deciduous molars associated with eruptive and developmental disturbances in the permanent dentition: A report of 28 selected cases. *Br. J. Orthod.*, 24: 149-157.