

Effect of Infrared Irradiation of Oocysts on the Pathology of Experimental Cryptosporidiosis in Apparently Normal and Immunosuppressed Mice

Hafidh I. Al-Sadi and Saevan S. Al-Mahmood
Department of Pathology and Poultry Diseases,
College of Veterinary Medicine, University of Mosul, Mosul, Iraq

Abstract: The pathogenicity of infrared irradiated oocysts of local isolate of *Cryptosporidium* sp. in normal and immunosuppressed mice and pathogenesis of the experimental infection were studied. In a pilot study, the medium infectious dose of oocysts for normal mice was 2×10^3 oocysts and the suitable dose of infrared-rays to reduce substantially the infectivity of the oocysts was 700-750 nm at a distance of 48.5 cm and exposure time of 5 min. In apparently normal mice, clinical signs of the experimental infection appeared at the 2nd post-infection (p.i.) day, the parasite was seen in sections of the intestines at the 2nd p.i. day, pathological lesions appeared starting on the 2nd p.i. day and oocysts shedding started on the 4th p.i. day. In comparison, giving the medium infectious dose of the oocysts to immunosuppressed mice lead to more extensive clinical signs and lesions, additional appearance of the parasite in gastric pits and pyloric glands of the stomach and earlier shedding of the oocysts (3rd p.i. day). Infrared irradiation of the oocysts for 10, 15 or 20 min rendered the oocysts completely non-infective. When the oocysts were irradiated for 5 min and shown to apparently normal mice they caused only mild clinical signs which appeared after the 6th p.i. day and mild pathological lesions which appeared after the 6th day. Additionally, oocysts shedding started at the 8th p.i. day and the parasite was not seen in tissue sections up to the 10th p.i. day. When the irradiated oocysts were shown to the immunosuppressed mice, shedding of the oocysts started at the 6th p.i. day and only mild signs and symptoms were seen. Pathological lesions included necrosis and sloughing of tips of some of the intestinal villi and the infiltration of mononuclear cells in the muscularis mucosa of the colon. The parasite was not seen in any of the tissue sections.

Key words: Experimental cryptosporidiosis, infrared irradiation, oocysts, immunosuppression, mice, Iraq

INTRODUCTION

Cryptosporidiosis is caused by protozoan parasites of the genus *Cryptosporidium* (family Cryptosporidiidae, order Eucoccidiorida, subclass Coccidiasina, class Sporozoasida, phylum Apicomplexa). Currently, 18 valid species have been identified namely: *C. hominis* (humans), *C. parvum* (humans and other mammals), *C. andersoni* (cattle), *C. bovis* (cattle), *C. canis* (dogs), *C. muris* (mice), *C. felis* (cats), *C. wrairi* (guinea-pigs), *C. suis* (pigs), *C. fayeri* (red kangaroo), *C. macropodum* (grey kangaroo), *C. meleagridis* (turkeys and humans), *C. baileyi* (chickens), *C. galli* (adult hens and some wild birds), *C. varanii* (emerald monitor lizards), *C. serpentis* (snakes and lizards), *C. molnari* (fish: gilthead seabream) and *C. scophthalmi* (fish: turbot) (OIE Terrestrial Manual, 2008). Infections are usually acquired from water or food contaminated with infectious oocysts (Xiao *et al.*, 2004).

Gamma irradiation at 50 k Gy has been found to lead to a complete elimination of *C. parvum* oocysts excretion *in vivo* (Yu and Park, 2003). In another study, the *in vitro* infectivity of *C. parvum* on human ileocecal adenocarcinoma cells (HCT-8) was effectively reduced ($>2 \log_{10}$) by irradiation at 10 k Gy or more (Lee *et al.*, 2009). In a neonatal calf model, gamma irradiation at 0.4 k Gy was shown to be sufficient to kill oocysts (Jenkins *et al.*, 2004). No phenotypic evidence of either light or dark repair of UV-induced DNA damage of *C. parvum* was found (Shin *et al.*, 2001).

For the purpose of disinfection of *C. parvum*, 10 k Gy of gamma irradiation has been found to be an effective dose (Lee *et al.*, 2009).

The present study was designed to determine the effect of infrared irradiation on the viability and infectivity of *Cryptosporidium* sp. oocysts in apparently normal and immunosuppressed mice.

MATERIALS AND METHODS

Animals: Six-week old Balb/c white mice of both sexes obtained from the animal house of the College of Education, University of Mosul, Mosul, Iraq were used. They were harvested in plastic cages, kept in an air-conditioned room in the animal house of the College of Veterinary Medicine and shown food and water ad libitum. Examination of thin fecal smears shown from these mice and stained with hot Ziehl-Neelsen stain were performed to assure that they were free of *Cryptosporidium* oocysts. Animals free from *Cryptosporidium* oocysts were transferred to clean and disinfected cages and their feces were examined again for the presence of *Cryptosporidium* oocysts at 72 and 24 h prior to experimentation.

Fecal samples: One hundred fecal samples were directly collected from the rectum of 3 weeks old calves suffering from diarrhea in 6 different geographic locations in Ninevah province, Iraq. The samples were placed in nylon bags, marked and immediately transferred in ice-cooled containers (4°C) to the laboratory. Fecal examination was done at a period <24 h after collection (OIE Terrestrial Manual, 2008). *Cryptosporidium* sp. positive fecal samples were stored at 4°C in 2.5% K₂Cr₂O₇ (OIE Terrestrial Manual, 2008). *Cryptosporidium* oocysts were identified in fecal smears stained with the iodine stain (Ma and Soave, 1983), Koster's stain (Luna, 1968) and the hot Ziehl-Neelsen stain (OIE World Organization for Animal Health, 2005). Morphometric measurement of oocysts was done on 50 oocysts and the ranges and standard deviations of length and width were recorded (Xiao *et al.*, 2004). The measurement was done using a light binocular microscope stage micrometer and an eye-piece micrometer and the measurements were shown in micron. Isolation of the *Cryptosporidium* oocysts was done according to the technique described by Lazo *et al.* (1986). Counting of the numbers of oocysts per mL of the fecal sample was done according to the method described by Xiao *et al.* (2004).

The pilot study: In a pilot study, the medium infectious dose (ID₅₀) of the isolated *Cryptosporidium* was determined and it was 2×10³ oocysts and this dose was used in the various experiments. In this same study, the isolated *Cryptosporidium* were exposed to infrared irradiation using an Italian apparatus (Vavonerza Co., Itlay) in a dose of 700-750 nm at a distance of 48.4 cm for 5, 10, 15 and 20 min. Mice that were shown the medium infectious dose of the oocysts after 5 min irradiation shedded the oocysts in their feces within the 8th p.i. day.

Typical pathological lesions were seen in these animals at the 10th p.i. day with the appearance of the parasites in tissue sections shown from them at this period. Mice that were shown the irradiated medium infectious dose for 10, 15 and 20 min did not shed the oocysts during the whole experimental period indicating that exposure to infrared irradiation for these periods abolished the infectivity of the oocysts. Therefore, infrared irradiation of the oocysts used in this study was done for 5 min.

Experimental design: Three hundred and forty mice were used in 3 experiments. In the first experiment, 80 mice were subdivided into 2 equal groups. The first group was shown 2×10³ oocysts of *Cryptosporidium* orally and on the 2nd, 4th, 6th and 10th p.i. days, 10 mice were euthanatised and tissue specimens were collected from the intestines, stomach, pancreas, lungs, liver, spleen and kidneys. These specimens were fixed in 10% formalin. The second group was divided into two equal subgroups. Distilled water was shown orally to the first subgroup (control positive) and the second subgroup served as control negative subgroup. Tissue specimens were collected from the mice following euthanasia at the same periods (2, 4, 6 and 10 days) and fixed as described before. In the second experiment, 160 mice were used and divided into 3 groups of 40, 40 and 80 mice each. Infrared irradiated oocysts (2×10³ oocysts) were shown orally to the first group. Mice of the second group was shown 125 µg dexamethasone intraperitoneally daily for 6 days. At the 7th p.i. day, 2×10³ infrared irradiated oocysts were shown orally to these mice. The 3rd group was subdivided into 4 equal subgroups and the first subgroup was shown infrared irradiated distilled water orally, the second subgroup was shown distilled water orally (positive control), the third subgroup served as negative control and the 4th subgroup was shown 125 µg dexamethasone intraperitoneally daily for 6 days. At the 2nd, 4th, 6th and 10th p.i. days, 5 mice were euthanatised and tissue specimens were collected and fixed as described before.

One hundred mice were used in the 3rd experiment and the mice were divided into 2 groups. Group one (40 mice) was shown 125 µg dexamethasone intraperitoneally daily for 6 days and at the 7th p.i. day was shown 2×10³ non-irradiated oocysts orally. At the 2nd, 4th, 6th and 10th p.i. day, 10 mice were euthanatised and tissue specimens were collected and fixed as described before. Mice of the second group (60 mice) were divided into 3 equal subgroups. Subgroup one was shown distilled water orally (control positive), subgroup 2 served as negative control and the 3rd subgroup was shown 125 µg dexamethasone intraperitoneally for 6 days.

Five mice were euthanised from each subgroup on the 2nd, 4th, 6th and 10th p.i. days and tissue specimens were collected and fixed as described before.

Histopathological examination: Following fixation of the tissue specimens in 10% formalin for 48 h, they were trimmed to suitable sizes, washed, dehydrated, cleared in xylol, embedded in paraffin wax, sectioned at 5-6 μM thickness, stained with hematoxylin and eosin and examined with light microscope (Luna, 1968).

RESULTS AND DISCUSSION

Cryptosporidium oocysts were identified in 23 out of the 100 fecal samples (23%) that were collected from the <3 weeks old diarrheic calves. The average measurements of the oocysts were 6.5 (length) X 5.6 μM (width). In apparently normal mice that were shown 2×10^3 oocysts orally, the percentage of infection was 100% at the 6th p.i. day and the mice started shedding the oocysts at the 4th p.i. day. Signs and symptoms appeared at the 2nd p.i. day and increased in severity with time and they included dullness, anorexia and dehydration. Gross lesions included congestion of most of the viscera particularly the intestines. Microscopically, there were necrosis of the tips of some of the intestinal villi, hyperplasia of Peyer's patches, shortening and fusion of some of the intestinal villi and the infiltration of mononuclear cells in the lamina propria (Fig. 1). *Cryptosporidium* parasite was seen in the intestinal epithelial cells (submembranous location). At the 6th p.i. day, large numbers of the parasite were seen attached to the luminal surface of the intestinal epithelial cells and the presence of large quantity of tissue debris in the lumen of the small intestine (ileum) (Fig. 2). The parasite was also seen in the intervillar spaces. These lesions became more extensive at the 10th p.i. day. *Cryptosporidium* oocysts were not detected in the feces of mice of the control groups. Similarly, signs and symptoms, gross and histopathological lesions and the parasite were not detected in these animals.

In apparently normal mice that were shown the infrared irradiated medium infectious dose of the oocysts, the infected mice shedded the oocysts at the 8th p.i. day. Signs and symptoms appeared after the 6th p.i. day and included dullness, anorexia and dehydration. Grossly, only mild congestion of the intestines, liver, spleen and kidneys was noted. Microscopic lesions included hyperplasia of Peyer's patches and necrosis and sloughing of the tips of some of the villi and their accumulation in the lumen. These lesions increased in severity from the 4th to the 6th p.i. day and on the 10th p.i. day shortening and fusion of some of the villi of the

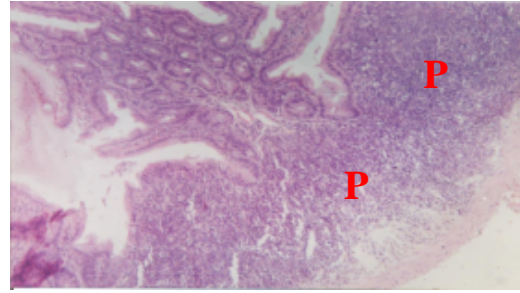


Fig. 1: Photomicrograph of the ileum of a mice 2 days after being experimentally infected with *Cryptosporidium* sp. Hyperplasia of the Peyer's patches (P) is evident. H and E x100

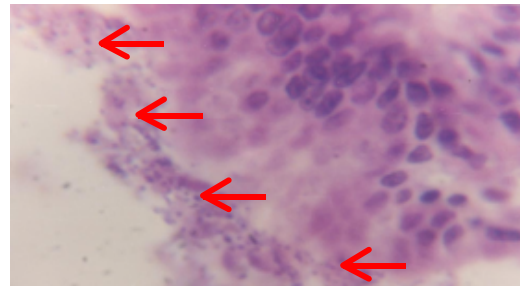


Fig. 2: Photomicrograph of the ileum of a mice 6 days after being experimentally infected with *Cryptosporidium* sp. The attachment of numerous cryptosporidia to epithelial cells of the villi could be seen (arrows). H and E x1000

small intestine (ileum) were seen. The parasite was not observed in any of the tissue sections. Shedding of the oocysts, signs and symptoms and pathological lesions were not found in any of the control mice.

When the infrared irradiated medium infectious dose of the oocysts were shown to the immunosuppressed mice, shedding of the oocysts in feces started at the 6th p.i. day. Mild signs and symptoms appeared after this period (6th p.i. day). Grossly, congestion of the intestines and spleen appeared on the 6th p.i. day onward. The microscopic lesions appeared on the 4th p.i. day and continued up to the 10th p.i. day. They included necrosis and sloughing of tips of some of the intestinal villi and the infiltration of mononuclear cells in the muscularis mucosa of the colon (Fig. 3). The parasite was not seen in any of the tissue sections. Oocysts shedding, signs and symptoms and pathological lesions were not seen in any of the control mice. Giving the medium infectious dose of the non-irradiated oocysts to the immunosuppressed mice lead to the appearance of the oocysts in the feces of the animals at the 4th p.i. day. Signs and symptoms included

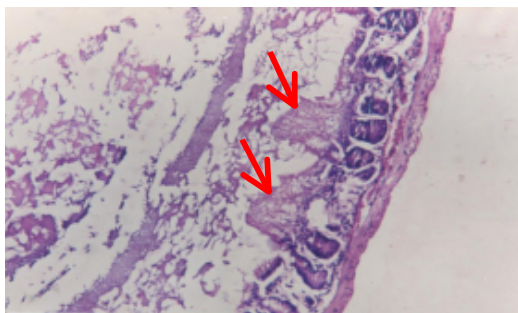


Fig. 3: Photomicrograph of the small intestine of a mice 10 days after being experimentally infected with infrared irradiated *Cryptosporidium* sp. Necrosis of tips of some of the villi is evident (arrows). Sloughing and accumulation of the necrotic material in the lumen are also evident. H and E x100

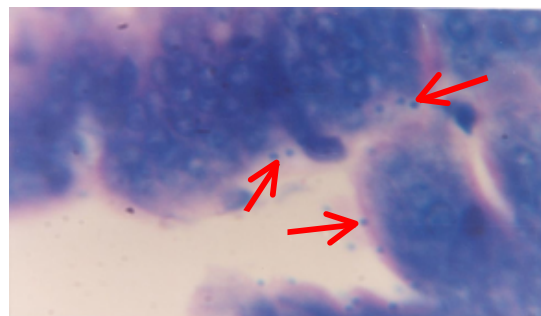


Fig. 4: Photomicrograph of the small intestine of immunosuppressed mice 6 days after being experimentally infected with *Cryptosporidium* sp. The presence of the parasite in attachment with and inside the epithelial cells could be seen (arrows). H and E x100

dullness, anorexia, redness of the skin and alopecia. Furthermore, two mice died at the 2nd p.i. day, another one died at the 5th p.i. day and a fourth one died at the 8th p.i. day. Grossly, congestion of the viscera and swelling of the liver and spleen were observed at the 2nd p.i. day. These lesions were also seen at the 4th, 6th and 10th p.i. days. Microscopic lesions appeared at the 2nd p.i. day and included shortening and fusion of some of the intestinal villi (ileum).

Necrosis and sloughing of tips of the intestinal villi were also observed. At the 4th p.i. day, large numbers of the parasite were noted attached to the intestinal epithelial cells and inside these cells (Fig. 4). Congestion of the muscularis mucosa of the stomach and focal infiltration of mononuclear cells were observed in the fundic region of the stomach. Large numbers of the parasite were also noted in the gastric pits, parietal cells and the immature cells of the stomach.

Atrophy of the bronchial-associated lymphoid tissue was seen. At the 6th p.i. day, large numbers of the parasite were identified in mucosal cells lining the intestines and in cells of the intestinal glands. There was also necrosis of tips of some of the intestinal villi. At this stage, there were also infarction of the renal cortex and infiltration of mononuclear cells in the renal interstitium. At the 10th p.i. day, large numbers of the parasite were seen attached to epithelial cells lining the intestines. Necrosis of tips of some of the intestinal villi was observed and some of the necrotic tips sloughed and accumulated in the lumen (Fig. 5). A similar necrosis was seen in the superficial layers of the gastric mucosa. The parasite was numerous in the pyloric glands of the stomach and there were focal mononuclear cell infiltrations in the gastric submucosa.

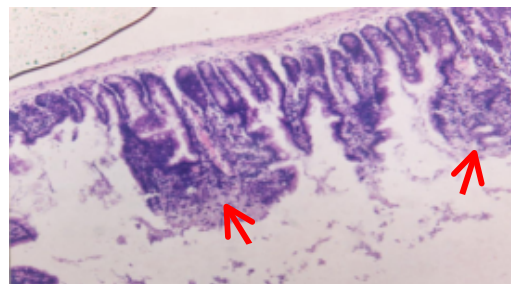

Fig. 5: Photomicrograph of the small intestine of immunosuppressed mice 10 days after being experimentally infected with *Cryptosporidium* sp. Note shortening and fusion of some of the villi (arrows). H and E x100

In the present study, cryptosporidial oocysts were isolated from fecal samples that were collected from diarrheic calves in multiple locations in Ninevha province, Iraq. According to staining properties and morphometry of the oocysts ($6.5 \times 5.6 \mu\text{m}$) and confinement of the lesions of experimental infection in mice to the small intestine as opposed to the stomach, the oocysts were diagnosed to be of *Cryptosporidium parvum*. However, since the Polymerase Chain Reaction (PCR) and the Restriction Fragment Length Polymorphism (RFLP) and/or sequencing were not done in this study the parasite was referred to as *Cryptosporidium* sp. (Xiao *et al.*, 2004; OIE Terrestrial Manual, 2008).

When the normal mice were shown orally the medium infectious dose of the oocysts the infection was mainly intestinal. The infected mice started shedding of the oocysts at the 4th p.i. day and they were dull, anorexic and dehydrated. Pathological lesions appeared in the 2nd

p.i. day onward and they included shortening of the villi, fusion of some of the villi, hypertrophy of the crypts of Lieberkühn and exfoliation of tips of some of the villi. *Cryptosporidium* were numerous in the microvillus border of the villi particularly in the ileum. Infiltrations of neutrophils and mononuclear cells were present in the lamina propria. These findings are in accordance with those described by others (OIE World Organization for Animal Health, 2005; Xiao *et al.*, 2004; Brown *et al.*, 2007). Infiltration of inflammatory cells in the intestinal mucosa and submucosa in case of cryptosporidiosis has been postulated to be due to attraction caused by proinflammatory cytokines released from infected epithelium (Tizard, 2004; Brown *et al.*, 2007).

When the infrared irradiated medium infectious dose of *cryptosporidium* oocysts was shown to apparently normal mice, shedding of the oocysts by the infected mice were delayed up to the 8th p.i. day. A pronounced decrease in the severity of signs and symptoms were noted and their appearance was delayed up to the 6th p.i. day. Furthermore, only mild pathological lesions were seen and the parasite was not seen in any of the tissue sections during the whole experimental period. These findings indicated that infrared irradiation in the dose used in this study caused a marked reduction in the infectivity and pathogenicity of the oocysts. However, a complete elimination of the *cryptosporidia* oocysts excretion was not obtained. These findings are comparable to those obtained by others using other type of irradiation (Yu and Park, 2003; Lee *et al.*, 2009). Gamma irradiation at a dose of 0.6-2.0 k Gy has been found to be efficient in controlling the coccidian parasites *Toxoplasma gondii* and *Eimeria necatrix* (Singh and Gill, 1975; Song *et al.*, 1993; Dubey *et al.*, 1996). It has been shown that the excystation rate was the same in *C. parvum* oocysts receiving 2 k Gy irradiation and non-irradiated oocysts but it has been also shown that 20 and 50 kGy irradiations reduced excystation rates of 50 and 0%, respectively (Kato *et al.*, 2001). Lee *et al.*, 2009 shown that for the purpose of disinfection of *C. parvum*, 10 k Gy of irradiation could be an effective dose. In the present study, infrared irradiation of the *Cryptosporidium* oocysts in a dose of 700-750 nm at a distance of 48.4 cm for 10, 15 and 20 min abolished the infectivity of the oocysts.

The administration of the infrared irradiated medium infectious dose of *cryptosporidium* oocysts to the immunosuppressed mice caused the mice to shed the oocysts at the 6th p.i. day and exhibited only mild signs and symptoms at this period. Gross and microscopic lesions appeared at the 4th p.i. day and the parasite was not seen in the tissue sections for the whole period of the

experiment. From these results, it could be said that immunosuppression alleviated some degree of the lost infectivity of the oocysts. These findings provide further evidence of the seriousness of cryptosporidiosis in certain immunosuppressed individuals (Fantry, 2000; Hunter and Nichols, 2002).

Giving the non- irradiated medium infectious dose of *cryptosporidium* oocysts to the immunosuppressed mice led to the appearance of oocysts in the feces of the mice at the 4th p.i. day, the occurrence of severe signs and symptoms and more severe pathological lesions at the 2nd p.i. day. Numerous *Cryptosporidia* were seen in the tissue sections as early as the 4th p.i. day.

CONCLUSION

Infrared irradiation of the *Cryptosporidium* oocysts at a dose of 700-750 nm at a distance of 48.5 cm and exposure time of 5 min reduced the infectivity of the oocysts in mice. Extending the exposure time to 10, 15 and 20 min abolished the infectivity of the oocysts. The administration of infrared irradiated oocysts (5 min exposure) to apparently normal mice delayed the appearance of signs and symptoms, pathological lesions and shedding of oocysts. Furthermore, the parasite was not seen in tissue sections shown from organs of infected animals. Giving the infrared irradiated oocysts to immunosuppressed mice lead to similar results but with more severe pathological lesions.

ACKNOWLEDGEMENT

The researcher extend thanks to the College of Veterinary Medicine, University of Mosul for financial and technical support.

REFERENCES

- Brown, C.C., D.C. Baker and I.K. Barker, 2007. Alimentary System. In: Jubb, Kennedy and Palmer's Pathology of Domestic Animals, Maxie, M.G. (Ed.). 5th Edn., Saunders-Elsevier, Edinburgh, pp: 274-277.
- Dubey, J.P., M.C. Jenkins and D.W. Thayer, 1996. Irradiation killing of *Toxoplasma gondii* oocysts. J. Eukaryot. Microbiol., 43: 123-125.
- Fantry, L., 2000. Gastrointestinal infections in the immunosuppressed host. Curr. Opin. Gastroenterol., 16: 45-50.
- Hunter, P.R. and G. Nichols, 2002. Epidemiology and clinical features of *Cryptosporidium* infection in immunocompromised patients. Clin. Microbiol. Rev., 15: 145-154.

- Jenkins, M., J. Higgins, K. Kniel, J. Trout and R. Fayer, 2004. Protection of calves against cryptosporidiosis by oral inoculation with gamma-irradiated *Cryptosporidium parvum* oocysts. J. Parasitol., 90: 1178-1180.
- Kato, S., M.B. Jenkins, W.C. Ghiorse and D.D. Bowman, 2001. Chemical and physical factors affecting the excystation of *Cryptosporidium parvum* oocysts. J. Parasitol., 87: 575-581.
- Lazo, A., O.O. Barriga, D.R. Rdeman and S. Bech-Nielsen, 1986. Identification by transfer blot of antigens reactive in the enzyme-linked immunosorbent assay (ELISA) in rabbits immunized and a calf infected with *Cryptosporidium* sp. Vet. Parasitol., 21: 151-163.
- Lee, S.U., M. Joung, T. Nam, W.Y. Park and I.R. Yu, 2009. Quantitative evaluation of infectivity change of *Cryptosporidium parvum* after gamma irradiation. Korean J. Parasitol., 47: 7-11.
- Luna, L.G., 1968. Manual of Histological Staining Methods of the Armed Forces Institute of Pathology. 3rd Edn., The Blakiston Division, McGraw-Hill Book Co., New York.
- Ma, P. and R. Soave, 1983. Three steps stool examination for cryptosporidiosis in 10 homosexual men with protracted watery diarrhoea. J. Infect. Dis., 147: 824-828.
- OIE Terrestrial Manual, 2008. Chapter 2.9.4: Cryptosporidiosis. http://www.oie.int/Eng/normes/mmanual/2008/pdf/2.09.04_CRYPTO.pdf.
- OIE World Organization for Animal Health, 2005. Manual of Diagnostic Tests and Vaccines for Terrestrial Animals. 5th Edn., OIE, UK.
- Shin, G.A., K.G. Linden, M.J. Arrowood and M.D. Sobsey, 2001. Low-pressure, UV inactivation and DNA repair potential of *Cryptosporidium parvum* oocysts. Applied Environ. Microbiol., 67: 3029-3032.
- Singh, J. and B.S. Gill, 1975. Effect of gamma-irradiation on oocysts of *Eimeria necatrix*. Parasitology, 71: 117-124.
- Song, CC., X.Z. Yuan, L.Y. Shen, X.X. Gan and J.Z. Ding, 1993. The effect of cobalt-60 irradiation on the infectivity of *Toxoplasma gondii*. Int. J. Parasitol., 23: 89-93.
- Tizard, I.R., 2004. Veterinary Immunology an Introduction. 7th Edn., W.B. Saunders Co., Philadelphia.
- Xiao, L., R. Fayer, U. Ryan and S.J. Upton, 2004. *Cryptosporidium* taxonomy: Recent advances and implications for public health. Clin. Microbiol. Rev., 17: 72-97.
- Yu, J.R. and W.Y. Park, 2003. The effect of gamma-irradiation on the viability of *Cryptosporidium parvum*. J. Parasitol., 89: 639-642.