

## **Insights on Central and Peripheral Venous Catheterization; Biology, Anatomy, Surgical Aspects and Nursing Management: Our Experience**

<sup>1</sup>C. Lo. Piccolo, <sup>1</sup>L. Lipari, <sup>2</sup>G. Cocorullo, <sup>1</sup>V. Valenza and <sup>1</sup>F. Carini

<sup>1</sup>Department of Experimental Medicine, Faculty of Anatomy and Histology,

<sup>2</sup>Department of General and Urgent Surgery, University of Palermo, Sicilia, Italy

---

**Abstract:** After a review of the main anatomical districts of relevance to central and peripheral venous catheterization, the researchers analyze the primary guidelines for the management of cannulation of central and peripheral venous catheters; a background study relative to this subject is then carried out. The aim of the present study is to review the main central and peripheral catheterization methods and to share the experience with particular emphasis on analyzing common complications.

**Key words:** Central venous catheter, peripheral venous catheter, intravenous port system, nursing management, surgical aspects, Italy

---

### **INTRODUCTION**

In surgical management, a thorough knowledge of the vascular bed is essential for a successful procedure. Anatomists and surgeons have reported a certain degree of anatomical variations that are of great interest in their field of research. The present manuscript is the result of a collaboration between the School of Nursing, The Department of Surgery and Department of Human Anatomy, its aim being to analyze the morphology and main variants of the blood vessels that are relevant to the positioning of venous and peripheral central catheters, as well as to evaluate the percentage of complications related to the positioning of these catheters. Before performing any kind of surgical procedure, the patient's vital signs are monitored, a Peripheral Venous Catheter (PVC) is inserted often with the addition of a Central Venous Catheter (CVC); a perfect knowledge of vascular anatomy, a proper cannulation technique performed by the physician in collaboration with the nurses and successive administration of medication through catheters carried out by the nursing staff contribute greatly to the success rates of surgical procedures. Variable doses of crystalloids, colloids, blood, serum and platelets can be administered to the patient via the CVC and the PVC, allowing the normal vital parameters to be restored. In addition to surgical applications, CVC and PVC are widely used in emergency medicine, oncological disciplines and other medical fields. Identifying a valid venous location for catheter insertion in critical patients facilitates the care and healing process. Evolutions in

medical care mean that patient management is increasingly taking place not only in hospitals but can also continue in other facilities such as hospices or residential health and rehabilitation clinics; therefore, all nursing staff, regardless of the setting in which they assist a patient undergoing intravenous therapy must be competent in central and/or peripheral catheter management.

The transformation of the nursing profession in Italy, both in terms of expertise and responsibility, endorsed by Italian legislation (Ministerial Decree 739/94 relative to Professional Profile, Law 42/99 that defines nursing as a healthcare occupation); as well as the code of nursing Deontology of 1996, call for a key role for nursing staff in patient management and education; this includes issues related to venous catheter management. The patient must be helped to accept the transformation of his/her life, potential changes resulting from the medical condition, sometimes for extended periods of time as well as the presence of the catheter device necessary for his/her treatment program but not devoid of possible complications.

**Fundamentals of anatomy:** A brief analysis of the principal central and peripheral blood vessels is presented that is chosen for venous catheterization. The superficial veins of the upper limb run in the deep layer of subcutaneous connective tissue and are not satellites of the arteries. They are surrounded by abundant circular and longitudinal smooth muscle layers. Their valves are fewer than those of deep veins and they are joined by anastomoses, being connected to the deep veins via

anastomotic branches without valves. The cephalic vein arises at the confluence of the first dorsal metacarpal vein, the cephalic vein of the thumb and venous branches of the thenar eminence; passing along the radial surface of the volar forearm until the cubital crease of the elbow continuing along the bicipital groove into the deltopectoral groove and merging with the axillary vein just below the clavicle. In the cubital crease region, the cephalic vein gives off the median vein of the elbow, anastomosed with the deep veins that medially joins the basilic vein. In its course, the cephalic vein receives connecting branches from cutaneous veins of the volar and dorsal surfaces of the forearm and the lateral surfaces of the arm and shoulder. The basilic vein begins at the confluence of the fourth dorsal metacarpal vein, the salvatella vein and venous branches of the hypothenar eminence, running up the posterior surface of the ulnar side of the forearm and inclining forward to the anterior surface below the elbow. Here, it is joined by the vena mediana cubiti, a branch of the cephalic vein and ascends obliquely into the medial bicipital groove, perforating the deep fascia a little below the middle of the arm ending in the medial brachial vein. The subclavian vein, of great importance with regard to central venous catheterization, collects blood from the upper limb superficial regions of the head and neck as well as from the upper chest. It begins as a direct continuation of the axillary vein, extending from the clavicle to the sternoclavicular articulation, where it joins the internal jugular vein to form the brachiocephalic vein. Its mean diameter is approximately 13 mm and it is provided with a pair of valves near its two terminations. The only tributary of the subclavian vein is the external jugular vein. The external jugular vein originates on a level with the angle of the mandible, being formed by the junction of the posterior auricular vein with an anastomotic venous branch of the posterior facial vein. It runs perpendicularly down the side of the neck, covered by the platysma muscle, crossing the sternocleidomastoideus obliquely upon reaching the upper margin of the clavicle, it deepens, ending in the subclavian vein near where the latter unites with the internal jugular vein. The internal jugular vein collects effluent blood from the head and from the deep regions of the neck. It begins in the jugular foramen at the base of the skull being directly continuous with the transverse sinus. It runs down the side of the neck along the lateral wall of the pharynx behind the internal carotid artery, then lateral to the common carotid artery, under the sternocleidomastoid muscle. It joins the subclavian vein, thus forming the brachiocephalic vein. In its initial tract, the internal jugular vein is located in proximity to the glossopharyngeal, vagus and hypoglossal accessory

nerves; forming, together with the vagus nerve and the common carotid artery, the vascular-nervous bundle of the neck, where it runs laterally to the artery and anterolaterally to the nerve. It is 12-15 cm long and its diameter increases from top to bottom from 9 mm in the initial section to 12 mm in the final section. The femoral vein collects all effluent blood from the superficial circulation (great and small saphenous veins) as well as that from the deep venous circulation of the foot, leg and most of the upper leg. The great saphenous vein originates from the medial marginal vein anterior to the medial malleolus, running up the medial side of the leg where it ascends vertically; at the knee, it forms an anterior concavity and courses to the anteromedial surface of the upper leg where it runs along the medial margin of the sartorius muscle until it reaches the femoral triangle. Near the fossa ovalis, it forms a deep downward curve and continues into the femoral vein. Throughout its course, excluding the short final section, the great saphenous vein remains subcutaneous and epifascial. It anastomoses with the small saphenous vein by means of numerous branches. The anterior and posterior tibial veins form a part of the deep veins of the lower limb; they collect blood from the deep regions of the foot and the leg. The anterior tibial veins originate from deep veins of the dorsal region of the foot while the posterior tibial veins arise from deep veins of the plantar region; they ascend along the leg following the course of corresponding arterial branches; they join at the tendinous arch of the soleus muscle to form the popliteal vein. The popliteal vein carries blood from the deep regions of the foot and leg. It begins under the tendinous arch of the soleus muscle where the anterior and posterior tibial veins join.

**CVC and PVC management guidelines:** For the procedure of peripheral vein cannulation, the researchers observe the following guidelines (Fujita and Namiki, 2008):

- Lower the limb below the body level and apply a tourniquet in the appropriate position
- Locate a vein with adequate size that is also as straight and immobile as possible; disinfect the skin
- Stabilize the skin by straightening it over the entry point
- Insert the needle approximately 0.5-1 cm from the vein with the bevel of the needle upward at a slight angle in relation to the cutaneous surface
- As soon as free flow of blood is observed in the syringe, withdraw guide wire, simultaneously inserting the plastic catheter in the vein. No resistance should be present. Remove the tourniquet

- Apply pressure to the vein at the end of the catheter in order to avoid bleeding when the guide wire is removed. Withdraw the needle and connect the catheter to the infusion line with the eventual three way tap
- Fix the catheter in place with appropriate sterile bandage (Gorski, 2009)

**External jugular vein cannulation technique:**

- Place patient in trendelenburg position with the head turned in the opposite direction from the vein chosen for cannulation (Milagry *et al.*, 2008)
- Use your finger to apply pressure on the vein above the clavicle in order to achieve a tourniquet effect; this procedure usually requires the intervention of an aide
- Disinfect the skin
- Align the cannula with the vein, aiming toward the shoulder on the same side, maintaining the skin taut to stabilize the vein
- Proceed following the instructions for peripheral vein cannulation (Hertzog and Waybill, 2008)

**Central venous catheterization:** This procedure is applied when peripheral veins are not available or when invasive hemodynamic monitoring or administration of hyperosmotic solutions is required.

**Internal jugular vein catheterization:** Catheterization of the internal jugular vein is preferable to that of the subclavicular vein because the former has minimal risk of inadvertent pleural puncture. This should be taken into account especially when a CVC is urgently needed for a patient with precarious cardiopulmonary condition.

**Insertion techniques:** It is preferable to perform the catheterization on the right side for the following reasons:

- The right pleural cupula is lower than the left one
- The right jugular vein provides the most direct route to the superior vena cava
- There is no risk of puncturing the thoracic duct

There are several types of approaches described in the literature; the best is always the one with which the operator is most familiar. However, the patient's head must be turned to the opposite side to the correct degree required by the technique that is being employed (Lapostolle *et al.*, 2007).

**Posterior approach:** With the patient's head rotated to the opposite side, the needle is inserted at the point where

the middle and lower third of the lateral or posterior margin of the sternocleidomastoid muscle merge (5 cm above the clavicle or where the external jugular vein crosses the muscle). The needle is pointed towards the jugular notch at a 45° angle to the skin in the sagittal plane and at 15° in the frontal plane.

**Axial approach:** With the patient's head slightly rotated to the opposite side, Sedillot's triangle formed by the superior margin of the clavicle and both heads of the sternocleidomastoideus is located. The needle is inserted in the center of the triangle in the caudal direction, parallel to the sagittal plane, at approximately 30° angle to the frontal plane.

**Anterior approach:** The position of the carotid artery is identified by palpation with the finger tips and it is compressed medially to move it away from the internal jugular vein running beside it. The needle is inserted by the anterior margin of the sternocleidomastoideus, approximately 5 cm above the clavicle, at a 30-40° angle to the frontal plane, proceeding downward and outward, toward where the middle third and the internal third of the clavicle merge.

**Subclavian vein catheterization:** Compared with the internal jugular vein, subclavian vein catheterization allows the catheter to be fixed better with a greater freedom of movement of the neck and a lesser risk of infection. It is therefore preferred by many when a long term catheterization is required.

Even in experienced hands, especially when dealing with an emergency, the risk of inducing a pneumothorax should always be kept in mind. Subclavian catheterization can be carried out by two different approaches: the subclavicular approach with an elevated risk of puncturing the pleural cupula and the infraclavicular approach which is strongly recommended because of the lower incidence of the aforementioned complication.

**Subclavicular approach:** The point where the outer margin of the clavicle meets the clavicular head of the sternocleidomastoid is located. The needle is inserted in a caudal direction at this point, at a 45° angle to the sagittal plane and at a 15° angle to the frontal plane. The vein should be encountered within 1-3 cm. The bevel should be oriented so as to prevent the passage of the guide wire or catheter into the ipsilateral internal jugular vein.

**Infraclavicular approach:** The needle is inserted 1 cm below the junction of the middle and medial thirds of the clavicle. The forefinger is placed on the suprasternal

notch; the needle is then directed toward a point just above and behind the finger, keeping the bevel oriented to slide along the posterior clavicle surface. The needle should remain parallel to the frontal plane; the vein is usually encountered within 3-5 cm.

**Femoral vein catheterization:** Disadvantages commonly attributed to this type of catheterization are associated to the difficulty of maintaining asepsis in the groin area, making other means of access for long-term catheterization preferable over this approach. However, in emergency situations, femoral access may be very useful. Locating the femoral vein usually requires the presence of a femoral arterial pulse and in its absence, catheterization of the femoral vein can be very difficult. The femoral artery is identified by palpation or if no pulse is detected, the midpoint between the anterior superior iliac spine and the pubic symphysis is used. A needle with syringe is inserted two fingers widths below the inguinal ligament, medial to the artery, directing the needle upward at a 45° angle to the skin or the frontal plane, while maintaining aspiration. When blood is seen in the syringe, the needle is lowered, making it more parallel to the frontal plane; once the correct position is verified, the guide wire is inserted and catheterization is continued following the Seldinger technique.

**Subclavian vein advantages (CVC):**

- Ease of access
- Allows a long-term cannulation
- Greater comfort for the patient
- Ease of management
- Less visible when patient is dressed

**Disadvantages/complications:**

- Pneumothorax caused by pleural cupula puncture and subsequent air ingress
- Hemothorax caused by laceration of the subclavian artery or vein
- Gas embolism due to aspiration of air into the vein
- Increased risk of venous thrombosis and stenosis

**Internal jugular vein advantages (CVC):**

- Ease of access
- Allows a long-term cannulation
- Greater comfort for the patient

**Disadvantages/complications:**

- Pneumothorax caused by pleural cupula puncture and subsequent air ingress
- Hemothorax caused by laceration of the subclavian artery or vein

- Gas embolism due to aspiration of air into the vein
- Increased risk of venous thrombosis and stenosis

**Femoral vein advantages:**

- Superficial vein with large diameter
- Easy to locate even in patients under shock
- No risk of fatal complications

**Disadvantages/complications:**

- Increased risk of infection
- Especially susceptible to infection in the cannulation site
- Significant risk of Deep Vein Thrombosis (DVT)
- Impairs patient mobility
- Disliked by patients due to the lack of privacy

**Precautions and complications:** Establishing a venous access for administration of medications and fluids carries a certain risk of complications. Common to all venipuncture and catheterization techniques are local long-term complications, such as thrombosis and phlebitis, as well as systemic complications such as sepsis and pulmonary thromboembolism. Particular attention should be paid to avoid short term complications of central venous catheterization in the cephalic vein area. This procedure is at a particular risk of gas embolism and injury to adjacent anatomical structures, especially to the pleural cupula and the subclavian and carotid arteries. Staff members responsible for injections and venous catheterizations must take appropriate precautions to protect themselves as well as the patient, from transmission of infectious diseases by washing hands thoroughly and appropriately disposing of needles and other sharp instruments.

**The final position of the central venous catheter:**

Incorrect positioning of the central venous catheter (3-18% of cases in the literature) can be a serious risk to the patient (arrhythmias, anatomic lesions, incorrect evaluation of hemodynamics). It is important that in its final position, the tip of the central venous catheter is located 3-4 cm from the right atrium and should not be in contact with the atrial wall. Before catheterization, it is necessary to assess the anatomic conformation of the patient to estimate how far to insert the catheter. After catheterization, the final position of the probe should always be verified by means of a thoracic radiograph. During catheterization, it is common practice to monitor the P-wave with the ECG through the main way of the catheter filled with saline solution or through the metallic guide wire J-shaped at its extremity. In both cases, the ECG is detected at the distal end of the probe, initially

displaying normal P-waves similar to those registered contemporarily at the skin. When the catheter enters the right atrium, the P-waves alter unmistakably given the proximity of the sinoatrial node, widening and spiking. The catheter is then retracted until normalization of the P-wave indicates transition into the vena cava. From this spot, the final position is safely reached by retracting the catheter for another 3-4 cm.

**Using subcutaneous ports:** The most popular among these devices is undoubtedly the dialock which is nothing more than a metallic valve connected to permanent silicone twin catheters (Del Pozo *et al.*, 2006). The port is implanted into a surgically created subcutaneous pouch under the clavicle and connected to two catheters inserted into the right internal jugular vein until the right atrium. In addition to being of easy insertion and immediate use, this device also allow a high dialysis flux, a low incidence of thrombosis and infection but due to its high cost, it is prevalently reserved for elderly patient or patients with complications due to a depletion of the venous network (Easton *et al.*, 2007). The patient is encouraged to the perform daily cleaning routine by washing the skin around the exit site with disinfectant soap while nursing staff will be in charge of inserting needles under strict aseptic conditions. At the beginning of each dialysis session, the catheters should be washed with an isotonic saline solution using an antithrombotic substance if necessary. At the end of the session, the cannula, port and catheter should be filled with 2.5 c of isotonic saline solution containing 5000 IU of heparin or 3.8% sodium citrate. After removal of the needles, the point of insertion is slightly compressed for approximately 5-10 min to achieve complete hemostasis and finally a light dressing is applied to maintain moderate compression.

**Background:** Intravascular catheters are indispensable in modern medical practice, particularly in Intensive Care (ICU) (Wieners *et al.*, 2009). Although, these catheters provide the necessary vascular access, their use puts patients at risk of local and systemic complications such as local infections at the catheter site, septic thrombophlebitism endocarditis and other metastatic infections (e.g., lung and brain abscesses and osteomyelitis) (Jasinsky and Wurster, 2009). Every year, health care facilities purchase millions of intravascular catheters. The incidence of infections varies considerably depending on the type of catheter, frequency of catheter manipulation and other factors associated with the patient (i.e., pre-existing conditions and degree of illness). Peripheral venous catheters are the most frequently used

devices for vascular access. Although, the incidence of local or systemic infections associated with peripheral venous catheters is usually low, due to the high volume of applications serious complications lead to significant yearly morbidity levels. However, the majority of serious infections associated with vascular catheters are linked to the use of central venous catheters in patients in intensive care (Gorski, 2007).

In intensive care units, the incidence of infection is often higher than that of hospital wards with less acute patients or that of outpatient clinics. Systemic infections may be caused by a prolonged central venous access; the patients may become colonized with organisms acquired in the hospital and the catheters are usually handled several times a day for administration of fluids, medications and blood products. Moreover, some catheters are inserted in emergency situations where it may be impossible to follow proper antiseptic techniques (Herrero *et al.*, 2006).

Many studies have estimated the risk of morbidity and mortality due infection in CVC: each year, in the United States, there are a total of 15 million CVC days (the total number of days of exposure to CVC by all patients in the selected population during the selected time period). If hospitals are evaluated as a whole, rather than systematic infections only, it is estimated that each year, there is a total of 250,000 cases of systematic infections associated with CVC in the United States. In this case, the estimated attributable mortality rates range from 12-25% for each infection. To improve the patient outcome, new strategies to reduce the incidence of infections are urgently needed.

These attempts must be multidisciplinary, involving health care professionals for insertion and management of intravascular catheters. The terminology used to identify different types of catheters is varied because many clinicians and researchers use different characteristics of the catheter as reference terminology. A catheter can be designated by the type of vessel it occupies (e.g., peripheral venous, central venous, arterial) by its expected duration (i.e., temporary to permanent vs short term or long term) by its insertion site (e.g., subclavian, femoral, jugular, peripheral and peripherally inserted central catheter); by its path from skin to blood vessel (i.e., tunneled or not); by its length (long/short) or by specific characteristics such as the presence or absence of a cap, impregnation with heparin, antibiotics or antiseptics. In order to accurately define a particular type of catheter, all of these aspects must be described (Turcotte *et al.*, 2006).

**Epidemiology and microbiology:** From 1980 to present day, the US national surveillance body for CVC (National

Nosocomial Infection Surveillance System, NNIS) has collected data on the incidence and etiology of nosocomial infections, including systemic infections associated with CVC, in approximately 300 member hospitals in the United States (Katneni and Hedayati, 2007). The majority of systemic infections in hospitals are associated with CVC use with substantially higher rates of infections among patients with CVC compared to those with PVC. Infection rates associated with CVC vary considerably depending on the size of the hospital, type of hospital ward and type of CVC. During the period of 1992-2001, NNIS hospitals reported CVC-related intensive care BSI rates ranging from 2.9 (Cardiothoracic Intensive Care Unit) to 11.3 (in a ward with babies weighing <1 kg) BSI per 1000 CVC days (Kawamura *et al.*, 2008). Infection rates are influenced by some patient related parameters, such as severity and type of condition (e.g., third degree burns vs. post-cardiac surgery) and catheter related parameters (e.g., tunneled vs non tunneled or subclavian vs. jugular). Over time, the types of most frequent micro-organisms causing hospital infections have changed.

**Pathogenesis:** The most common cause for infection (Blaivas and Lyon, 2006) in short term peripherally inserted catheters is the migration of micro-organisms from the skin at insertion site with colonization of the catheter tip. In long term catheters, contamination of the catheter junction substantially contributes to intraluminal colonization (Brogden, 2004). Occasionally, catheters may be contaminated via a blood-borne infection from another infection site. Rarely, intravenous administration of contaminated fluids may lead to a local infection.

The most important determinants of pathogenesis in catheter-related infections are:

- Catheter material
- Inherent virulence factors of the infective micro-organism

*In vitro* studies have demonstrated that catheters made of polyethylene are probably less resistant to the adherence of micro-organisms than Teflon, silicone elastomer or polyurethane catheters. Additionally, some materials have surface irregularities which increase the adhesion of some microbial species (e.g., coagulase negative staphylococcus, *Acinetobacter calcoaceticus*, *Pseudomonas aeruginosa*) (Munckhof, 2005). Catheters made of these materials are particularly vulnerable to microbial colonization with subsequent infection. Furthermore, some catheter materials are more

thrombogenic than others, a characteristic that could also predispose to catheter colonization and catheter-related infection (Brannam *et al.*, 2004).

**Prevention strategies for catheter-related infections:** The measures necessary to minimize risk of infection associated with intravascular therapy should aim for a balance between patient safety and cost effectiveness (Amerasekera *et al.*, 2009). With enhanced knowledge, technology and healthcare facilities, control measures and infection prevention should also be enhanced. In order for these efforts to succeed, well organized programs for providing, monitoring and evaluating current health assistance as well as proper training are necessary. It has been shown consistently that the risk of infection declines following standardization of aseptic care procedures and that with insertion and management of intravascular catheters by inexperienced staff may increase the risk of catheter colonization and local infections. It has been unequivocally demonstrated that health care teams specializing in intravenous therapy reduce the incidence of catheter-related infections, complications and associated costs (Onat *et al.*, 2005).

**Catheter insertion site:** The site through which the catheter is inserted influences the subsequent risk of infection and phlebitis. This depends partly on the risk of thrombophlebitis and density of local skin flora. Phlebitis has long been recognized as a risk of infection. In adults, catheter insertion in the lower extremities is associated with a higher risk of infection than insertion in the upper extremities. In addition, the veins of the hand have a lower risk of phlebitis than those of the wrist or the arm (Periard *et al.*, 2008).

**Catheter material:** Teflon and polyurethane catheters have been associated with fewer infectious complications than catheters made of polyvinyl chloride or polyethylene. Steel needles used as an alternative to catheters for peripheral venous access have the same rate of infectious complications as teflon catheters. However, using steel needles frequently results in leakage of intravenous fluid into the subcutaneous tissue, a serious complication if the fluid is potentially corrosive.

**Hand hygiene and aseptic techniques:** For short peripheral catheters, proper hand hygiene before catheter insertion or management, combined with appropriate aseptic technique during catheter manipulation, provides protection against infection. The use of alcohol without water or an antibacterial soap and water with adequate rinsing can achieve proper hand hygiene. Appropriate

aseptic technique does not necessarily require sterile gloves. The CVC, compared with PVC have an increased risk of infection, so the correct level of barrier precautions necessary to prevent infection during CVC insertion must be used. Using maximal sterile barrier precautions (i.e., cap, mask, sterile gown, sterile gloves and a large sterile drape) during CVC insertion significantly reduce the incidence of local infection.

**Skin antiseptics:** In the United States, the most widely used antiseptic for CVC insertion site antiseptics and for arterial catheter management has classically been povidone-iodine. However, in a recent study it was determined that the preparation of central venous and arterial sites with a 2% solution of chlorhexidine gluconate lowered systemic infection rates by 10% compared to povidone-iodine and 70% compared to alcohol. Other preparations of chlorhexidine might not be as effective. About 0.5% tincture of chlorhexidine gluconate is no longer effective in preventing local infection or colonization of the CVC compared with 10% povidone-iodine solution, as demonstrated by a randomized prospective study conducted among adults. However, in a study on infants, 0.5% chlorhexidine preparation reduced peripheral colonization compared to povidone-iodine. This study did not include CVC and had insufficient number of participants to evaluate systemic infection rates. In Canada and Australia, a 1% chlorhexidine tincture is available. There are no published studies comparing this preparation to povidone-iodine (Walker *et al.*, 2009).

**Catheter site dressing:** Transparent semi-permeable polyurethane dressings have become a popular method for dressing catheter insertion sites. Transparent dressings efficiently affix the device, permitting continuous visual inspection of the insertion site as well as allowing the patient to bathe or shower without compromising the dressing and require less frequent changing than standard gauze dressings and plasters; using these dressings reduces management time by staff (Reddy, 2006).

In the biggest controlled study on dressing regimes and peripheral catheters, infectious morbidity associated with the use of transparent dressings was analyzed in approximately 2000 peripheral catheters. The results suggest that colonization rates for catheters with transparent dressings is comparable to those with gauze dressings (5.7 vs. 4.6%, respectively) and that there are no substantial clinical differences in cases with catheter colonization or phlebitis. Furthermore, the results also suggest that transparent dressings can be safely used on

PVCs for the whole duration of the treatment without increasing the risk of thrombophlebitis. Studies on the risk of catheter-related systemic infections comparing groups using transparent dressings with those using gauze dressings were analyzed. The risk of local infection did not differ in adults. The choice of dressing can be a matter of preference. If there is a leakage of blood from the insertion site, gauze dressing may be preferable. In a multicenter study, a chlorhexidine-impregnated sponge placed on a short term arterial catheter site solved the risk of catheter colonization and local infection. The use of this device did not cause adverse systemic effects (Surov *et al.*, 2009).

**Catheter fixation devices:** Fixation devices without sutures may be advantageous compared to those requiring sutures in preventing catheter-related infections. In a study with a limited number of patients and therefore of low statistical relevance, a catheter fixation device without sutures was compared with another one using sutures; a reduction of local infections in patients with the device not requiring sutures was observed.

**Catheters impregnated with antimicrobial/antiseptic agents and cuffs:** Some catheters and cuffs are impregnated with or incorporate, antimicrobial or antiseptic agents. These can reduce the risk of local infection, potentially reducing hospital costs associated with treating such infections, despite the additional cost of purchasing impregnated catheters. To date, all studies on impregnated catheters have been conducted on tri lumen catheters without cuffs in adult patients with a catheterization period of <30 days.

**Chlorhexidine/silver sulfadiazine:** In order to reduce systemic infections, studies have been conducted on catheters incorporating chlorhexidine/silver sulfadiazine only on the outer surface of the lumen (Clevenot *et al.*, 2003). Two studies demonstrated that such catheters reduce the risk of local infection when compared with standard catheters. In summary, the catheterization period varied from 5-11 days. The half-life of antimicrobial activity against *S. epidermidis* was 3 days, *in vitro* for chlorhexidine/silver sulfadiazine coated catheters; this activity diminished with time. The benefits to patients with this kind of catheters were evident in the first 14 days. Currently, a second generation of chlorhexidine coated catheters is available. These catheters are coated on the inner surface as well as on the outer surface of the lumen with the coating of the outer surface containing 3 times more chlorhexidine and an increased release of surface bound antiseptics compared to the first

generation catheters. The outer surface is coated with chlorhexidine combined with silver sulfadiazine while the inner surface is coated with chlorhexidine alone. Preliminary studies indicate that the prolonged anti-infective activity provides a better efficacy in preventing infection. Although, it is a rare occurrence, a Japanese study has reported the possibility of anaphylaxis associated with the use of chlorhexidine/silver sulfadiazine coated catheters. It has not been determined whether patients become colonized or infected by organisms resistant to chlorhexidine/silver sulfadiazine. These catheters are more expensive than standard catheters (Cook, 2007).

**Minocycline/Rifampin:** In a randomized multicenter trial, central venous catheters impregnated on both the outer and the inner surface with minocycline/rifampin were associated with lower local infection rates than first generation catheters impregnated with chlorhexidine/silver sulfadiazine (Lin *et al.*, 2005).

The benefits were visible after a 6th day catheterization period. None of the catheters was evaluated after 30 days. No minocycline/rifampin resistant organisms were observed. However, *in vitro* data suggest that the use of these catheters could increase the incidence of resistance to minocycline and rifampin among pathogens, in particular staphylococci. The half-life of antimicrobial activity against *S. epidermidis* of minocycline/rifampin coated catheters was 25 days, compared to 3 days of first generation catheters coated with chlorhexidine/silver sulfadiazine, *in vitro* (Subha *et al.*, 2005).

**Platinum/silver:** Metal ions have a broad spectrum of antimicrobial activities and are starting to be used to prevent local infections in catheters and cuffs. Platinum/silver coated catheters are available in Europe and have recently been approved by the FDA for use in the United States. Although, these catheters are being marketed for their antimicrobial properties to date no published studies exist to support these claims.

**Silver ion-impregnated cuffs:** Ionic silver has been used in subcutaneous collagen cuffs attached to CVCs. Ionic silver provides antimicrobial action and the cuff creates a mechanical barrier against microorganisms migrating along the outer surface of the catheter. Studies on catheters left in place for >20 days report no reduction in local infection rates with cuffs. Two other studies on short term catheters were not able to demonstrate their effectiveness due to the low number of local infections observed.

**Antibiotic/antiseptic ointment:** In order to reduce the incidence of catheter-related infections, application of povidone-iodine ointment to hemodialysis catheter insertion sites was studied as a preventive measure. A randomized study on 129 hemodialysis catheters reported a reduction in insertion site infection, catheter tip colonization and systemic infection rates with a routine use of povidone-iodine ointment on insertion sites, compared to the absence of such treatment (Scales, 2008). Many studies have evaluated the efficacy of mupirocin ointment applied to central venous catheter insertion sites in reducing local infections. Although, mupirocin reduced the risk of local infection, the use of mupirocin ointment was associated with resistance to mupirocin and could compromise the integrity of polyurethane catheters.

**Anticoagulants:** Anticoagulant solutions are widely used to prevent thrombosis in the catheter. Since thrombi and fibrin deposits in the catheter could lead to microbial colonization in intravascular catheters, the use of anticoagulants might play a role in preventing local infections. In a study that assessed the benefits of prophylaxis with heparin in patients with short term catheters, the risk of CVC related thrombosis was reduced with the use of heparin. However, no significant difference was reported in local infection rates. Since the majority of heparin solutions contain preservatives with antimicrobial properties, it is unclear whether the reduction in local infection rates is due to a reduced thrombus formation, the preservatives or both. The majority of central venous, umbilical and pulmonary artery catheters are heparinised. Most contain heparin and benzalkonium chloride, providing antimicrobial action with antithrombotic effects. Warfarin has also been evaluated as a means of reducing local infection rates by its anticoagulant properties. In patients with a permanent CVC, low doses of Warfarin (1 mg day<sup>-1</sup>) decreased the incidence of catheter-related thrombi. To date, there have been no studies reporting reduction of local infection rates with Warfarin.

**Midline catheters:** The use of midline catheters has been shown to be associated with lower phlebitis rates than short peripheral catheters and with lower infection rates than CVCs. In a prospective study on 140 midline catheters, the mean BSI rate was 0.8 per 1000 catheter days. No specific risk factors, including catheterization duration were reported. In this study, mean catheterization period was 7 days but it ranged up to 49 days. Although, the results of this study suggest that midline catheters can be changed only when there is a specific indication, the benefits of a change routine as a midline catheter-related CRBSI prevention strategy have not been assessed by randomized trial to date.



## MATERIALS AND METHODS

The researchers analyzed 460 urgent/emergency care patients (Fig. 1); all patients underwent peripheral catheterization with 126 also requiring central venous catheterization and 20 requiring venous access port insertion. Nurses actively participated in the preparation for CVC insertion and in the subsequent catheter management consisting of monitoring the catheter function, being aware of the implications, possible complications and correct CVC management techniques. Nurse coordinators and medical directors played an important role in optimizing human resources, materials and time to ensure an effective and efficient management of central venous access facilities.

The decision to employ such devices, even in critical cases (oncological, oncohematological or immunocompromised subjects) was taken in consideration of the potential risk factors of catheterization, together with eventual immediate, short and long-term complications. To achieve quality results, scheduled CVC insertion was recommended, unless in emergency conditions because only a proper organization could guarantee patient safety as well as allowing staff to respect necessary operating times and scientific knowhow.

The planning phase was carried out by a multidisciplinary team formed by the ward doctor and nurse caring for the patient, the physician in charge for inserting the catheter as well as the patient him/herself. The most suitable device was selected and personalized based on the therapeutic needs of each patient. Patient was informed by several professionals each with their specific, well defined role. The doctor treating the patient provided information regarding the therapeutic program consisting of one or more of the following approaches: antitubercular chemotherapy, parenteral nutrition, blood/blood product transfusion, pain therapy and palliative therapy. Insertion technique and related

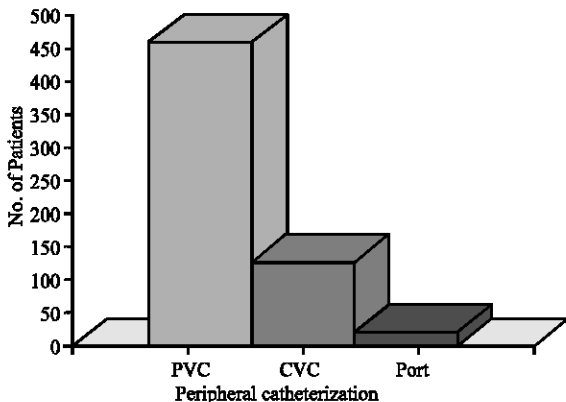


Fig. 1: Examined cases

immediate risks were discussed with the physician who would later insert the device. The ward nurse played a fundamental role in informing and educating the patient to actively involve him/her in the management of the catheter in particular with long term catheterization or home care patients. For the present study the researchers performed:

- Data collection on the habits of the patient (e.g., if the patient sleeps on his/her right side, it is preferable to place the CVC on the left) when choosing a suitable catheterization site, proper functioning of the catheter must be ensured while maintaining the best possible quality of life
- Detection of eventual allergies to local anesthetics (e.g., lidocaine which is often used during catheter insertion), skin antiseptics or patches used in the management of insertion site dressings
- Identification of a leader relative/family member as a reference point for the domiciliary treatment phase: this is important not only to the aspects strictly related to the CVC but also for the entire treatment program.
- Making sure that the patient is able to reach a hospital or emergency unit in case of acute CVC related complications

A signed patient consent form was obtained by the doctor. These consent forms were voluntary and could only be signed by a mentally capable patient. The formal acquisition of informed consent could not be delegated to nursing staff, although the latter were allowed to assist and integrate the physician by sharing their experience in order to help patients fully understand and assent to the treatment. The consent collection phase was rigorously characterized by active dialogue between the patient and care staff, psychological support, explanation of benefits and risks of the chosen treatment. The legal references related to this process are:

- Article 32 of the Italian Constitution
- Article 33 D.L. 833 del 23/12/1978
- Articles 32, 33, 34, 35, of the 1998 Medical Deontology Code (Italy)
- Articles 4.2, 4.3, 4.5, 4/11 of the 1999 Deontology Code for Nurses (Italy)

### Patient preparation

**Trichotomy:** Although, there are plenty of indications that hair removal before surgical procedures is not necessary for preventing infection, it would be difficult to apply this in practice. In fact, considering different

aspects of catheter site management, the absence of hair facilitates the use of adhesive dressings. Also, in patients undergoing antineoplastic chemotherapy and/or radiotherapy, alopecia is almost always observed in a male patient, the loss of hair on the back would create a less hygienic environment in the insertion area. Therefore, in male patients and when body hair was present at the catheter insertion site, hair removal was carried out. Shaving with a razor blade can promote the development of infections through multiplication of bacteria in eventual microabrasions. There is ample evidence in the literature that a preparatory shower using an antiseptic soap reduces staph infections colonizing the skin compared to shower using soap only thus, it is recommended to use this method in preparation for central venous access. The patients were instructed to wash with a chlorhexidine based antiseptic preceding the insertion of the device, wearing clean undergarments afterward; for transfer to the operating room, a disposable gown was used and the patient was requested not to wear any kind of jewelry or other accessories.

**Medical assessment:** Prior to the insertion of the CVC, the patient was visited (when possible) by a physician to exclude:

- History of lung disease, morphological abnormalities of the chest and neck (i.e., presence of lymphonodal groups)
- Changes in blood coagulation and/or thrombocytopenia
- Presence of infective risk

All of these conditions could increase short term catheter-related risks, particularly if inserted in a thoracic vein. Nurses verified that the patient's medical records contained recent tests including:

- Chest radiography
- ECG
- Routine blood tests: blood count, platelet count, PT, PTT
- Blood group for eventual emergency transfusion
- Other possible preliminary tests (echo-color Doppler assessment of the blood vessels)

**CVC insertion in operating room:** To date, there have been no studies regarding the choice of the ideal environment for venous access insertion. It is customary to use an operating room because it is considered a cleaner environment compared to a normal ward. In reality, the use of any other space is acceptable as long as it is dedicated and prepared for these procedures and not used for performing contaminating procedures.

**Characteristics of the insertion environment:** The environment dedicated to CVA insertion must meet the following requirements:

- Room with good lighting, where it is possible to ensure the privacy of the patient
- Only operators must be allowed entry in order to reduce air movement and provide an ideal microclimate
- Availability of equipment for eventual emergency resuscitation procedures in case of serious complications

Furthermore, if required by the operator:

- Possibility to perform X-rays during insertion maneuvers
- Possibility to perform an ultrasound guided insertion
- ECG monitoring of the patient and the possibility of ECG-guided CVC tip positioning

**Materials used for CVC insertion:**

- CVC of appropriate size (14 gauge x 20 cm) sealed in special sterile kit containing everything needed for the cannulation
- Local anesthetic (Lidocaine 2%)
- 5 mL syringe with a fine needle
- Ampoule containing saline solution
- Hair removal supplies (if necessary)
- Antiseptic 10% alcoholic povidone-iodine solution
- Sterile drape set (4)
- Sterile gown + drape-towel set
- Surgical mask
- Surgical gloves
- Headgear
- CVC set
- Set of surgical instruments with at least: 1 klemmer forceps, 1 needle tray, 1 pair of scissors
- Sterile gauze set
- 2/0 non-absorbable sutures for skin with pre-mounted needle
- Infusion solution with tube
- Connectors and three-way taps
- 10x8 cm transparent sterile dressing (if not available, sterile gauze and anafix were used)
- Special waste container

**Preparation:** The patient was monitored for: heart rate, blood pressure, oxygen saturation. CVC insertion was performed at the bedside.

- Trichotomy was performed in the supra infraclavicular region, neck, chest (above the nipple line) and/or inguinal region (in the case of femoral catheterization)
- Betadine saturated gauze was placed on insertion site for a minimum time of 10 min. If CVC insertion was performed under emergency conditions, this procedure was omitted and only the pre-insertion disinfection was carried out. A 500 cc container with saline solution is prepared and positioned ready for use
- The patient was positioned: without pillow, head rotated to the opposite side from the insertion site, rigorously in a supine position in a slight Trendelenburg tilt (20-30 degrees) as requested by the physician (for subclavian CVC) with a pad or a sheet roll folded in between of the shoulders to hyperextend the neck and elevate the clavicle, both arms by the sides. The interscapular pad technique is recommended especially in patients who have a short neck or are obese
- For subclavian vein cannulation, the ipsilateral arm was rotated externally and moderate traction was applied while the head was held in the opposite direction from the insertion site by the nurse or the patient him/herself (if collaborating). It is important to maintain the correct position throughout the insertion procedure as it reduces the risk of gas embolism and maintains, in the case of jugular catheterization, a higher venous pressure.
- Inserted the needle, while aspirating and as soon as blood was drawn, the Seldinger was inserted through the plunger of the syringe that has an access hole
- Inserting it for approximately 20-25 cm
- Removed the syringe with caution in order to avoid guide wire dislodgement and proceeded with expansion of the surrounding area with a dilator
- The catheter was then inserted on the Seldinger, which was subsequently removed once the CVC was in its final position
- Connected the infusion line to the three-way tap

After inserting the CVC, the physician completed the procedure by:

- Securing the catheter with two sutures
- Disinfecting the site

The dressing was then applied by a nurse. It is recommended to use a hypoallergenic, breathable (for oxygen/vapour exchange), transparent (allowing visual inspection of the catheter site) dressing that is also impervious to liquids, bacteria and viruses. After CVC insertion, a chest radiography was performed. Throughout the procedure, the nurse was responsible for:

- Monitoring the heart and respiratory rates of the patient
- Verifying and monitoring the position of the patient

**Preparation of sterile field:** Sterile field was prepared by two operators:

- The first must have sterile hands and has the task of materially preparing the field
- The second operator assists the first one, handing him/her the sterile kits

Operators were either nurses or physicians.

**Insertion phase:** The physician carried out the following procedures:

- Extensively disinfected the skin with Betadine solution in a rotating fashion and subsequently cleaned the immediate insertion site with 70° alcohol
- Arranged two sterile drapes on the patient to delimit the insertion area
- Performed local anesthesia of the skin and subcutaneous tissue laterally, just below the middle of the clavicle
- Assembled the needle and 10 mL syringe contained in the kit and aspirated 2-3 mL of saline solution
- Pricked the skin in the anesthetized spot

## **RESULTS AND DISCUSSION**

After analysis, the researchers found remarkable similarities between the results and available literature. In an analysis of 460 patients with CVC and PVC, the researchers report 4 cases of pneumothorax, 6 hematomas, 11 cases of phlebitis, 4 cases of arterial puncture, 1 case of deep vein thrombosis, 6 cases of skin infection, 7 cases of ruptured blood vessel, 5 cases of occlusion of the vessel, 7 cases of catheter dislocation, 2 cases of arrhythmia and 2 cases of decubitus ulcers from port installation (Fig. 2).

Vascular catheterization has become a frequent procedure in health care units; the benefits of such procedure, as discussed before are many providing the guidelines are followed carefully. Proper use of the catheter allows for improved benefits for the patient, simplifying the infusion therapy procedures carried out by nursing staff and overall translates into better health care. It has been known for many years that a perfect balance of health care roles (in this case between physicians and nurses), allows for a harmonious and successful patient care and that educating health care personnel in the

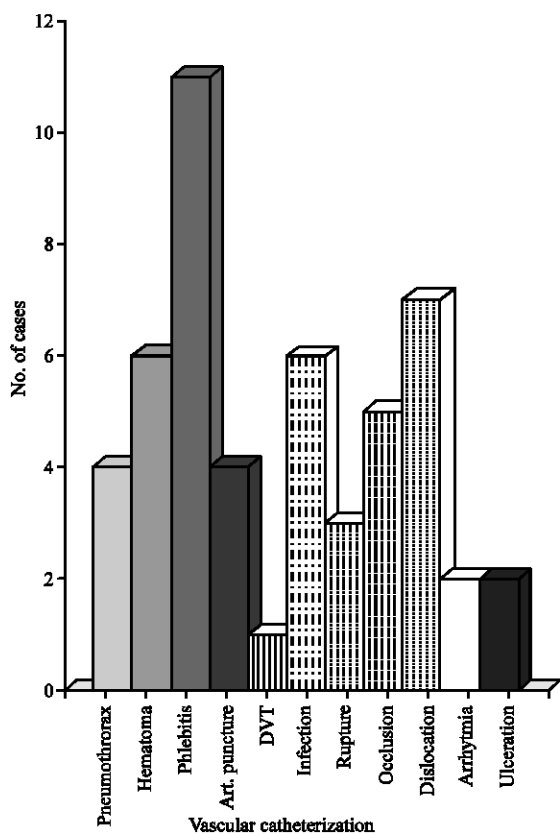


Fig. 2: Complications: referred to a total of 460 patients with CVC and PVC

delicate field of vascular catheterization relative to the administration of fluids and in the vital field of patient monitoring is of great importance.

### REFERENCES

Amerasekera, S., M. Jones, R. Patel and J. Cleasby, 2009. Imaging of the complications of peripherally inserted central venous catheters. *Clin. Radiol.*, 64: 832-840.

Blaivas, M. and M. Lyon, 2006. The effect of ultrasound guidance on the perceived difficulty of emergency nurse-obtained peripheral IV access. *J. Emerg. Med.*, 31: 407-410.

Brannam, L., M. Blaivas, M. Lyon and M. Flake, 2004. Emergency nurses utilization of ultrasound guidance for placement of peripheral intravenous lines in difficult-access patients. *Acad. Emerg. Med.*, 11: 1361-1363.

Brogden, J., 2004. Current practice in administration of parenteral nutrition: Venous access. *Br. J. Nurs.*, 13: 1068-1073.

Clevenot, D., S. Robert, B. Debaene and O. Mimoz, 2003. Critical review of the literature concerning the comparative use of two antiseptic solutions before intravascular or epidural catheterization. *Ann. Fr. Anesth. Reanim.*, 22: 787-797.

Cook, S., 2007. Choosing the right intravenous catheter. *Home Health Nurse*, 25: 523-531.

Del Pozo, L., A. Serrera, A. Martinez-Cuesta, J. Leiva, J. Penades and I. Lasa, 2006. Biofilm related infections: Is there a place for conservative treatment of port-related bloodstream infections. *Int. J. Artificial Organs.*, 29: 379-386.

Easton, B., A. Graber, J. Monnahan and J. Hughes, 2007. Defining the scope of implied consent in the emergency department. *Am. J. Bioeth.*, 7: 35-38.

Fujita, T. and N. Namiki, 2008. Replacement of peripheral intravenous catheters. *J. Clin. Nurs.*, 17: 2509-2510.

Gorski, A., 2007. Infusion nursing standards of practice. *J. Infusion Nurs.*, 30: 151-152.

Gorski, A., 2009. The peripheral intravenous catheter: An appropriate yet often overlooked choice for venous access. *Home Health Nurse.*, 27: 130-132.

Herrero, G.S., M.T.P. de Alborno, N.B. Vidal, S.E. Alvarez, V.J. Perez, S.J.R. Garrido and A.M. Garcia, 2006. Use and abuse of intravenous catheters in conventional hospital wards. *Anales Medicina Interna*, 23: 475-477.

Hertzog, R. and N. Waybill, 2008. Complications and controversies associated with peripherally inserted central catheters. *J. Infusion Nurs.*, 31: 159-163.

Jasinsky, M. and J. Wurster, 2009. Occlusion reduction and heparin elimination trial using an antireflux device on peripheral and central venous catheters. *J. Infusion Nurs.* 32: 33-39.

Katneni, R. and S. Hedayati, 2007. Central venous catheter-related bacteremia in chronic hemodialysis patients: Epidemiology and evidence-based management. *Nat. Clin. Pract. Nephrol.*, 3: 256-266.

Kawamura, J., S. Nagayama, A. Nomura, A. Itami and H. Okabe *et al.*, 2008. Long-term outcomes of peripheral arm ports implanted in patients with colorectal cancer. *Int. J. Clin. Oncol.*, 13: 349-354.

Lapostolle, F., J. Catoire, B. Garrigue, V. Monmarteau and T. Houssaye *et al.*, 2007. Prospective evaluation of peripheral venous access difficulty in emergency care. *Intensive Care Med.*, 33: 1452-1457.

Lin, W., A. Kacker, V. Anand and H. Levine, 2005. Catheter- and antibiotic-related complications of ambulatory intravenous antibiotic therapy for chronic refractory rhinosinusitis. *Am. J. Rhinol.*, 19: 365-369.

- Milagry, F., A. Raian and S. Taylor, 2008. The role of the registered nurse in the insertion of external jugular peripherally inserted central catheters and external jugular peripheral intravenous catheters. *J. Infusion Nurs.* 31: 226-227.
- Munckhof, J., 2005. Intravenous catheter-associated *Staphylococcus aureus* bacteraemia: A common problem that can be prevented. *Intern. Med. J.*, 35: 315-318.
- Onat, D., J. Stathopoulos, A. Rose, K. Newman, R. Sciacca, P. Jorde and P. Colombo, 2005. Reliability of nesiritide infusion via non-primed tubing and heparin-coated catheters. *Ann. Pharmacother.*, 39: 1617-1620.
- Periard, D., P. Monney, G. Waeber, C. Zurkinden and L. Mazzolai *et al.*, 2008. Randomized controlled trial of peripherally inserted central catheters vs. peripheral catheters for middle duration in-hospital intravenous therapy. *J. Thromb. Haemost.*, 6: 1281-1288.
- Reddy, K., 2006. Clinical utility of novel agents in the treatment of central venous catheter occlusion. *Support Cancer Ther.*, 3: 135-139.
- Scales, K., 2008. Intravenous therapy: A guide to good practice. *Br. J. Nurs.*, 17: 4-12.
- Subha, D., R. Lavi and R. Macaden, 2005. Infections related to vascular catheters in a pediatric intensive care unit. *Indian Pediatr.*, 42: 667-672.
- Surov, A., A. Wienke, M. Carter, D. Stoeversandt and C. Behrmann *et al.*, 2009. Intravascular embolization of venous catheter-causes, clinical signs and management: A systematic review. *J. Parenter. Enteral. Nutr.*, 33: 677-685.
- Turcotte, S., S. Dubé and G. Beauchamp, 2006. Peripherally inserted central venous catheters are not superior to central venous catheters in the acute care of surgical patients on the ward. *World J. Surg.*, 30: 1605-1619.
- Walker, M., C. Bowler and P. Bejon, 2009. Risk factors for recurrence after *Staphylococcus aureus* bacteraemia. A retrospective matched case-control study. *J. Infect.*, 58: 411-416.
- Wieners, G., U. Redlich, O. Dudeck, K. Schütte, J. Ricke and M. Pech, 2009. First experiences with intravenous port systems authorized for high pressure injection of contrast agent in multiphasic computed tomography. *Rofo*, 181: 664-668.