

Bovine Liver Telangiectasis

Doustar Yousef and Mohajeri Daryoush
Department of Pathobiology, Faculty of Veterinary Medicine,
Islamic Azad University, Tabriz Branch, Tabriz, Iran

Abstract: Bovine liver telangiectasis is one of the most common liver lesions found in cattle throughout the world. Liver samples from 50 bovines with telangiectasis were examined by light microscopy. They were characterized grossly by single or multiple red-brown foci, generally 1-5 mm in diameter and occasionally larger. They were located on the parietal surface of the lobus dexter or rarely scattered throughout the organ. Microscopically, irregular and cystic dilation of hepatic sinusoids in all over the liver observed; these cystic cavities were full of red blood cells and in some cases fibrins with neutrophil in these cavities were distinguished. In finding of electronic microscope; marked dilation of diss spaces with red blood cells and collagen and moderate sediment of fibrin were observed. This study is the 1st report on liver telangiectasis in cattle in East Azerbaijan province.

Key words: Bovine, liver, telangiectasis, fibrins, lobus dexter, Iran

INTRODUCTION

Bovine liver telangiectasis, a focal dilation and congestion of a group of hepatic sinusoids is the most common liver lesion in cattle from different countries of the world (Andersen, 1955b; Jensen *et al.*, 1947; Roberts, 1982; Wettimuny and Aturaliya, 1975; Ziaii-Nia *et al.*, 1981). In fact, telangiectasis is a frequently encountered lesion that leads to economic losses due to the condemnation of the affected parts of the liver in cattle (Andersen, 1955b, c; Julian and Doewe, 1947; Julian, 1950). This lesion causes direct economic losses due to liver condemnation by sanitary inspectors and in severe cases due to impairment of liver function, indirect losses related to a decrease in milk yield or meat production (Reid *et al.*, 1977). The purpose of this research was to pathological study on bovine liver telangiectasis. This is the 1st study on this subject in East Azerbaijan province area. This report deals with the incidence and gross and microscopic pathology of telangiectasis of beef cattle slaughtered in Tabriz slaughterhouse.

MATERIALS AND METHODS

Liver samples from 50 bovines with hepatic telangiectasis were taken between 20-35 min after death at a local slaughterhouse, fixed by immersion in cold 3% glutaraldehyde in 0.1 M phosphate buffer, post-fixed in 1% osmium tetroxide, dehydrated in alcohol, embedded in PolyBed 812 (Polysciences Inc., Warrington, Penn., USA), cut, stained with lead citrate and uranyl acetate and

observed at the light and electron microscope. Also in this study from specific method for staining were used. Of course, all processing of this study after taken the livers from Tabriz Slaughterhouse in Laboratory of Pathology in Veterinary Faculty of Islamic Azad University, Tabriz Branch was done.

RESULTS

The findings of present study consist of microscopic. From macroscopic study of hepatic telangiectasis, various numbers of reddish brown depressed spots in surfaces of liver were observed. Most of them ranged from 1-5 mm in diameter while a few reached up to 1 cm. Figure 1 shows the macroscopic photograph of hepatic telangiectasis

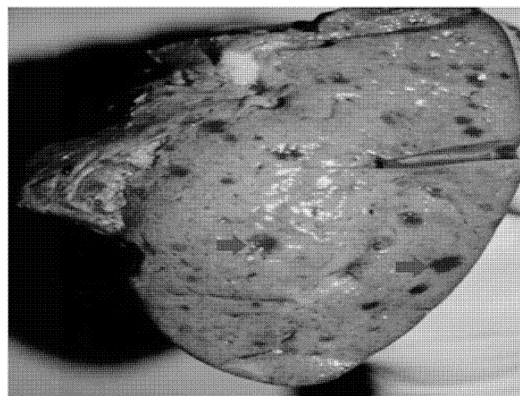


Fig. 1: Macroscopic photograph of hepatic telangiectasis in cattle

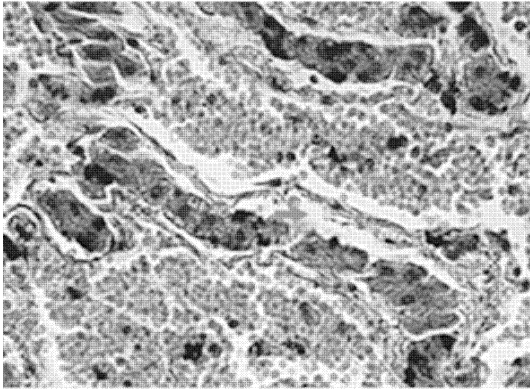


Fig. 2: Microscopic appearance of cattle liver, arrow shows the dilated space of sinusoid and disse, also rupture of sinusoidal endothelium with erythrocyte and neutrophil infiltrations (H and E, x400)

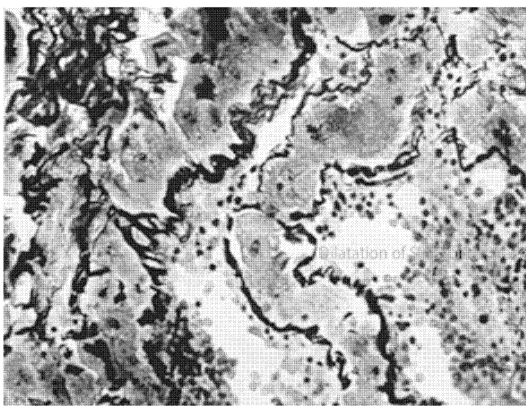


Fig. 3: Microscopic photograph of hepatic telangiectasis in cattle, arrow shows increases thickness of sinusoidal wall (GM, x400)

in cattle. Microscopically findings were characterized by dilatation of the space of disse by glycogen extruded from hepatocytes with endothelial rupture and subsequent erosion of the hepatocytes. Also, other lesions consist of dilated sinusoids as irregular cavernous vascular spaces and in some areas atrophic hepatocyte. Dilated sinusoids were filled with erythrocytes and rarely mononuclear cells, neutrophil leucocytes, desquamated hepatocytes, some endothelial cells and plasma. This finding with hemotoxylin and eosin staining were distinguished. Figure 2 shows the lesions with hemotoxylin and eosin staining.

By gomeri methamine silver staining increase the sinusoidal base membrane and tortuous pattern of reticulin fibers in perisinusoidal region were observed. The telangiectatic regions were separated from connective capsule by new formed collagen (Fig. 3).

DISCUSSION

Hepatic telangiectasis has been reported in many countries such as the USA, France, Germany, Italy and Argentina (Jensen *et al.*, 1947; Kreuzer *et al.*, 1985; Morales *et al.*, 1978). The basic lesion of liver telangiectasis consists in a focal dilation and congestion of the hepatic sinusoids. Its etiology is unknown however, in cattle. It has been associated to several factors such as vascular inflammation of the portal system (Andersen, 1955a), focal hepatic necrosis (Getty, 1946) and toxic plants. In humans, it has been associated to long term therapy with anabolic steroids and in laboratory animals it has experimentally been produced with B1 aflatoxin (Gedek and Hofmann, 1970), vinyl chloride (Winell *et al.*, 1976), Lasiocarpine (Jensen *et al.*, 1982), experimental inoculations with murine leucemia 9H virus (Bergs and Scotti, 1967) or in mice transplanted with granulosa cell tumors or interstitial cell tumors (Wolstenholme and Gardner, 1950). It is recorded that telangiectatic lesions tend to develop either in the top parietal portion of the liver and at the periphery of the liver lobules or in any area of the organ (Andersen, 1955b; Julian and Doewe, 1947; Julian, 1950; Morales *et al.*, 1978; Scanlan and Berg, 1983). In this study, these lesions were generally located at any site on the parietal surface of the lobus dexter. Gross and microscopic lesions of telangiectasis were similar in all respects to those previously described by Andersen and Hart (1952), Andersen (1955c), Getty (1946) and Robinson *et al.* (1951). The pathogenesis of bovine liver telangiectasis is still unknown and several theories have been proposed. Jensen *et al.* (1982) have proposed that telangiectasis may be produced by occlusion of sinusoids and necrosis of hepatocytes as a consequence of embolism caused by ulcerative lesions of the Gastrointestinal tract. They have demonstrated the presence of venopathies associated with liver telangiectasis in animals with spontaneous lesions or experimentally inoculated with hemophilus somnus and concluded that the ischemia of hepatocytes was the initial cause of the lesion (Jensen *et al.*, 1982). Getty (1946) has proposed that the primary lesion of bovine liver telangiectasis is an inflammatory focus of hepatic necrosis.

Andersen and Hart (1952) proposed that hepatic telangiectasis is due to glycogen accumulation in the sub endothelial region of the sinusoid which distort and destroy the endothelium allowing the blood to enter the space of disse, eroding the hepatocytes. Foschi has pointed out that liver compression by tympany or pregnancy can cause vascular compression and telangiectasis.

CONCLUSION

In this study, although most of the telangiectatic lesions were located on the parietal surface of the liver. This study is the 1st report on liver telangiectasis in cattle in East Azerbaijan province.

ACKNOWLEDGEMENT

Researchers wish to thank the Vice Chancellor's office for Research Affairs of the Tabriz Branch, Islamic Azad University, Tabriz, Iran.

REFERENCES

- Andersen, A.C. and G.H. Hart, 1952. Histochemical methods in the study of telangiectasis. Am. J. Vet. Res., 13: 359-365.
- Andersen, A.C., 1955. The pathogenesis of telangiectasis in the bovine liver II. histopathological and microbiological studies. Am. J. Vet. Res., 16: 217-236.
- Andersen, A.C., 1955. The pathogenesis of telangiectasis in the bovine liver IV. discussion and summary. Am. J. Vet. Res., 16: 240-245.
- Andersen, A.C., 1955. The pathogenesis of telangiectasis in the bovine liver. I. The incidence of telangiectasis. Am. J. Vet. Res., 16: 27-34.
- Bergs, V.V. and T.M. Scotti, 1967. Virus-induced peliosis hepatis in rats. Science, 158: 377-378.
- Gedek, B. and H. Hofmann, 1970. Animal experiments on the hepatotoxic effect of mycotoxins. 2. Chronic changes in the guinea pig. Zentralbl. Vet., 17: 667-676.
- Getty, R., 1946. The histopathology of a focal hepatitis and of its termination (sawdust and telang liver) in cattle. Am. J. Vet. Res., 7: 437-449.
- Jensen, R., L.W. Johnson, L.H. Lauerman, J.O. Tucker and B.L. Swift *et al.*, 1982. Ischemia: A cause of hepatic telangiectasis in cattle. Am. J. Vet. Res., 43: 1436-1439.
- Jensen, R., P.R. Frey, F. Cross and W.E. Connell, 1947. Telangiectasis, sawdust and abscesses in the livers of beef cattle. J. Am. Vet. Med. Assoc., 110: 256-261.
- Julian, L.M. and L.B. Doewe, 1947. Studies on the subgross anatomy of the bovine liver. I. The distribution of the blood vessels and bile ducts as revealed by the vinylite-corrosion technique. Am. J. Vet. Res., 10: 331-335.
- Julian, L.M., 1950. Studies on the subgross anatomy of the bovine liver II. The pathology of telangiectasis as demonstrated by the vinylite- corrosion technique. Am. J. Vet. Res., 11: 166-172.
- Kreuzer, W., A. Rosopula, P. Petry and D. Schunemann, 1985. Chromium content of various edible tissues (muscle and organ) of slaughter cows. Fleischwirtschaft, 65: 1255-1261.
- Morales, C.R., J.C. Sampietro, L.A. Pereyra, H.A. Domitrovic and J.R. Paez-Barrio, 1978. Telangiectasia in the Liver of Cattle. Index Vet., 046- 00000.
- Reid, I.M., R.D. Harrison and R.A. Collins, 1977. Fasting and refeeding in the lactating cow. 2. The recovery of liver cell structure and function following a six-day fast. J. Comp. Pathol., 87: 253-265.
- Roberts, J.L., 1982. The prevalence and economic significance of liver disorders and contamination in grain-fed and grass-fed cattle. Aust. Vet. J., 59: 129-132.
- Robinson, T.J., D.E. Jasper and H.R. Guilbert, 1951. The isolation of *Spherophorus necrophorus* from the rumen together with some feed lot data on abscess and telangiectasis. J. Anim. Sci., 10: 733-741.
- Scanlan, C.M. and J.N. Berg, 1983. Experimental hepatic necrobacillosis infection in cattle. Cornell Vet., 73: 117-124.
- Wettimuny, S.G. and D.S. Aturaliya, 1975. Abattoirstudy of liver diseases of cattle. Ceylon Vet. J., 23: 54-57.
- Winell, M., B. Holmberg and T. Kronevi, 1976. Biological effects of vinyl chloride: An experimental study. Environ. Health Perspect., 17: 211-216.
- Wolstenholme, J.T. and W.U. Gardner, 1950. Sinusoidal dilatation occurring in livers of mice with a transplanted testicular tumor. Proc. Soc. Exp. Biol. Med., 74: 659-659.
- Ziaii-Nia, H., B. Zakarian and L. Nowrouzian, 1981. An abattoir survey on telangiectasis of cattle and its economical loss. J. Vet., 36: 67-84.