

## Comparative Survey in Automazied Tool of a Cephalometry Images for Orthodontist Application

<sup>1</sup>N. Shanmuga Vadivu and <sup>2</sup>K. Sankarananarayan

<sup>1</sup>Department of E.C.E, V.L.B. Jannakiammal College of Engineering and Technology,  
42 Coimbatore, India

<sup>2</sup>Easa College of Engineering and Technology, 105 Coimbatore, India

**Abstract:** Cephalometry is an important diagnostic tool for orthodontist and craniomaxillo facial surgery. Location of landmark point assist to analyze the lateral cephalogram. Automatic location of landmark point in cephalogram may improve the quality of treatment plan and also time consumption. This study discusses different methods involved in the detection of landmark points in lateral cephalometry.

**Key words:** Cephalometry, landmark points, unilateral cleft lip, craniomaxillo, orthodontist, diagnostic tool

### INTRODUCTION

Cephalograms are clinically useful image data for diagnosis and treatment in orthodontists. The analysis of cephalometric lateral skull X-rays is critically dependent on the accurate location of carefully defined anatomical and constructed landmarks. Errors in landmark identification both systematic and random are a significant source so that the methodology used to identify and record landmarks must be meticulous.

Cephalometrics is the interpretation of lateral skull radiographs taken under standardized conditions (Singh, 2007). The patient is placed in a cephalostat. The patient's head is made oriented at 90° to the X-ray beam at a distance of 5 ft. from the tube. The film is placed 15" from the head. This is a standard under which all cephalometric radiographs are taken worldwide. It ensures that radiographs taken at different centers are directly comparable. The traced and various standard landmarks, lines and angles are measured and recorded. This allows comparison with normal values for a population and assessment of growth and/or effects of treatment. Three techniques are commonly used to identify and record landmarks in cephalometric studies (Turner and Weerakone, 2001). These are:

- Overlay tracing of the lateral skull radiograph on an X-ray viewer followed by direct measurement of cephalometric lines and angles on the tracing paper using a ruler and protractor
- Overlay tracing of the radiograph to identify anatomical and constructed points followed by transfer of the tracing to a digitizer linked to a computer

- Direct digitization of the lateral skull X-ray using a digitizer linked to a computer

The soft tissue can be seen in the outline of the face as well as the tongue and pharynx. All the hard tissue references points should be clearly visible (Fig. 1). List of some cephalometric points (Fig. 2):

- S (Sella): Mid point of sella turcica
- N (Nasion): Most anterior point on fronto-nasal suture
- Or (Orbitale): Most inferior anterior point on margin of orbit
- Po (Porion): Upper most point on bony external auditory meatus
- ANS: Anterior Nasal Spine
- PNS: Posterior Nasal Spine

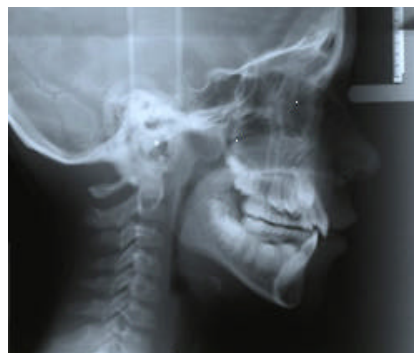

Fig. 1: Cephalometric radiograph

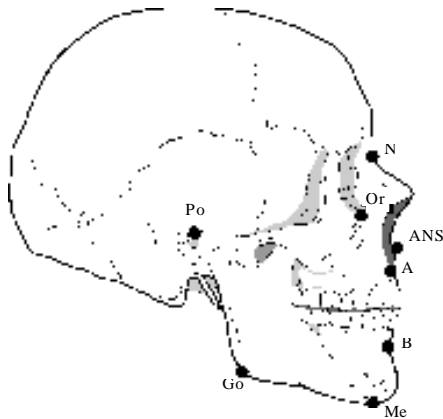


Fig. 2: Key points in cephalography

- Go (Gonion): Most posterior inferior point on angle of mandible
- Me Menton: Lower most point on the mandibular symphysis
- A point: Position of deepest concavity on anterior profile of maxilla
- B point: Position of deepest concavity on anterior profile of mandibular symphysis

List of lines/planes in cephalogram are given as:

- Frankfort plane [Po-Or]: Equivalent to the true horizontal when patient is standing upright
- Maxillary plane [PNS-ANS]: Gives inclination of maxilla relative to other lines/planes
- Mandibular plan [Go-Me]: Gives inclination of mandible relative to other lines/planes

The angle MMPA-Maxilla to Mandibular Planes Angle (Maxillary plane to mandibular plane). Gives an inclination of the maxilla relative to the mandible, this in turn indicates the relative proportions of face height and acts as an indicator for future growth direction:

- S-N line indicates orientation of anterior cranial base
- N-A indicates relative position of maxilla the cranial base
- N-B indicates relative position of maxilla the cranial base

The angles SNA, SNB and ANB indicates relative positions of maxilla/mandible to each other and to the cranial base. Long axis of upper central incisor/lower central incisor (root apex to incisal edge) allows measurement of the angulations of incisors to maxilla/mandibular planes. The above mentioned are some important landmark points and planes for treatment planning and for surgery.

## VARIOUS METHODS TO FIND LANDMARK POINTS

**Shape and local appearance:** In craniofacial cone beam CT images, statistical model was obtained with the knowledge from Training data. Local appearance model captures the local intensity pattern around each anatomical landmark in the image. The shape model contains a local and a global component. With the use of image n-SIFT image descriptor, projection images, different optimizer and the combination of the local shape model with a global shape model, landmark points are identified. But improvement can be made by using other local image descriptors. The combination of the local and the global shape model and the manual definition of the edges between the anatomical landmarks are somehow arbitrary. This could be improved by using a more unified approach (Keustermans *et al.*, 2010).

**Wavelet neurons matching:** In a cephalogram analysis, weighted window for wavelet neurons matching was employed. First, templates were generated with the help of orthodontists. Steepest descent method is involved in learning process. Next to find wavelet matching from that similarity between testing image and template was listed. From that list, maximum value measures the correct coordinate for landmark of cephalogram. Results were graphed between template matching, WNM without the weight Window and with the weighted Window. The highest rate of correct identification was obtained for weighted Window with the value of 40.9% (Yamakawa and Kawano, 2001).

**View box an intelligent system for cephalometry analysis:** Chen *et al.* (2005) describes that the user manually locate the landmarks on the computer screen in the hardware part light box is used to send a X-ray film into touch screen for user interface. Analog to digital conversion takes place. An algorithm named control routines for the touch panel, keep on checking the point located in the X-ray and plot the corresponding point in that X-ray.

**Active appearance model and simulated annealing:** According to Saad *et al.* (2005), this method evaluate usage of AAM followed by simulated annealing for automatic cephalometric analysis. Building AAM consist from strongly appeared edges in the cephalometric images. PCA (Principle Component Analysis) was performed after alignment of all shapes to the mean shape. PCA was used as a dimensionality reduction technique by producing a projection of a set of multivariate samples into a subspace constrained to explain a certain amount of the variation in the original samples. Any shape can be

represented in terms of mean shape, matrix of eigen vectors of the covariance matrix arranged to their percentage of variation and shape model parameter. The non-linearity produced by the alignment process must be avoided by transients-space projection. Then, 2nd PCA was performed on the texture vectors to obtain from the training set a model of the texture variation. In order to remove the correlation between shape and texture model parameter and making the mode representation more compact, 3rd PCA was performed on the concatenation shape and texture parameters to obtain the combined mode parameter. AAM treat the search algorithm as an optimization problem in which the difference between the synthesized object delivered by AAM and the actual image is to be minimized.

**Cephalometric landmark identification using probabilistic relaxation:** Favaedi and Petrou (2010) describe that cephalometric utilize semi automatic system to plot landmarks directly on the screen. Background is removed with a help of white mask. Edges were identified with the help of canny edge detection techniques. Local histogram equalization is achieved for preprocessing the image. After preprocessing, the next step is to scale the model and place it on the scene. To facilitate the scale measuring process between the scene and the model, the soft tissue surrounding the nose is used as a reference feature. The position of the profile in the scene must also be identified. This can be achieved by identifying the first white point in each row when we scan the image from right to left. After that the soft tissues profile in the model and the scene are considered as two separate images. To finds first, the cartesian coordinates are converted to polar coordinates, normalized cross correlation spectrum matrix were formed. Using probabilistic relaxation and deformable contours elastically deform the template and matches to the images. The cephalometry landmarks were identified with 30.95% accuracy for <1 mm tolerance.

**Active contour detection:** In order to facilitate the cephalometric landmark detection based on pattern recognition and machine learning method. Preprocessing operation is performed including normalizing, enhancement and edge detection. Deformable template is generated with a group of labeled X-ray images as training the model. Contour detection is achieved with the help of deformable templates. After setting the landmark matrices, it was intended to obtain a prototype of deformable templates. The template consists of four elements; a geometric prior, an occlusion process, an image model and a dynamic programming optimization algorithm.

The geometric prior describes probabilistically what configurations the soft tissue template is likely to assume and the imaging model together with the occlusion process describe probabilistically how any particular configuration will appear in a gray scale image. These first three elements assigns a posteriori probability to each possible contour configuration.

A dynamic programming algorithm searches for the maximum a posteriori configuration, the configuration that optimally fits the image data. Last step is to find the optimal path and store the position of the ancestor node for tracing back. The optimal path are lined out and landmarks are highlighted. By this method, soft tissue detection parts are detailed but need more focus on hard contour detection.

**Landmark detection using a domain independent techniques in cephalograms:** The automated procedure involved segmenting with a pulse coupled neural network, computation of an average template and then thresholding the template to obtain the shapes. An investigation of detection program that used the PCNN derived shapes demonstrated a significant improvement in detection performance when compared to the handcrafted shapes when tested on the menton, upperlip and sella landmark points. Overall the result suggest that the automated shape generation procedure will give detection performance that is not worse than the hand crafted procedure.

**Layered diffusion and dilated skelton maps:** According to Ma *et al.* (2006), a multiscale method for craniofacial landmark detection mainly contributes some aspects. It is the first method for layered structure formation. A knowledge based template, statistically derived application cases is applied to determine the diffusion offsets in creating layered structures. Second, it is a way for decision based on EDM dilated skeletons. Prominent landmarks of large structures could be exactly determine diffusion by a big magnitude offset diffusion and landmarks of tiny structures corresponding to small offset obtaining their approximates position from the knowledge of point relationship to those distinguished ones. The actual location will be available after dilations and erosions.

**Particle swarm optimization:** Wijesinghe (2005) describes that the particle swarm optimization is a technique used for finding a certain combination of parametric data that when given to a function, causes the function to return as the fitness function used by particle swarm optimization, supplied by the user. A characteristic of the fitness

function is that it returns better fitness or evaluation values when it is given parametric value. The input to each landmark detector program is a small Window, containing the surrounding pixel relative to a position on the image. The size of the Window has been determined to contain some of the distinctive area surrounding the target landmark. The detection program accepts these visual feature values as parameter at each point on the image and returns a value that indicates the likelihood of the target landmark on that position. Accuracy of the landmark detection is yet to be a problem. Manually assisted feature Window design has led to better detection results than automated feature design.

**Semi automatic landmark localization on 2D cephalometric images:** For feature extraction, a graphical user interface has been designed. Firstly, using GUI three landmark points are marked on each image. Then using these three points, 21 features are extracted from each image. These feature parameters measure the exact position of skull and rotation of skull according to relative position. The feature is fed through the trained neural network. Finally, desired landmark locations are obtained as a network output. This is semi automatic landmark localization (Gajendra *et al.*, 2010).

**Improving cephalogram analysis through feature subimage extraction:** Instead of the global image, a limited region corresponding to each feature subimage was defined for GA searching. The size of the region was evaluated statistically based on the distribution of features of the training set. About 80 subimages were randomly selected within each limited region. All the positions (x, y) of upper-left corner of subimages were encoded as the strings to form a population for the GA. Their fitness value for each sub image was estimated using a trained MLP. The individuals with higher fitness values were selected for reproduction and crossover to generate the next offspring iteratively. An MLP with a GA was proposed to extract feature subimages containing orthodontic landmarks. Simulated images and cephalograms were used to investigate its performance in comparison with the cross correlation method. From the results of simulated image containing shapes, different geometrical conditions can be identified. The performance of the MLP can be significantly improved by collecting more representative false patterns. The GA is a good approach to speed up the process of feature sub image extraction based on the fitness evaluated using MLP (Chen *et al.*, 1999).

**Approach to fuzzy location of cephalometric landmark in craniofacial superimposition:** According to Ibanez *et al.*

(2009), craniofacial superimposition is the second stage of a complex forensic technique that aims to identify a missing person from a photograph and the skull found. This specific task is devoted to find the most appropriate pose of the skull model to be projected onto photograph. The process is guided by a number of landmarks identified both in the skull (Craniofacial landmark) and in the face (Cephalometric landmarks). Genetic algorithm-based approach was involved in the location of the cephalometric landmarks and its influence in the matching between these landmarks and the craniofacial. Procedure is through the use of an IR technique to properly align the 3D skull model and the 2D face photograph in a common co-ordinate frame. That registration transformation is defined by 12 parameters which are encoded in a real-coded chromosome. It proposed the use of fuzzy landmark to tackle the uncertainty related to landmark for a complex forensic identification task called craniofacial superimposition. It used two different sets of landmark provided by forensic anthropologists for two photographs of the same identification case. As a drawback, the fuzzy approach implies more computational operation with the consequent increment in the run time required for GA.

**Mixed signal VLSI for real-time generation of edge-based image vectors:** According to Yagi (2003), a mixed-signal image filtering VLSI has been developed aiming at real-time generation of edge-based image vectors for image recognition. A four-stage asynchronous median detection architecture based on analog digital mixed-signal circuits has been introduced to determine the threshold value of edge detection, the key processing parameter in vector generation. As a result, a fully seamless pipeline processing from threshold detection, to edge feature map generation has been established. A prototype chip was designed in a 0.35  $\mu\text{m}$  double-polysilicon three-metal-layer CMOS technology and the concept was verified by the fabricated chip. The mixed-signal median filter VLSI circuit for PPED vector generation was presented. A four-stage asynchronous median detection architecture based on analog digital mixed-signal circuits had been introduced. As a result, a fully seamless pipeline processing from threshold detection to edge feature map generation had been established. A prototype chip was designed in a 0.35  $\mu\text{m}$  CMOS technology and the fabricated chip generates an edge based image vector every 80  $\mu\text{sec}$  which is about 104 times faster than the software computation.

**Automatic localization of cephalometric landmarks:** According to Mohseni and Kasaei (2007), the proposed algorithm uses the information of the marked landmarks

on a reference normal cephalometry image as the prior knowledge. The image is automatically divided into several regions and three main control points are located on it. These are then matched to their corresponding points on the reference image to form an affine transform matrix that describe how other points on the reference should be mapped to the target image. Each mapped point is used as an initial estimation of the landmark location on the target image. The accurate location of each landmark is detected within a surrounding window position around the estimated initial point of the landmark using edge-detection, image histogram and curve fitting scheme. The similarities are available in human anatomy to estimate the initial location of each landmark. Then address the difference by applying the accurate landmark definition in a small region of interest. The image processing and pattern matching techniques are combined to locate the three main reference landmarks on each image which are then used to form affine matrix. The matrix is used to estimate the initial location of the other landmarks. The initial points of the remaining landmarks are obtained from the reference lines. By assuming a region around each initial location and using a proper method based on the definition of each landmark, the accurate location of each landmarks are defined and localized in small search regions.

**Robust cephalometric landmark identification using SVM:** Chakrabartty *et al.* (2003) discuss that this study uses Support Vector Machine (SVM) to model discrimination boundaries between different landmarks and also between the background frames. Large margin classification with non-linear kernels allows to extract relevant details from the landmarks, approaching human expert levels of recognition. In conjunction with Projected Principal-edge Distribution (PPED) representation as feature vectors, SVM is able to demonstrate >95% accuracy for landmark detection on medical cephalograms within a reasonable location tolerance value. For each training image, a template of PPED vectors corresponding to the landmark frames were extracted. The image was then scanned pixel by pixel and 64×64 pixel frame was extracted. PPED vectors for each frame was computed and its kernel distance was computed to extract the similarity metric to all landmark PPED vectors. Two PPED vectors for each landmark were chosen as negative candidates. The first one with the highest kernel score amongst all frames that were at least 256×256 pixels away from the landmark. The second one is with the highest kernel score amongst all the frames within 256×256 pixels of the landmark. The utility of such a technique surpasses human performance, especially when high dimensional

non-linear features have to be evaluated for identification. Such a scenario occurs during identification of landmark orbitale O and ANS which the recognizer is able to identify with near perfect accuracy. But this method is applicable for edge based landmark because of projection edge distribution algorithm only.

**N-dimensional scale invariant feature transform for medical images:** Landmark based image registration is for building statistical models of shape and appearance. The scale-invariant feature transform produces stable features in two dimensional images. Extending SIFT to N-dimensional images, it evaluates the extensions in the context of medical images. N-SIFT locates position that are stable in the image, creating a unique feature vector and matches the feature vectors between two scalar images of arbitrary dimensionality (Cheung and Hamarneh, 2007).

**Accuracy of angular cephalometry measurements with scanned lateral cephalogram:** This study is to compare the accuracy of angular cephalometric measurements on scanned cephalograms with manual tracing as the gold standard. Cephalometric analysis of specified angular measurements was performed on cephalometric radiographs manually. Radiographs were subsequently scanned and the images were analyzed digitally with computer software for the same measurements. Paired sample tests were used for statistical significance ( $p < 0.05$ ). Clinical significance was set as  $> 2^\circ$  difference between the methods for any angular measurement (Shaheed *et al.*, 2009).

Cephalometric comparisons between original and digital images showed statistically significant differences for various angles (SNA, MMA, IMPA and Nasolabial angles). None of the means of the difference between the two methods  $> 1^\circ$ .

The differences in landmark identification error between the film-based and digital methods including the statistically significant differences were  $> 2$  units of measurements (degrees). This indicates that even the statistically significant differences between the two methods of cephalometric analyses were unlikely to be of any clinical significance. Scanned images of lateral cephalogram are equally accurate and reliable clinically for angular cephalometric analysis.

**Genetic programming for landmark detection:** This approach involves dividing the landmark detection problem into 56 independent sub-problems. Each of these problems involves finding a specific landmark in a region of the X-ray. For each landmark and each region, it

evolves a program that can be placed over a small Window and give a positive response if the Window is centered on the landmark. The program will then be applied to the region in moving Window fashion to find the landmark. Inputs to the evolved program will be a set of features based on partitioning the area surrounding a landmark into specific shapes individual to the landmark characteristics. The features consist of the mean and standard deviation of pixel intensities for each shape. First, a database of images is assembled with the known positions of landmarks to be located. Then domain knowledge is used to extract regions in which the landmarks are expected to be. Some sub-images are reserved as unknowns for measuring detection performance as the test set. Then *square\_size* is the size of a square centred on the landmark determined that will contain enough distinguishing information to permit the landmark to be identified. This is the size of the input Window that will be used by the evolved program. Appropriate shapes (Feature map) were determined manually in the input Window that are expected to be applied to the training images and the landmark points were discriminated from the background. An evolutionary process was evolved to generate a program which can determine whether a landmark in its input field. Finally, the generated program as a moving template was applied to the reserved test images and obtain the positions of the landmarks were obtained. The detection rate and the false alarm rate on the test set as the measure of performance was calculated. A drawback of the method is that run times for the evolutionary process are high, one run of 100 generations taking around 3 h on a 1400 MHz pentium 4 computer. However, this is a once-only cost. Applying the evolved program to an image is very fast taking around 0.1 sec. Given the coarseness of the features used, particularly for the nose tip and incisor points, the detection accuracy achieved is surprising and suggests that with more attention to the features, the approach will be successful on the more difficult landmarks (Ciesielski *et al.*, 2003).

**A non-anatomical soft and hard tissue centroid line in cephalometrics:** According to Al-Shahrani *et al.* (2010), the applicability of an introduced non-anatomical soft and hard tissue cephalometric centroid line (S and H centroid) was investigated in this research. The S and H centroid line established from 12"×14" lateral cephalometric radiographs of 57 selected adults was used as a base to create a new cephalometric reference line Centroid-Nasion (C-N). The reliability and the use of the newly created Centroid-Nasion (C-N) as a reference line was tested against the conventional Sella-Nasion (S-N)

cephalometric reference line to evaluate the sagittal and vertical maxillary and mandibular relationship. Pearson's correlation coefficient, one way ANOVA and Tukey multiple comparison post-hoc statistical tests were used. The digitization technique was reliable. The Centroid-Nasion (C-N) cephalometric reference line created by utilizing the S and H centroid line was found to be as useful as the conventional Sella-Nasion (S-N) cephalometric plane in establishing and differentiating between sagittal and vertical intermaxillary relationships. A Centroid-Nasion (C-N) reference line was created utilizing the newly introduced soft and hard tissue centroid. The digitization technique was reliable. The C-N reference line appears to be as useful in establishing and differentiating between the sagittal and vertical maxillo-mandibular relationship as the conventionally used anterior cranial (S-N) based cephalometric analysis.

**Landmark detection for cephalometric images using pulse coupled neural networks:** According to Innes *et al.* (2002), this study is to determine whether a Pulse Coupled Neural Network (PCNN) can be used to highlight regions containing key craniofacial features from digital X-rays. The method uses an averaging filter to minimize noise followed by a PCNN to highlight the features relevant to the detection of the landmark. The output of the PCNN, a binary image will be used by a subsequent process such as curve following or Hough transform to identify the position of the cephalometric landmark. The method was tested on three landmark detection problems of increasing difficulty in terms of background noise and contrast. On a test set of 109, images the PCNN was able to accurately segment regions containing soft tissue and bony structure with a success rate of 93.6 and 88.1%, respectively, suggesting that PCNN pre-processing will be very useful for landmarks on the boundary between two different tissue types. The PCNN was able to extract features surrounding the very difficult Sella point with a success rate of 36.7%. This could be improved by manual adjustment of PCNN parameters; however, a way of finding good parameter values automatically needs to be found before PCNN processing will be useful for the difficult points. The PCNN technique will be useful in finding landmark points on boundaries between different types of tissues. The results for the sella point are poor. However they were obtained with one standard set of PCNN parameters.

**Reliability of landmark identification in cephalometric radiography acquired by a storage phosphor imaging system:** According to Chen *et al.* (2004), this study compares the cephalometric landmark identification on

softcopy and hardcopy of direct digital cephalography acquired by a Storage-phosphor (SP) imaging system. Ten digital cephalograms and their conventional counterpart, hardcopy on a transparent blue film were obtained by a SP imaging system and a dye sublimation printer. Twelve orthodontic residents identified 19 cephalometric landmarks on monitor-displayed SP digital images with computer-aided method and on their hardcopies with conventional method. The x- and y-coordinates for each landmark indicating the horizontal and vertical positions were analyzed to assess the reliability of landmark identification and evaluate the concordance of the landmark locations in softcopy and hardcopy of SP digital cephalometric radiography. For each of the 19 landmarks, the location differences as well as the horizontal and vertical components were statistically significant between SP digital cephalometric radiography and its hardcopy. Smaller inter observer errors on SP digital images than those on their hardcopies were noted for all the landmarks except point Go in vertical direction. The scatter-plots demonstrate the characteristic distribution of the inter observer error in both horizontal and vertical directions. Generally, the dispersion of inter observer error on SP digital cephalometric radiography is less than that on its hardcopy with conventional method. The SP digital cephalometric radiography could yield better or comparable level of performance in landmark identification as its hardcopy except point (Go) in vertical direction.

**Computer assisted landmarking of cephalometric radiographs:** According to Desvignes *et al.* (2000a), the method used to detect and extract the endocranial contour where the coordinate space is fixed in which all further processes will take place. The model is to store the variability of the features derived from the sampled endocranial contour in the previous coordinates space and used by identification process. The mean value and standard deviation of these features represent this variability.

A training set, processed by expert is used for this purpose. The number of parameters derived from the sampled endocranial contour can be reduced. The last part explains how the model is used to compute the desired landmarks on new radiography. The main feature of this research is different from traditional affine registration and mean model. With the use non-linear registration before building a model, it is reduced to the mean and standard deviation of the coordinates of the landmarks.

**Contour tracking by minimal cost path approach**  
**Application to cephalometry:** By Romaniuk *et al.* (2004),

a minimal cost approach is used contour tracking. Dynamic programming was chosen for its efficiency. This general method is applied to the extraction of the cranial contour high resolution X-ray images. As a first step of automated localization of cephalometric points, an ellipse is then fitted on the extracted contour. An iterative approach is used for tracking this contour which is the stronger gradient path. In this approach, the best successor is computed at each iteration in a local region. The main idea here is to define a cost function. This function has to evaluate the cost of a contour by computing the cost for each point of this contour. This cost should be minimal at the starting point of an area. This minimal cost path is the contour. The first few points of this contour are retained and the tracking is iterated. The cost function must represent the contour intensity. It must also be invariant to contrast variations.

The selected function is thus the opposite gradient of the image. The concept of regional maximum suppresses my concept of threshold and allows a great robustness. The detection of the higher part of the cranial contour is done when the path reaches the point. This is a method for contour tracking which has been applied to cranial contour extraction.

The detected contour can then be considered as the background for statistical localization of cephalometric points. It can be used to define an invariant co ordinate's space for the cephalometric problem.

**First steps toward automatic location of landmarks on X-ray images:** This study describes about locating some anatomical bone structures on lateral cranial X-ray images. The main problem in this pattern recognition application is that the landmarks are difficult to distinguish on images even for the human expert because of lateral projection of the X-ray process (Desvignes *et al.*, 2000b).

This research consist of a three steps approach; the first step provides a statistical estimation of the landmarks using an adaptative coordinate space. The second step computes a region of interest around the estimated landmark. In the third step each landmark is precisely located using its anatomical definition. This study describes the two first generic steps and gives examples of the last step for two anatomical points.

**Computerized cephalometric line tracing technique:** According to Sinthanayothi (2009), the cephalometry tracing lines can lead to the measurement of the skull both in lateral and PA views in both bones and soft tissue section and also can lead to the diagnostic abnormalities of skull, face and teeth. PA view can be used for analysis on symmetry of the skull. There are four steps involved.

First the X-ray image can be preprocessed via, adaptive, local contrast enhancement. Next the landmark is defined by the dentists on both lateral and PA X-ray images. Tracing lines are automatically generated by the deformable template registration and cubic spline fitting techniques. Tracing lines are smoothed by all lines into bitmap data which an interpolation techniques and the result was shown through drawings.

### CEPHALOMETRY STANDARDS FOR VARIOUS NATIONS

**Cephalometric analysis of mashhad children based on natural head position:** Basafa and Shahri (2007) describe that there was no cephalometric norm available for the children of Mashhad. The most suitable method to prepare a cephalogram is for the head to be captured in its Natural Position (NHP) and drawn on the basis of its true horizontal reference line. In traditional cephalometric analysis, SN or other planes are used as a reference plane. For this particular studies, cephalometric norms are formed on the basics of the NHP method for children with normal occlusion in Mashhad. This is due to the clockwise rotation of the mandible. So, the conclusion is each nation should have its own cephalometric criteria.

**Cephalometric analysis for evaluating the profile nasal morphology in Egyptian adults:** This study is to establish similar measurements for adult Egyptian males and females. Also, the results are compared to that of the Caucasian nose. In current study, lateral. Cephalograms are traced manually then vertical, horizontal and angular measurements are taken. Results are analyzed to set up the normative Egyptian standards for the nose of this age group. By comparing the results to that of the Caucasian, some differences are noticed. Cephalometry is proved to be a good tool for nasal shape analysis. The main advantage of this study is giving a standard lateral cephalometry nasal profile measurements for Egyptian people of both genders helping in rhinoplasty surgical decisions and improving postoperative outcomes. It is hoped that the result of this piece of work will provide more objective database helping in making surgical decisions improving postoperative outcomes by El-Hadidy *et al.* (2007).

### ABNORMALITIES IN CEPHALOMETRY

**Unilateral cleft lip and palate patients:** Bongaarts *et al.* (2008) describe that the measurements with A, ANS and PNS were compared to measurements performed with alternatives for A, ANS and PNS namely; A1, A2, ANS1, ANS2 and PNS1. In young cleft lip and palate patients

identification of cephalometric landmarks is even more difficult due the abnormal anatomy. This especially holds true for localization of the landmarks point A, Anterior Nasal Spine (ANS) and Posterior Nasal Spine (PNS). Point A, ANS and PNS can be hard to locate because of reduced radiopacity due to the cleft. Although, many cephalometric studies on facial growth in unilateral cleft lip and palate patients have been published. Only few discuss in detail the reliability of cephalometric measurements in which point A, ANS and PNS are involved landmarks for Maxilla. All lateral head films were traced by hand in which only one was observed and 16 lateral head films were traced. The traditional landmarks A, ANS and PNS are difficult to trace in children with UCLP.

### Foetal alcohol syndrome

**A cephalometric analysis of patients and controls:** According to Naidoo *et al.* (2006), Foetal Alcohol Syndrome (FAS) consists of multi-system abnormalities and is caused by the excessive intake of alcohol during pregnancy. The teratogenic effect of alcohol on the human foetus has now been established beyond reasonable doubt and FAS is the most important human teratogenic condition known today. The purpose of this study was to analyse the craniofacial parameters of children with FAS and compare them with matched controls. This study has shown that measurements related to face height and mandibular size appear to be the most important features when distinguishing FAS children. Overall, the FAS children in the present study presented a vertically and horizontally underdeveloped maxilla, together with features of a long face syndrome with a large gonial angle and a short ramus in relation to total face height. There was also a tendency for the development of an anterior open bite which appears to be compensated for by an increase in the anterior alveolar process to bring the incisor teeth into occlusion. The latter adaptation occurred mainly in the mandible.

### THREE DIMENSIONAL CEPHALOMETRIC SYSTEM

**Solution for the correction of cephalic malpositioning in 3D cephalogram:** Three dimensional coordinates of orthodontic landmarks from lateral and frontal cephalograms have been achieved by various equations. The plane determined by the midpoint of bilateral porion and bilateral orbita is defined as the standard plane. Ear rod has been considered as an origin point for further calculation. 3D cephalometric system has been corrected not only for magnification of the image but also corrected the 3D cephalic malpositioning during cephalogram exposure (Mori *et al.*, 2001).



**From 2-3D algorithm to derive normal values for computerized assessment:** Measurements of midface length, mandibular length and lower anterior face height from both examinations were calculated. Two other groups of measurements were derived mathematically from the dimensions directly quantified on the lateral cephalogram namely; the magnification correction group and the algorithm correction group. All measurements from the lateral cephalogram were significantly different from the corresponding measurements derived from the CBCT. Simply taking into account the image magnification did not correct the 2-dimensional linear measurement obtained from a conventional cephalogram into a 3-dimensional linear measurement made on a CBCT scan unless the structure from which the distance will be measured are located on the midsagittal plane when the algorithm was used to correct the CBCT group and the algorithm group (Gribel *et al.*, 2011).

**Three-dimensional cephalometric analyses:** According to Olszewski *et al.* (2010), 3D CT reconstructions were achieved by ACRO-3D software. The 3D surface rendering was based on the marching cubes algorithm. The 3D cephalometric analysis can be sub-divided into two groups; dimensional and topological:

- Dimensional analysis was based on measurement between reference landmarks. To provide a diagnosis, the set of measurement of a subject must be compared to the norms established for a large population
- Topological analysis provides 3D geometrical reference frames using the reference landmarks

The common denominator for these two groups of analysis was the individual identification of craniofacial reference landmarks based directly on a 3D CT surface rendering. Three cranial planes and nine craniofacial planes are considered to define the 3D cranial and craniofacial reference frames. The alignment of different structures along the reference planes was indicative of the type of dysmorphia present in the craniofacial skeleton. ACRO-3D software guided the user through the manual point-picking procedure a systematic way. Some landmarks were automatically identified and constructed. The software reduced the workload of the user by calculating and automatically constructing 13 planes from previously identified landmarks. Some landmarks required additional information such as the gender and age of the patient in order to be automatically constructed. When using the 3D-ACRO software (Which requires the observer to manually select the landmark directly on the

3D CT reconstruction). The sella landmark was not floating and was always positioned on the floor of the sella turcica.

## OVERVIEW FOR VARIOUS SOFT COMPUTING TECHNIQUES

**A combination of region based initial segmentation and active surface:** Segmentation is an essential step in the analysis of medical images. For segmentation of 3D data set in the clinical practice, methods are necessary which have a small user interaction time and which are highly flexible. Two steps are involved; coarse segmentation using the image transformation and an active surface creates the final segmentation (Pohle *et al.*, 2003).

In coarse segmentation, the original data set with a resolution in x and y direction of 512×512 voxel is mapped onto 64×64 voxel. In first step of the algorithm, the user marks initial foreground and background regions by drawing lines interactively in few lines of this data set I. The interaction occur in 3 sections of plane which are parallel to the three coordinates axes. The local neighborhood and the edge cost were calculated. Edge cost is nothing but absolute difference of the gray values of the adjacent voxel. Parametric deformable models have been applied for many different segmentations. The boundary between foreground and background voxel is smoothed with a boxcar filter. Two threshold values are determined. According to threshold, internal and external boundary was defined. In first step of coarse segmentation, a initial surface was extracted and search corridor was found using the region based segmentation approach based on the IFT algorithm. In the second step, the initial surface was adapted on the real object surface using the active surface segmentation method.

**Segmentation based on contextual label tree for retrieval:** Liu *et al.* (2011) describe that this is based on the traditional wavelet-domain Hidden Markov Tree (HMT). Multiscale segmentation method, a contextual label tree method is presented.

Dependency information between image block belong to different scales including the relation from further the father node. This method calculates the maximal similarity. The basic principle of image segmentation is to make the inside feature or attributes same or similar which considered in one kind image, in order to advance the precision of image retrieval. Multi-scale image segmentation is a process that connecting the adjacent fixed scale image Windows and realizing image segmentation. The big Window contains more pixels and has higher statistical reliability. Small Window reduces

reliability but it can reflect the load character of the image. This method is mainly classified as texture images and medical images.

**Online handwriting recognition using support vector machine:** According to Ahmad *et al.* (2004), the objective is to further improve the recognition rate by using support vector machine at the segment classification level.  $R^n \times R$  samples are taken to calculate the joint probability distribution. From that risk, function is applied and also empirical minimization is performed. SVM finds optimal hyper plane as the solution. SVM recognition rates are significantly better due to structural risk margin of separation in the decision function. Research on integrating the SVM character recognition framework into the HMM based word recognition framework is on the way.

In the hybrid system, word preprocessing and normalization needs to be done before SVM is then used for character hypothesis recognition and word likelihood computation using HMM. Due to SVM producing better discrimination capability, word recognition rate will be better than in a NN/HMM hybrid system.

**A practical guide to support vector classification:** Support vectors are a useful technique for data classification. In this, data is transformed to the format of an SVM package. It is made simple scaling on the data. The RBF kernel function is considered. Cross-validation is used to find the best parameter  $C$  and  $\gamma$  (Hsu *et al.*, 2010; Genov and Cauwenberghs, 2003). The best parameter  $C$  and  $\gamma$  to train the whole training set. Use that equation for test. First step is scaling. The advantage of scaling is to avoid attributes in greater numeric ranges. It is also used to avoid numerical difficulties during the calculation. Kernel values usually depend on the inner product of feature vectors. Scaling is applicable to both training and also testing data. RBF kernel is the first choice. This kernel non-linearly maps samples into higher dimensional space so, it unlike linear kernel, it can handle the case when the relation between class labels and attributes is non-linear. In addition, sigmoid kernel behaves like RBF for certain parameters. The number of hyper parameters influences the complexity of model selection. The polynomial kernel has more hyper parameters than the RBF kernel. Then cross validation procedure can prevent the over fitting problem.

## CONCLUSION

This comparative study describes about cephalometry analysis of lateral cephalogram. Various

techniques are applied to find landmark points with more accuracy. There are some previous attempts to automate cephalometric analysis with the aims of reducing the time required to obtain an analysis, improving the accuracy of landmark identification and reducing the errors due to clinician subjectivity. Even, there are some techniques are available. The problem is in accuracy and the automatization of cephalometric process. One more disadvantage of cephalometric is a two dimensional representation of a three dimensional structure making it impossible to make all the measurement. Very few researches of the before mentioned describes about soft tissue growth. Future works would be directed towards in 3D conversion and also considering changes soft tissue in cephalogram.

## REFERENCES

- Ahmad, A.R., C.V. Gaudin, M. Khalid and R. Yusof, 2004. Online handwriting recognition using support vector machine. Proceeding of the 2nd International Conference on Artificial Intelligence in Engineering and Technology, Aug 3-5, Kota Kinabalu, Malaysia, pp: 250-256.
- Al-Shahrani, I.S., K.M. Al-Balkhi and A. Al-Madi, 2010. The applicability of a non-anatomical soft and hard tissue centroid line (S and H centroid) in cephalometrics. Saudi Dent J., 22: 63-67.
- Basafa, M. and F. Shahri, 2007. Cephalometric analysis of mashhad children based on natural head position. J. Mashhad Dent. Sch., 31: 4-8.
- Bongaarts, C.A., M.A. Van't Hof, P.B.R. Andersen and A.M.K. Jagtman, 2008. Identification of cephalometric landmarks in unilateral cleft lip and palate patients: Are there alternatives for point A, ANS and PNS? Cleft Palate Cranio Facial J., 45: 81-86.
- Chakrabartty, S., M. Yagi, T. Shibata and G. Cauwenberghs, 2003. Robust cephalometric landmark identification using support vector machine. Proceeding of the International Conference on Acoustics, Speech and Signal Processing IEEE, April 6-10, Baltimore MD, USA, pp: 825-828.
- Chen, Y.T., K.S. Cheng and J.K. Liu, 1999. Improving cephalogram analysis through feature subimage extraction. Proceeding of the Engineering in Medicine and Biology Magazine, Jan-Feb 1999, IEEE Publication, pp: 25-31.
- Chen, Y.J., S.K. Chen, H.W. Huang, C.C. Yao and H.F. Chang, 2004. Reliability of landmark identification in cephalometric radiography acquired by a storage phosphor imaging system. Dento Maxilla Fac Radiol., 33: 301-306.

- Chen, Y.T., K.S. Cheng, J.K. Liu and J.J. Huang, 2005. An intelligent view box system for cephalometry. *Proceeding of the IEEE Transaction on Instrument and Measurement*, Feb 2005, IEEE Publications, pp: 98-104.
- Cheung, W. and G. Hamarneh, 2007. N-dimensional scale invariant feature transform for medical images. *Proceeding of the 4th IEEE International Symposium on Biomedical Imaging: From Nano to Macro*, April 12-15, Arlington, VA, pp: 720-723.
- Ciesielski, V., A. Innes, S. John and J. Mamutil, 2003. Genetic programming for landmark detection in cephalometric radiology images. *Int. J. Knowledge Based Intell. Eng. Syst.*, 7: 164-171.
- Desvignes, M., B. Romaniuk, R. Clouard, R. Demoment, M. Revenu and M.J. Deshayes, 2000a. First steps toward automatic location of landmarks on X-ray images. *Proceeding of the 15th International Conference Pattern Recognition*, Sep 3-8, Barcelona Spain, pp: 275-278.
- Desvignes, M., B. Romaniuk, R. Demoment, M. Revenu and M.J. Deshayes, 2000b. Computer assisted landmarking of cephalometric radiographs. *Proceeding of the 4th IEEE southwest symposium on Image Analysis and Interpretation*, April 4, Austin TX, USA., pp: 296-300.
- El-Hadidy, M.M.D., A.B. El-Din, M.D.L. El-Bassioni and M.S.W Attal, 2007. Cephalometric analysis for evaluating the profile nasal morphology in Egyptian adults. *Egypt J. Plast. Reconstr. Surg.*, 31: 243-249.
- Favaedi, L. and M. Petrou, 2010. Cephalometric landmark identification using probabilistic relaxation. *Proceeding of the Annual International Conference (EMBS) of the IEEE*, Aug31-4Sept, London, UK, pp: 4391-4394.
- Gajendra, K.M., T. Mondal, H.K.Sardana, A. Jain and N. sharma, 2010. Semi automatic landmark localization on 2D cephalometric images. *Proceeding of the National Conference on Computational Instrumentation*, Mar 19-20, Chandigarh, India, pp: 82-85.
- Genov, R. and G. Cauwenberghs, 2003. Kerneltron: Support vector machine in silicon. *Proceeding of the IEEE Transactions on Neural Networks*, September 2003, Baltimore MD, USA, pp: 1426-1434.
- Gribel, B.F., M.N. Gribel, F.R. Manzi, S.L. Brooks and J.A. Jr McNamara, 2011. From 2D to 3D algorithm to derive normal values for 3-dimensional computerized assessment. *Angle Orthodont.*, 81: 3-10.
- Hsu, C.W., C.C. Chang and C.J. Lin, 2010. A practical guide to support vector classification. *Bioinformatics*, 1: 1-16.
- Ibanez, O., O. Cordon, S. Damas, S. Guadarrama and J. Santamaria, 2009. A new approach to fuzzy location of cephalometric landmarks in craniofacial superimposition. *Proceedings of the 2009 IFSA World Conference, ESFLAT Conference (IFSA-EUSFLAT'09)*, July 2009, Lisbon, Portugal, pp: 195-200.
- Innes, A., V. Ciesielski, J. Mamutil and S. John, 2002. Landmark detection for cephalometric radiology images using pulse coupled neural networks. *Proceedings of the International Conference on Artificial Intelligence*, June 2002, Las Vegas, CSREA, pp: 511-517.
- Keustermans, J., W. Mollemans, D. Vandermeulen and P. Suetens, 2010. Automated cephalometric landmark identification using shape and local appearance model 2010. *Proceeding of the 20th International Conference on Pattern Recognition*, Aug 23-26, Istanbul, Turkey, pp: 2464-2467.
- Liu, H., Y. Zhan and C. Zhang, 2011. Medical image segmentation based on contextual label tree for retrieval. *J. Comput. Inf. Syst.*, 7: 1472-1478.
- Ma, L., S. Jiang, Y. Zhang, C. Lin and H. Lu, 2006. Craniofacial landmark detection by layered diffusion and dilated skeleton maps. *Proceeding of the 9th International Conference on Control Automation, robotics and Vision*, Dec 5-8, Singapore, pp: 1-5.
- Mohseni, H.J. and S. Kasaei, 2007. Automatic localization of cephalometric landmarks. *Proceeding of the IEEE International Symposium on Signal Processing and Information Technology*, Dec 15-18, Giza, pp: 396-401.
- Mori, Y., T. Miyajimai, K. Minami and M. Sakuda, 2001. An accurate three dimensional cephalometric system: A solution for the correction of cephalic malposition. *J. Orthod.*, 28: 143-149.
- Naidoo, S., A. Harris, S. Swanevelder and C. Lombard, 2006. Foetal alcohol syndrome: A cephalometric analysis of patients and controls. *Eur. J. Orthodont.*, 28: 254-261.
- Olszewski, R., O. Tanesy, G. Consnard, F. Zech and H. Reychler, 2010. Reproducibility Of osseous landmark used for computed tomography based three-dimensional cephalometric analyses. *J. Cranio MaxilloFacial Surg.*, 38: 214-221.
- Pohle, R., T. Behlau and K.D. Toemmes, 2003. Segmentation of 3-D medical image data sets with a combination of region based initial segmentation and active surface. *Proc. SPIE.*, 5032: 1225-1232.
- Romaniuk, B., M. Desvignes, M. Revenu and M.J. Deshayes, 2004. Contour tracking by minimal cost path approach: Application to cephalometry. *Proceeding of the International Conference on Image Processing*, Oct 24-27, France, pp: 937-940.

- Saad, A.A., A. El-Bialy, A.H. Kandil and A.S. Ahmed, 2005. Automative cephalometric analysis using active appearance model and simulated annealing. Proceedings of the GVIP 05 Conference, December 19-21, 2005, CICC, Cario Egypt, pp: 253-257.
- Shaheed, S., U. Bashir and N. Arshad, 2009. Accuracy of angular cephalometry measurements with scanned lateral cephalogram. Pak. Oral Dent. J., 29: 68-72.
- Singh, G., 2007. Text Book of Orthodontics. 2nd Edn., Jaypee Brothers Medical Publishers, New Delhi, India, ISBN: 9788184480801, Pages: 704.
- Sinthanayothi, C., 2009. Computerized cephalometric line tracing technique on X-ray images. Proceedings of the 13th International Conference on Bio Medical Engineering's, December 3-6, 2008, Singapore, pp: 265-269.
- Turner, P.J. and S. Weerakone, 2001. An evaluation of the reproducibility of landmark identification using scanned cephalometric images. J. orthod., 28: 221-229.
- Wijesinghe, G., 2005. Landmark detection on cephalometric X-rays using particle swarmoptimization. Honours Thesis, RMIT University, Melbourne, Australia.
- Yagi, M., H. Yamasaki and T. Shibata, 2003. A mixed signal VLSI for real-time generation of edge-based image vectors. Proceedings of 7th Annual Conference on Neural Information Processing Systems, December 8-12, 2003, Whistler, BC, Canada, pp: 1-8.
- Yamakawa, T. and H. Kawano, 2001. Identification of a landmark in a roentgenographic cephalometry By employing the wavelet neurons. Int. J. Neural Syst., 11: 329-334.