

Intercanine Distance as a Recognition Method of Bite Marks Induced at Cases of Child Abuse

C. Stavrianos, D. Tatsis, P. Stavrianou, A. Karamouzi, G. Mihail and D. Mihailidou
Department of Endodontology (Forensic Odontology), Aristotle University, Thessaloniki, Greece

Abstract: Now-a-days in the civilized societies, one of the most reprehensible and criminal actions is considered to be child abuse either it appears as physical or psychological violence. The clinician is the 1st to verify signs and symptoms that can lead in the diagnosis of an abused child. This happens because the most common form of abuse is bite mark which derives from physical, sexual abuse or even neglect. For this reason, the role of dentist is important to ascertain such a background through clinical examination. The aim of this study to highlight the clinical evidence that a dentist should take under consideration. The intercanine distance is a clinical factor that contributes in the early assessment of the proper identification of the assaulter since, the distance differs from one person to another and mostly from children to adults. Thus, the age of the perpetrator will be defined and the self-inflicted traumas will be excluded. In conclusion, a possible judicial process will be facilitated from the dentist's deposition always with the pre-requisite of a full scientific acknowledgement.

Key words: Child abuse, bite mark, intercanine distance, identification, sexual abuse, dentist

INTRODUCTION

Child abuse is a public health problem existing all over the world. The victims of child abuse can be separated in two categories; the ones who lived through and those who did not. Child abuse can be defined as any non-accidental trauma, failure to meet basic needs or abuse inflicted upon a child by the caretaker that is beyond the acceptable norm of childcare in the culture. Abuse may cause serious injury to the child and may even result in death. And this can range from habitually humiliating a child to not giving the necessary care and from excessively shaking a child to rape (Kenney and Spencer, 1995; Vale, 1997).

These behaviors are serious crimes both as misdemeanors and felonies, punishable by arrest and imprisonment. Dentists should be aware that physical or sexual abuse may result in oral or dental injuries or conditions that sometimes can be confirmed by laboratory findings. Furthermore, injuries inflicted by one's mouth or teeth may leave clues, regarding the timing and nature of the injury as well as the identity of the perpetrator. About 65% of child abuse injuries involve head neck or mouth areas because crying and speaking originate from the mouth and this area is among the most usual focus of attack in all cases of violent child abuse (Vale, 1997; Sweet and Pretty, 2001). So, dental personnel are in good position to note and report abuse and are encouraged to

be knowledgeable about such findings and their significance and to meticulously observe and document them. When questions arise or when consultation is needed, a pediatric dentist or a dentist with formal training in forensic odontology can ensure appropriate testing, diagnosis and treatment. As dentists will probably have more chances to see those cases of hypodermal bleeding in faces, abrasions and mandible fractures they need to keep it in mind all times (Sweet, 1995; Herschaft *et al.*, 2006).

IDENTIFICATION OF BITE MARKS

Bite marks are mostly seen in crimes of passion. These may include homicide, rape/sexual assault, domestic violence (child abuse, partner abuse, elderly abuse) and battery/fighting (occlusional, impact). The bite marks can be caused by animal (dogs, cats and domestic animals, cows, wild cats, reptiles, fish). They may be ante-mortem or post mortem. They also may be self-inflicted (back vs. dorsum of forearm, children psychological disturbance and epilepsy) (Murmah *et al.*, 2006; Souviron and Silver, 2009).

The critical questions when there are signs and marks on a person's and especially child's skin are whether this is a bite mark if it is human or not if it is caused by a child or adult if it is self-inflicted and if it is identifiable (if it has enough unique characteristics to be attributable to one

particular perpetrator). A classical bite mark consists of oval/circular mark consisting of 2 opposing arcades, separated by a small open space at their bases, diameter of 25-40 mm, central bruising or multiple tiny haemorrhages and clear tooth marks and dental characteristics that may give high evidentiary value (Rawson *et al.*, 1984a; Sweet, 2000).

CHILD'S OR ADULT'S BITE MARK

According to recent studies, the 38.8% of bite mark victims are children. This arises a lot of legal issues at the authorities and the clinicians who originally come up with these findings. Regarding the age of the victim and the location of bite marks, younger infants have usually been bitten at cheek, neck, shoulders and buttocks and as a

result of uncontrollable anger in response to continuous crying or soiling (Jessee, 1995). Other children and adolescents usually have bite marks at breasts and abdomen and this shows a higher risk of sexual abuse. Other forms of abuse, regardless of bite marks, involve emotional abuse and child neglect. Anatomically, a deciduous dentition consists of smaller, rounded, bow like arches with smaller teeth and spacing between them. These characteristics though concern only the age between 3-6 years before the eruption of any permanent tooth (Wagner, 1986; Spencer, 1995; Stavrianos and Vasiliadis, 2002; Souviron and Silver, 2009). The accepted guideline for a proper recognition of a child's to an adult's dentition is the intercanine distance (Fig.1).

In rough, distances <30 mm belong to a child and a distance above that to an adult. Recent studies state that the intercanine distance at 3-6 years of age range from 28-29 and 4.4 mm smaller than at adults. In addition, the range at adults, based on 397 arches is from 21.3-41 mm (Fig. 2) (Bernstein, 1997; Rawson *et al.*, 1984b; Pretty and Sweet, 2001).

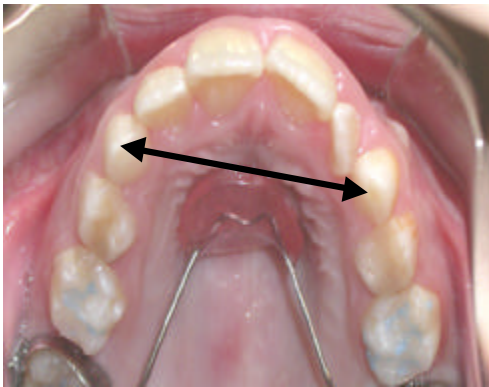


Fig. 1: The intercanine distance is marked with a double black arrow

INTERCANINE DISTANCE AND ANIMAL BITE MARKS

Animal bites cause 1% of all emergency cases and 1-2% of these patients require hospitalization. The most frequently affected are children aged up to 6 years (52.8%). Where 80-85% of all bites are dog bites, 10% are cat bites and 5-15% are other animal bites (Health A to Z, 2005; Knezevic *et al.*, 2006). Bite wounds located at the face, neck and head are most frequent in children (73%) whereas only 30% of adult dog bite traumas are located at the head and the neck (Weiss *et al.*, 1998). Unlike human bites, dog attacks on human may result in severe and sometimes even fatal injuries. The diagnosis of such injuries can often be established on the basis of typical tooth marks at the edges of the wounds and specifically the intercanine distance. Bite marks in these cases vary but they leave predictable patterns on the bone tissue as a result of various factors such as jaw size, bone density and bone force.

Generally, the most frequent sites of an injury are on the head, face and the neck. Lesions usually involve a combination of biting, clawing and crushing forces resulting in wounds with a characteristic pattern of punctures, lacerations and avulsion of the skin and other soft tissues (Tonn *et al.*, 2004; Murmann *et al.*, 2006; Santoro *et al.*, 2010). The normal distance between the maxillary canine teeth in adult humans is 2.5-4.0 cm and the canine marks in a bite will be the most prominent or deep parts of the bite. Bites produced by dogs and other

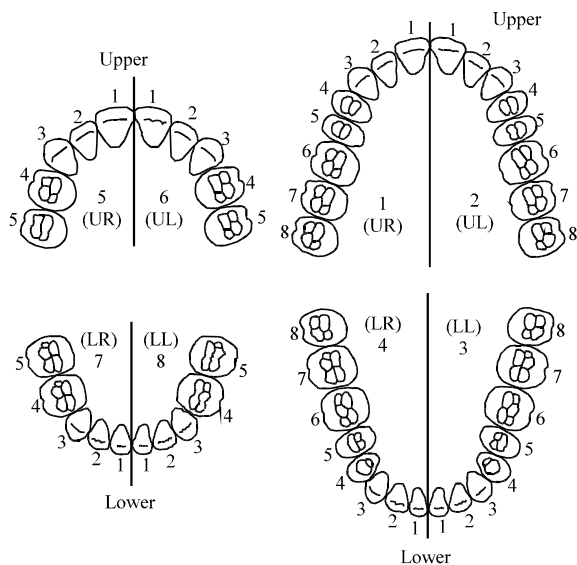


Fig. 2: The intercanine distance and the difference between the curvature of the deciduous (left) and the permanent (right)

carnivorous animals tend to tear flesh whereas human bites compress flesh and can cause abrasion, contusions, lacerations but rarely avulsion of tissues. Furthermore, human bites reflect the canine teeth but they usually include the incisors as well due to the relative flatness of the edges of human teeth when compared to those of animals. Something that should be included in the diagnose procedure is that carnivores have six incisors and two very large canines per arch, compared to human arches that have only four incisors and much smaller canines. Conclusively, animal bites can be very violent, resulting in extensive injuries requiring great skill to analyze them properly. All sings should be taken into consideration in order to exclude a possible animal bite mark (Tomn *et al.*, 2004; Murmann *et al.*, 2006).

LEGAL ASPECTS

As it has been discussed before, there are some discreet lines on what an adult is and what a child according to the intercanine distance, an anatomical term based on scientific findings. Legally, though there are not some standardization on this. First of all, there is a huge difference between the countries on the globe. In some the age of adulthood is 18 years old and in others this age is at the 21st birthday of the person.

Although in some countries, marriage is allowed at 16 years of age and a possession of a driving licence at the age of 17. In general, despite the fact that the dental maturity accrues at the age of 12-14 years of age, the legal responsibilities cannot forced at an age <18. As a result, the method of intercanine distance may not always predict in a safe way the age of the assaulter and the best way to identify them is by following the bite mark analysis protocol, as it is standardized by the American Board of Forensic Odontology (ABFO, 2000; Vermeylen, 2006).

DEFINING PHYSICAL EVIDENCE AS CHILD ABUSE

When a child presents for examination, particularly if there is any evidence of severe or repeated trauma involved, the history may alert the dentist to the possibility of a child abuse. Indeed, the history may be the single most important source of information. Because legal proceedings may follow the history should be recorded in detail. One should consider abuse or neglect whenever the history reveals the following:

- History of multiple injuries
- The family offers an explanation that is not compatible with the nature of the injury
- Delay in seeking care for the injury
- The family avoids discussing about the injury

While the above findings are by no means conclusive, they should cause the dentist to look further for general physical findings, possible signs of abuse. The intercanine distance is a scientific examination that helps the general dentist to define whether a bite mark is induced by a human, a draft age estimation of the assaulter (adult or child) and excluding the possibility of a self-inflicted trauma (Stavrianos and Metska, 2002; Stavrianos *et al.*, 2007).

DISCUSSION

In the last half of the 20th century and the 1st few years of the 21st century, many cases have been tried in courts worldwide that include bite mark testimony. The majority of these were in physical and sexual assault cases, family violence cases and in child and elder abuse cases. Although, homicide cases involving bite marks are more widely publicized and therefore better known they represent a minority of the total cases (Freeman *et al.*, 2005). Consider a child abuse case involving bite marks. The DNA and fingerprints of potential suspects such as the parents, siblings and other caregivers can and will be present. But a bite mark injury which may represent abuse or assault was neither accidentally created nor a result of incidental contact. If the features of the bite mark injury can include and equally importantly, exclude individuals then the analysis of the pattern has significant forensic value not possessed by the other modalities (Sweet and Shutler, 1999). The evidence of severe and repeated trauma should alert the dentist to identify possible child abuse. The ability of proper identification of suspicious injuries to the head, face, mouth and neck of the child is of great importance for the dentists. History can be the only valid source of information and as legal procedures may follow everything should be written down in a very detail. Offenders look like ordinary people.

Although, its not accurate or fair to create a profile of child abuser, statements of the general behavior can be made, based on studies of abuse perpetrators. People with a history of child abuse in their own childhood or of abuse against other children with problems with alcohol or drug abuse with anger management, especially to poor parenting skills and with poor coping skills, especially related to problem solving and making or having choices. So, it is of major importance to realize that all dentists have a unique opportunity as well as ethical obligation to assist in the struggle against child abuse and institute actions that might save children's lives. The comfort level of a given child must be such that they will even disclose it directly. So, dental personnel must understand their importance for the stop of pain and death of children's maltreatment by adopting the appropriate knowledge and training so as to recognize and report the signs

successfully (ADA, 1995; Souviron, 2005; Souviron and Silver, 2009). A bite mark on child's skin will change soon after the incident from a specific mark of the teeth to a blur bruise with an indifferent shape (Spencer, 1995). The only outcome that the forensic scientist can conclude in after clinical examination is the origin of the bite mark (human or not) and through the size the age of the assaulter (child or adult). Thus, the exclusion or indication of possible identification of an assaulter can present certain abuser or rule out another. A precise photography must be assured in order to have a comparison standard and as a result, increase the potentiality of a possible recognition (Kraus, 1984; Wright and Golden, 1997; Spencer, 2004).

In certain cases in order to ensure that the 3rd dimension of a mark is collected, an impression should be taken with a silicone dental impression material including the surrounding tissues and preserve it properly for later examination (Sweet, 1995). The technique of transillumination can give specific measures of the dental arch and finally identify the age of the assaulter through the intercanine distance.

CONCLUSION

As a final result, the law enforcement can be enabled and the assaulter may even pledge guilty prior to trial, only by presenting the certain forensic evidence (Spencer, 2004). Concluding as far as the intercanine distance measure procedure is concerned, it is a good indication method in order to predict the age of the assaulter but always the standard procedure of the ABFO should be followed in order to have proper evidence and match the bite with the assaulter.

REFERENCES

- ABFO, 2000. Guidelines and standards: Bitemark Guidelines and Standards. American Board of Forensic Odontology, Colorado Springs.
- ADA, 1995. Council on Dental Practice: The Dentist's Responsibility in Identifying and Reporting Child Abuse. 3rd Edn., American Dental Association, Chicago, IL.
- Bernstein, M.L., 1997. Forensic dentistry. Overview of forensic dentistry. *J. Okla. Dent. Assoc.*, 88: 18-28.
- Freeman, A.J., D.R. Senn and D.M. Arendt, 2005. Seven hundred seventy eight bite marks: Analysis by anatomic location, victim and biter demographics, type of crime and legal deposition. *J. Forensic Sci.*, 501: 436-443.
- Health A to Z, 2005. Encyclopaedia. Animal bite infections.
- Herschaft, E., M. Alder, D. Ord, R. Rawson and E. Smith, 2006. Manual of Forensic Odontology. ASFO, Impress Printing and Graphics Inc., New York, pp: 210-240.
- Jessee, S.A., 1995. Physical manifestations of child abuse to the head face and mouth: A hospital survey. *ASDC. J. Dent. Child.*, 62: 245-249.
- Kenney, J.P. and D.E. Spencer, 1995. Manual of Forensic Odontology. In: DNA and Forensic Odontology, Bowers, C.M. and G.L. Bell (Eds.). American Society of Forensic Odontologists, UK., pp: 191-199.
- Knezevic, B., P. Knezevi, V. Uglesic and V. Zubicic, 2006. Facial bite wound. *Acta Stomatol. Croat.*, 40: 83-88.
- Kraus, T.C., 1984. Photographic techniques of concern in metric bite mark analysis. *J. Forensic Sci.*, 29: 633-638.
- Murmann, D.C., P.C. Brumit, B.A. Schrader and D.R. Senn, 2006. A comparison of animal jaws and bite mark patterns. *J. Forensic Sci.*, 51: 846-860.
- Pretty, I.A. and D. Sweet, 2001. The scientific bases for human bite mark analysis-a critical review. *Sci. Justice*, 41: 85-92.
- Rawson, R.D., A. Koot, C. Martin, J. Jackson, S. Novosel, A. Richardson and T. Bender, 1984a. Incidence of bite marks in a selected juvenile population: A preliminary report. *J. Forensic Sci.*, 29: 254-259.
- Rawson, R.D., R.K. Ommen, G. Kinard, J. Johnson and A. Yfantis, 1984b. Statistical evidence for the individuality of the human dentition. *J. Forensic Sci.*, 29: 245-253.
- Santoro, V., G. Smaldone, P. Lozito, M. Smaldone and F. Introna, 2010. A forensic approach to fatal dog attacks. A case study and review of the literature. *Forensic Sci. Int.*, 206: 37-42.
- Souviron, R.R. and W.E. Silver, 2009. Dental Autopsy. CRC Press, Taylor and Francis Group, LLC, USA., pp: 151-193.
- Souviron, R.R., 2005. Animal Bites. In: Bitemark Evidence, Dorian, R. (Ed.). Marcel Dekker, New York, pp: 275-291.
- Spencer, D.E., 1995. Bite Marks in Child Abuse. Manual of Forensic Odontology. 1st Edn., Printing Specialists, Pontpelier, VT., pp: 177-178.
- Spencer, E.D., 2004. Child abuse: Dentists recognition and involvement. *J. California Dental Assoc.*, 32: 299-303.
- Stavrianos, C. and L. Vasiliadis, 2002. Forensic Odontology. Investigation of Injuries and Bite Marks. Computer I/O Press, Thessaloniki.
- Stavrianos, C. and M.E. Metska, 2002. Child abuse and neglect. Dental and Forensic Dental Aspect. Thessaloniki, pp: 27-30.

- Stavrianos, C., I. Stavrianou, P. Kafas and D. Mastagas, 2007. The responsibility of dentists in identifying and reporting child abuse. *Internet J. Law, Healthcare Ethics*, 1: 1-16.
- Sweet, D.J., 1995. Human Bitemarks: Examination, Recovery and Analysis. In: *Manual of Forensic Odontology*, Bowers C.M. and G.L. Bell (Eds.). American Society of Forensic Odontology, Colorado Springs, pp: 148-170.
- Sweet, D. and G.G. Shutler, 1999. Analysis of salivary DNA evidence from a bite mark on a body submerged in water. *J. Forensic Sci.*, 44: 1069-1072.
- Sweet, D., 2000. Human bite mark evidence. *Proceedings of the European IOFOS Millennium Meeting*, Aug. 23-26, Leuven, Belgium, pp: 75-79.
- Sweet, D. and I.A. Pretty, 2001. A look at forensic dentistry-Part 2: Teeth as weapons of violence-identification of bitemark perpetrators. *Br. Dent. J.*, 190: 415-418.
- Tom, E., D.J. Long and D. Dechant, 2004. A comparison of intercanine widths among various animals and humans. *Proceedings of the 56th Annual Meeting of the American Academy of Forensic Sciences*, Feb. 16-21, Dallas, TX, American Academy of Forensic Sciences, Colorado Springs, CO.
- Vale, G.L., 1997. Dentistry's Role in Detecting and Preventing Child Abuse. In: *Forensic Dentistry*, Stimson, P.G. and C.A. Mertz (Eds.). 1st Edn., CRC Press, Boca Raton, New York, pp: 161-162.
- Vermlyen, Y., 2006. Guidelines in forensic odontology: Legal aspects. *Forens. Sci. Int.*, 159: 6-8.
- Wagner, G.N., 1986. Bitemark identification in child abuse cases. *Pediatr. Dent*, 8: 96-100.
- Weiss, H.B., D.I. Friedman and J.H. Coben, 1998. Incidence of dog bite injuries treated in emergency departments. *J. Am. Med. Assoc.*, 279: 51-53.
- Wright, D.F. and S.G. Golden, 1997. Forensic Photography. In: *Forensic Dentistry*, Stimson, G.P. and A.C. Mertz (Eds.). CRC Press, Boca Raton, FL. USA., pp: 105-106.