

## Management of Primary Non-Aggressive Mandibular Giant Cell Tumor: A 14 Years' Experience

Silvia Tortorici, Maria Lidia Buzzanca, Francesco Burruano, Luigi Caradonna and Paolo Difalco  
Department of Stomatological Science, University of Palermo, Palermo, Italy

**Abstract:** Giant cell tumor is a rare non-odontogenic lesion that represents approximately 4-5% of all primary bone tumors. Such lesions derive their actual name from the constant presence of numerous giant cells, similar to osteoclasts. All the giant cell tumors historically is treated with curettage. Because this conservative approach is often associated with a recurrence rate of up to 70%, aggressive resection has become the standard practice. Unfortunately, recurrence after wide resection is about 7%. The aim of the study is to describe the 14 years single institution experience with management of primary non-aggressive giant cell tumor of the jaws bone.

**Key words:** Bony lesion, marginal osteotomy, bony healing, jaws, management, Italy

---

### INTRODUCTION

Giant Cell Tumor (GCT) is a rare non-odontogenic lesion that represents approximately 4-5% of all primary bone tumors (Cummins *et al.*, 1996; Sanghvi *et al.*, 1999). The name derives from constant micro-scopic findings of numerous multinucleated giant cells, similar to bone clusters in a background of fibrous connective tissue with abundant ovoid to spindle-shaped mesenchymal cells (Mooney *et al.*, 2003; Mullapudi *et al.*, 2011). Generally, the tumor appears in patients between the ages of 20-55 years, the peak age incidence is in the 3rd decade of life and frequently develops in the epiphysial region of the long bones (Cummins *et al.*, 1996; Sanghvi *et al.*, 1999; Thomas *et al.*, 2001; Dubey *et al.*, 2003). In the mandible or maxilla the primary GCT is decidedly rare (Sheikh *et al.*, 1999; Chan *et al.*, 2003). The etiology of the GCT is still open to question. It is possible that these lesions have a neoplastic origin or arise following a trauma. The biological behaviour is extremely various and even if the lesions are benign, present an local aggressiveness with a high recurrence rate. GCT was considered aggressive when the lesion was >4-5 cm in size and the cortical bone was damaged or expanded and teeth displaced (Troulis *et al.*, 2004; Mohanty and Jhamb, 2009; Amaral *et al.*, 2010). Surgery is the mainstay of treatment of this bony lesion. Historically, GCT was treated with curettage. Because this conservative approach is often associated with a recurrence rate of up to 70% (Sanghvi *et al.*, 1999), a wide resection has become a standard practice for the aggressive form of tumor (Troulis *et al.*, 2004). Unfortunately, recurrence after wide

resection is about 7% (Sanghvi *et al.*, 1999). The aim of the study is to describe the 14 years single institution experience with management of primary non-aggressive GCT in the jaws bone.

### MATERIALS AND METHODS

The researchers undertook a retrospective review of surgical records (clinical charts, biologic tests and radiologic investigations) held by the department and identified all patients with primary GCT of the jaws who had undergone surgical treatment between January, 1991 and June, 2006. A patient was considered eligible for the study if the records were adequate. Adequate records were; a pre-operative imaging of the lesion (orthopantomograms, intraoral radiographs or computed tomography), a careful description of surgical method, a preoperative diagnosis and follow up records with radiographic examination (orthopantomograms, intraoral radiographs or computed tomography). Patients were excluded when had an unsatisfactory follow-up duration or (<5 years) or if they had an aggressive GCT. Thus, the researchers investigated 15 patients with GCT who had undergone surgical treatment comprising 2 lesions into the maxillary bone (all the subjects were females) and 11 tumor into the mandible (10 subjects were females whilst 3 were males). The medical records of the selected patients were checked; age and sex of the patients, number and anatomic location of lesions and radiological findings were noted. The total of individuals was caucasian. The female to male ratio was 5:1; patients' age ranged from 12-51 with a mean age of 32 years. All the

patients showed a single lesion. Most of the cases were asymptomatic and were located in the posterior portion of the jaws. Radiographic findings are diverse ranging from small uni-locular lesions to large multi-locular lesions with displacement of teeth, root resorption. Before surgical treatment an incisional biopsy was taken from all lesions under local anaesthesia (Mepivacaine, 2% with ephedrine) for histological examination. After histological diagnosis, the researchers treated patients. A single surgical team including 2 oral surgeons with >10 years' experience, performed all the surgical treatment. The researchers carried out a wide marginal osteotomy for 8 small GCTs (diameter <3 cm); those lesions were removed by an intraoral approach and marginal osteotomy with at least a 1 cm safety margin beyond the tumor radiographic limits. In those cases, jaw bone continuity was conserved and the periosteum was minimally sacrificed. The others 6 GCTs were treated with curettage. The researchers repair all defects with a free bone graft. Patients were followed-up on after 15 days, 6 months, 1 year. Then, the subjects were undergone at annual follow-up consisting of clinical and radiographic examination up to a period of at least 5 years.

**RESULTS AND DISCUSSION**

The researchers compared subjects who were treated with bony curettage with those in which the treatment was a wide marginal osteotomy. The lesion variables examined included dimensions and complete healing (no recurrence of the lesion) after treatment. The primary parameter was complete healing. The distribution of complete healing was estimated by using Kaplan-meier analysis. According to this methodology, comparison between 2 survival curves is made by the Log-rank test. Statistical differences between groups were accepted for  $p < 0.05$ . A statistician who was blind to treatments, carried out statistical analysis with MedCalc Software Version 12<sup>®</sup> (MedCalc Software, Broekstraat 52, 9030 Mariakerke, Belgium). The initial sample comprised 15 patients with a single lesion. With regard to treatment results only patients with a minimum follow-up period of 5 years were included, 14 patients fulfilled these criteria. In fact, a patient with GTC primarily treated by marginal osteotomy were lost to follow-up after 2 years because she dead thus drop-out rate was of 7%. Among patient treated with wide marginal osteotomy 1 patient had a recurrence after 1 year and 2 patients after 2 years. In contrast, only one patient treated with bony curettage had a complete healing. Kaplan-meier survival analysis was used to evaluate differences between 2 type of treatment. The Kaplan-meier survival curves are shown in Fig. 1.

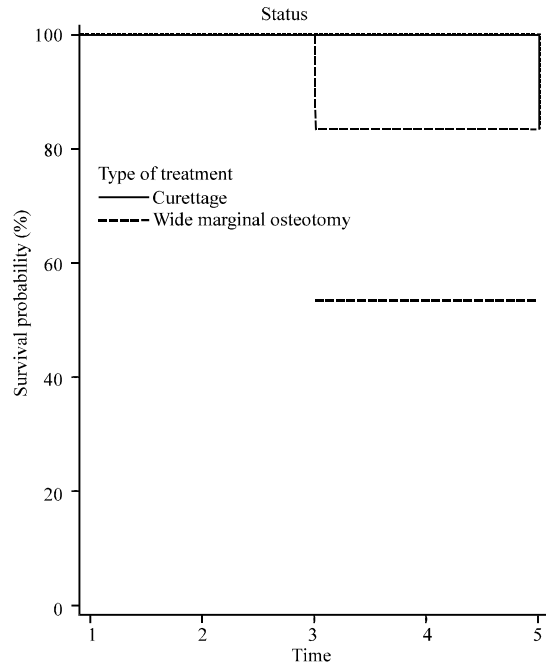


Fig. 1: The graphic reports the Kaplan-meier survival curves. The comparison of survival curves (Logrank test) shows statistical significant differences ( $p = 0.4795$ ) between two groups

The comparison of survival curves (Logrank test) showed statistical significant differences ( $p = 0.4795$ ) between two groups.

GTC is usually located intraorally and rarely extraorally. The tumor can be encountered in any area of the jaws but most often it is located in the posterior regions of the mandible (in particular the horizontal branch). The maxilla and anterior region of the mandible are rarely affected. The aetiology of the lesions with multinucleated giant cells is controversial. Researcher separated giant cells tumor from giant cells granuloma of the bone because he considered giant cells in the giant cells granuloma as a phagocytic response to traumatic intraosseous hemorrhage or a periosteal reaction (Jaffe, 1953; Liu *et al.*, 2003). Auclair *et al.* (1988) suggested that both central Giant Cell Granulomas (GCG) and GCT represent a spectrum of a single disease process modified by the age of the patient and the site of occurrence. Actually, the origin of multinucleated giant cell is discussed. Many researchers suggested that multinucleated giant cell may be formed by the fusion of the precursors derivate of monocyte-macrophage lineage. Liu *et al.* (2003) demonstrated that multinucleated giant cell shows an osteoclasts phenotype. Treatment choice depends on some factors such as the tumor extension and age of the patient. Actually treatment of GTC remains

controversial. When GCT is >4-5 cm, the researchers perform a segmental resection of lesion with a 1.5-2 cm margin beyond the radiological limit. In those cases, the researchers use fibular grafts for reconstruction of bone defect. Researchers prefer the free vascularized fibula because it has significant potential for the reconstruction of the mandible (Aydin *et al.*, 2004). In fact fibular graft show short- and long-term stability and its rate of atrophy is significantly lower than that of edentulous or dentulous mandibular bone (Disa *et al.*, 1997; Holzle *et al.*, 2007). Age is another important factor when considering treatment options. In case of a preoperative diagnosis of GCT in children, it is tempting, mainly for psychosocial reasons to perform less aggressive surgery. Patients undergoing mandibular aggressive resection often show serious esthetic and functional sequelae such as facial asymmetry (a retruded and deviated mandible), motor and sensory deficiencies, speech alterations and abnormal intermaxillary relationship and occlusion (Oelgiesser *et al.*, 2004).

### CONCLUSION

In those cases, the researchers prefer to perform an immediate reconstruction to prevent esthetic sequelae and to restore the mastication and speech. This is very important to determine an adequate quality of life. When the GTC is non-aggressive, it can be removed with a conservative surgical approach. This technique minimizes the mandibular defects but this conservative approach tends to have a rate of recurrence. In the current study, the researchers compared subjects who were treated with bony curettage with those in which the treatment was a wide conservative. The results of the study suggest that a wide marginal osteotomy has a high success rate.

### REFERENCES

- Amaral, F.R., C.C. Gomes, C.S. Oliveira, P.E. Souza and R.S. Gomez, 2010. Clonality analysis of giant cell lesions of the jaws. *Braz Dent. J.*, 21: 361-364.
- Auclair, P.L., P. Cuenin, F.J. Kratochvil, L.J. Slater, G.L. Ellis, 1988. A clinical and histomorphologic comparison of the central giant cell granuloma and the giant cell tumor. *Oral. Surg. Oral Med. Oral. Pathol.*, 66: 197-208.
- Aydin, A., U. Emekli, M. Erer and G. Hafiz, 2004. Fibula free flap for mandible reconstruction. *Kulak Burun Bogaz Ihtis Derg.*, 13: 62-66.
- Chan, J., F.H. Gannon and L.D. R. Thompson, 2003. Malignant giant cell tumor of the sphenoid. *Diagn. Pathol.*, 7: 100-105.
- Cummins, C.A., M.T. Scarborough and W.F. Enneking, 1996. Multicentric giant cell tumor of bone. *Clin. Orthop.*, 322: 245-252.
- Disa, J.J., R.M. Winters and D.A. Hidalgo, 1997. Long-term evaluation of bone mass in free fibula flap mandible reconstruction. *Am. J. Surg.*, 174: 503-506.
- Dubey, R.B., N.P. Tara and S.M. Desai, 2003. Giant cell tumor of sinonasal cavity: An uncommon location for a common bone Tumor. *Ind. J. Radiol. Imag.*, 13: 13-14.
- Holzle, F., A. Watola, M.R. Kesting, D. Nolte and K.D. Wolff, 2007. Atrophy of free fibular grafts after mandibular reconstruction. *Plast Reconstr. Surg.*, 151: 156-156.
- Jaffe, H.J., 1953. Giant cell reparative granuloma, traumatic bone cyst and fibrous (fibro-osseous) dysplasia of jaw bones. *Oral. Surg. Oral. Med. Oral. Pathol.*, 6: 159-175.
- Liu, B., S.F. Yu and T.J. Li, 2003. Multinucleated giant cells in various forms of giant cell containing lesions of the jaws express features of osteoclasts. *J. Oral Pathol. Med.*, 32: 367-375.
- Mohanty, S. and A. Jhamb, 2009. Central giant cell lesion of mandible managed by intralesional triamcinolone injections. *Med. Oral Patol. Oral Cir. Bucal.*, 14: 98-102.
- Mooney, W.W.W., G.P. Bridger, M. Baldwin and M. Donellan, 2003. Recurrent giant cell tumour of the maxilla associated with both paget's disease and primary hyperparathyroidism. *Anz J. Surg.*, 73: 863-864.
- Mullapudi, S.V., U.K. Putcha and S. Boindala, 2011. Odontogenic tumors and giant cell lesions of jaws-a nine year study. *World J. Surg. Oncol.*, 5: 9-68.
- Oelgiesser, D., L. Levin, S. Barak and D. Schwartz-Arad, 2004. Rehabilitation of an irradiated mandible after mandibular resection using implant/tooth-supported fixed prosthesis: A clinical report. *J. Prosthet. Dent.*, 91: 310-314.
- Sanghvi, V., M. Lala, S. Desai, P. Chaturvedi and G. Rodrigues, 1999. Synchronous multicentric giant cell tumour: A case report with review of literature. *Eur. J. Surg. Oncol.*, 25: 636-637.
- Sheikh, M., F.A. Chisti and T. Sinan, 1999. Giant cell tumour of the temporal bone: Case report and review of the literature. *Australas Radiol.*, 43: 113-115.
- Thomas, R., S.S. Banerjee, B.P. Eyden, J.H. Shanks and D.L. Bisset *et al.*, 2001. A study of four cases of extra-orbital giant cell angiofibroma with documentation of some unusual features. *Histopathology*, 39: 390-396.
- Troulis, M.J., W.B. Williams and L.B. Kaban, 2004. Staged protocol for resection, skeletal reconstruction and oral rehabilitation of children with jaw tumors. *J. Oral. Maxillofac Surg.*, 62: 335-343.