

Collagen-Calcium Alginate Film Dressing with Therapeutic Ultrasound to Treat Open Wound in Rats

¹M.A. Khaled, ¹A. Jalila, ²H. Kalthum, ¹M. Noordin and ³W. Asma Saleh

¹Faculty of Veterinary Medicine, University Putra Malaysia,
43400 Serdang, Selangor, Malaysia

²Faculty of Veterinary Medicine, Universiti Malaysia Kelantan,
16100 Kota Bharu, Kelantan, Malaysia

³Faculty of Science and Technology, University Sains Islam Malaysia,
Bandar Baru, 71800 Nilai, Negeri Sembilan, Malaysia

Abstract: About 24 healthy female Sprague-Dawley rats weighing between 300-350 g were used in this study over a 20 day period. They were allocated randomly into 4 groups of 6 animals each. After the creation of 2×2 cm open wound, group 1 was control treated with Gentamycin ointment. Groups 2-4 were treated with Therapeutic ultrasound massage, collagen-calcium alginate film and collagen-calcium alginate film with therapeutic ultrasound. On application, the collagen-calcium alginate film with therapeutic ultrasound was well accepted by the animals without any adverse reaction. Mean percentage of wound contraction were significantly better in group 4 ($p < 0.05$). Faster epithelialization was also seen in the collagen-calcium alginate film with therapeutic ultrasound treated group as compared to the other groups. Collagen is a biocompatible protein that does not interfere with the body's normal immunologic response and can be used in non-healing chronic wounds which require a trigger to stimulate the normal healing process. In extensive wounds when there is lack of autologous tissue, biomaterials like collagen-calcium alginate may be beneficial and can be used.

Key words: Ultrasound, collagen, calcium alginate, wound, biomaterials, tissues

INTRODUCTION

Wound healing is one of the most complex biological events after birth (Gillitzer and Goebeler, 2001). It is a complex process of the replacement of dead tissue by a vital tissue (Rubin and Farber, 1994). The response of the body to local injury begins very early in the process of inflammation and results in repair and regeneration. Regeneration is a replacement of injured tissue by parenchymal cells of the same type, sometimes leaving no residual trace of the previous injury (Kumar *et al.*, 2003). Repair is a replacement by connective tissue which in its permanent state constitutes a scar (Menetrey *et al.*, 2000). The objectives of any wound management are relief of pain and distress to the animal, functional and cosmetic repair, economic and time efficient procedures and prompt decision making in the event of signs of delayed healing (Cockbill, 2002). In chronic wounds, the major focus of wound healing has been on the relationship between tissue destruction by excess inflammation and tissue synthesis stimulated by a pro-healing environment. Natural polymers have been increasingly studied for

applications in health care due to their biocompatibility, biodegradability and nontoxicity (Mali *et al.*, 2006). Collagen-based film is a potentially useful biomaterial, since it is the major constituent of the connective tissue and permits controlled drug release within the target tissues (Gopinath *et al.*, 2004). Alginates are highly absorbent, gel-forming materials with haemostatic properties (Blaine, 1947) and it has long been known that more rapid wound healing occurs when a gel is formed at the wound surface and dehydration is prevented (Winter, 1995). In contact with body fluids, alginates are known to break down to simple monosaccharide-type residues and be totally absorbed. The wound exudates convert the calcium to the sodium salt facilitating the removal of the dressing by dissolution. Any residual fibres remaining within the wound are biodegradable, thus eliminating the need for complete removal (Burrow *et al.*, 1983). Non-invasive treatment with ultrasound therapy hastens wound healing by stimulating cellular activity and protein synthesis (Young and Dyson, 1990). Ultrasound therapy can be useful in accelerating the inflammatory and early proliferative stages of repair. The present study

discusses the effect of collagen-calcium alginate film along with therapeutic ultrasound for management of an extensive wound in a rat.

MATERIALS AND METHODS

Study design: A complete randomized design was used to determine the efficacy of collagen-calcium alginate film with therapeutic ultrasound for management on wound healing in rats. The experimental protocol was approved by the Animal Care and Use Committee (ACUC) at the Faculty of Veterinary Medicine, Universiti Putra Malaysia (UPM) (Reference No.: 12R158/May 12-April 13).

Animals: In this study, a total of 24 female Sprague-Dawley rats (weight 300-350 g) were used and they were randomly divided into 4 experimental groups of 6 rats each.

Group 1 (n = 6) control group: Gentamycin ointment (Dutch farm Veterinary pharmaceuticals, Netherlands) was applied after creation of 2×2 cm open wound.

Group 2 (n = 6): Therapeutic ultrasound massage treated group. The 2×2 cm open wound was treated using therapeutic ultrasound massage on the periwound skin after smearing the area with coupling gel 10 mts @ 0.5 watts cm⁻² area (UltraCure PRO™ US-10000, EZUltrasonid; Mobridge, South Dakota).

Group 3 (n = 6): Collagen-calcium alginate film treated group. The 2×2 cm open wound was treated using collagen-calcium alginate film soaked for 1-2 min in gentamycin (Dutch farm Veterinary pharmaceuticals, Netherlands).

Group 4 (n = 6): Collagen-calcium alginate film with therapeutic ultrasound treated group. The 2×2 cm open wound was treated using collagen-calcium alginate film soaked for 1-2 min in gentamycin (Dutch farm Veterinary pharmaceuticals, Netherlands) and therapeutic ultrasound massage was given on the periwound skin after smearing the area with coupling gel 10 mts @ 0.5 watts cm⁻² area (UltraCure PRO™ US-10000, EZUltrasonid, Mobridge, South Dakota). The sample size was designed to minimize the number of animals required which was still adequate to generate statistical analysis. The animals were acclimatized to the laboratory conditions for 1 week prior to the onset of experiment. The rats were individually caged and given commercial pellet and water ad libitum throughout the study.

Skin preparation: Rats were anaesthetized with an Intramuscular (IM) injection of ketamine (35 mg kg⁻¹) and xylazine (5 mg kg⁻¹) into the caudal thigh muscle. When fully anaesthetized, the animals were positioned on their dorsal area which was prepared aseptically for the creation of an open wound (2×2 cm). The skin was disinfected with hibiscrub, containing 0.6% chlorohexidin then with 70% alcohol solution and with 2% iodine solution (Druecke *et al.*, 2004).

Using a sterile millimetre ruler and cotton tipped applicator dipped in sterile methylene blue, a 2 cm² was drawn on the skin. A full thickness skin defect in which all tissue down to and including the panniculus muscle was excised using no. 15 scalpel blade.

Therapeutic ultrasound massage was given on the periwound skin after smearing the area with coupling gel 10 mts @ 0.5 watts cm⁻² area (Altomare *et al.*, 2009).

Collagen-calcium alginate film to cover the wound was soaked in normal saline, kept on the wound and protected with a bandage. The limb was immobilized using a PVC splint and bandage. The same procedure was repeated once a week and the progress in healing was evaluated through wound colour coding, nature and quantity of exudates and odour (James and Bayat, 2003).

Assessment of the wound: The progress of open wound healing was recorded at 0, 4, 8, 12, 16 and 20 days post-wounding. All the wounds were digitally photographed in the presence of a standard reference ruler.

A more accurate method for determining the wound area in healing studies is tracing of the wound margins onto a clear plastic sandwich film. In this method, a double layer sterile plastic sandwich bag was placed on the wound for tracing, the layer that comes into contact with the wound can be removed and disposed of accordingly. The outer layer was placed on to a graph sheet and the squares were measured by square counting procedure. The number of squares (0.04 cm²) that lay completely (Nc) and partially (Np) inside the tracing were counted and the area was determined using the following formula: $A_{c+p} = (N_c + 0.40 \times N_p) \times 0.04$ (Richard *et al.*, 2000). The wound margin at the border between normal skin and the wound and the outlined area was considered to be the total wound area. Next the leading edge of advancing epithelium was traced. The area between these two margins was considered to be the area for epithelialization. The area within the margin of advancing epithelium was taken as the area of open or unhealed wound (Bohling *et al.*, 2004). Percentage of wound contraction was calculated by:

Step 1: Total wound on day_n = Total wound area day_n/original wound area day 0×100.

Step 2: Wound on day_n(%) = 100-total wound on day_n as % of original

Histopathological analysis: Rats were euthanized at day 20 post-operation by halothane inhalation and the skin samples were taken for histopathological examination. The skin samples were fixed in 10% formalin solution and embedded in paraffin. Tissue sections of 4-5 mm thickness were cut, stained with Haematoxylin and Eosin (H&E) and examined under light microscope. Digital photomicrographs were captured at representative locations using a digital camera attached to a Nikon Eclipse FX-35DX microscope.

Statistical analysis: Data are expressed as mean±Standard Deviation (SD). The statistical analysis of data was performed using 2-way ANOVA using the SPSS® Statistical package (SPSS, Version 20.0, Chicago, Illinois, USA). The effects with p<0.05 were considered statistically significant.

RESULTS

The percentage of wound contraction was better in group 3 up to day 12 (59.24%), however it was best in group 4 on days 16 and 20. The difference between groups 2, 3 and 4 compared to group 1 was evident on day 8. The percentage of wound contraction improved from 75.64% (day 16) to almost 93.13% on day 20 in group 4 but group 3 showed an improvement from 17.69% (day 4) to almost 84.55% on day 20 and group 2 showed an improvement from 15.68% (day 4) to almost 78.57% on day 20. Nevertheless, group 4 demonstrated better than average total wound healing throughout the trial (Table 1).

On application, the collagen-calcium alginate films, adhered uniformly to the wound site and were absorbed on the wound site. No unabsorbed remnants were noticed during the next application. In groups 1 and 2 animals, the wound colour was red up to day 12 post-operation and pink in colour from day 16 and 20. Groups 3 and 4 showed

bright beefy red colour up to day 12 and it were red from day 16-20. Malodour was observed up to day 12 post-operation in group 1 and 2 animals. In group 3 and 4 mild malodour were observed up to day 8. Serous exudate was noticed up to day 12 in group 1. Mild serous exudate was noticed up to day 8 post-operation in groups 2 and 3 animals. No exudate was seen in group 4 animals throughout the study (Fig. 1 and 2).

Histopathological study: After 20 days of injury, epidermal regeneration was observed in all experimental wounds. Histopathologic comparisons showed that on day 20, collagen-calcium alginate film+ultrasonic massage treated wounds resulted in better re-epithelialization as compared to the control, ultrasonic massage and collagen-calcium alginate film treated rats. In addition, the inflammatory cells were absent in all treated wounds. In the untreated control wounds, though new epithelium was noted to regenerate, inflammatory cells particularly neutrophils and macrophages were still present on the upper dermis. Less scab formation was seen in the wounds treated with collagen-calcium alginate film+ultrasonic massage as compared to the ultrasonic massage, collagen-calcium alginate and untreated control wounds (Fig. 3).

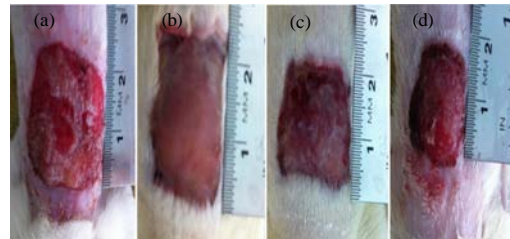


Fig. 1: Open wound on day 4 post-wounding: a) Control-group 1; b) Ultrasonic massage-group 2; c) collagen-calcium alginate film-group 3; d) Collagen-calcium alginate film+ultrasonic massage-group 4

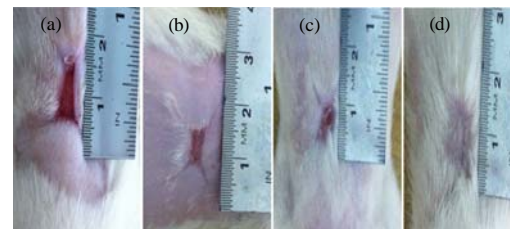


Fig. 2: Open wound on day 20 post-wounding: a) Control-group 1; b) Ultrasonic massage-group 2; c) Collagen-calcium alginate film-group 3; d) Collagen-calcium alginate film+ultrasonic massage-group 4

Table 1: Percentage of wound contraction (mean±SD)

Days	Control Group 1	US massage Group 2	Collagen-Ca Group 3	Collagen-Ca+US Group 4
0	0	0	0	0
4	16.26±0.91	15.68±0.93	17.69±0.08	15.47±0.90
8	27.12±1.37	32.64±3.32	34.67±3.21	33.98±5.66
12	48.70±1.97 ^a	54.27±1.12 ^{ab}	56.09±2.20 ^b	59.24±0.55 ^c
16	64.22±2.70 ^a	68.45±1.68 ^{ab}	74.52±3.32 ^{bc}	75.64±0.73 ^c
20	76.43±0.78 ^c	78.57±1.05 ^c	84.55±1.88 ^d	93.13±0.85 ^d

Values with different superscripts within a row differed significantly at p<0.05

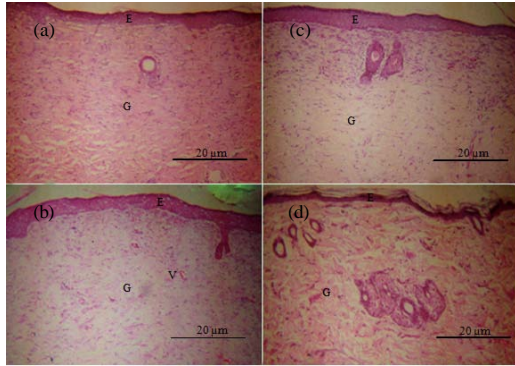


Fig. 3: Histopathology of the granulation tissue from the open wound day 20 post-wounding: a) Control-group 1; b) Ultrasonic massage-group 2; c) Collagen-calcium alginate film-group 3; d) Collagen-calcium alginate film+ultrasonic massage-group 4. (H and E stain 40x); E = Endothelial cell; G = Granulation tissue; V = Blood Vessel

DISCUSSION

In groups 3 and 4, the application of collagen-calcium alginate film was well tolerated by the animals. The film is easy to apply on the wound without any adverse reaction and was well accepted by all the animals. Calcium alginate contains no cellular materials so they do not elicit any immune response (Andersen *et al.*, 2012). The application of collagen-calcium alginate film treated with therapeutic ultrasound did not show any adhesion of the gauze during wound dressing.

The colour of the wound bed in groups 1 and 2 was red while groups 3 and 4 showed a bright beefy red colour which indicates healthy granulation tissue with neovascularisation (James and Bayat, 2003) and resistance to infection until the epithelial barrier is re-established (Hosgood, 2003; Pope, 1993). The bright red colour observed is due to the micro vascular network throughout the granulation tissue (Tonnesen *et al.*, 2000). The basic fibroblast growth factor set the stage for angiogenesis during the first 3 days of wound repair (Schaffer *et al.*, 2004) and plays an important role in granulation tissue formation and the wound healing process (Takehara, 2000). Granulation in all the cases was flat without any exuberant nature, granulation tissue with a smooth surface facilitates migration of epithelial cells (Pope, 1993). On days 16 and 20, the granulation tissue was observed to be pink in colour in groups 1 and 2 which indicates the final stage of wound healing. In groups 3 and 4 the granulation tissue was red in colour due to neovascularisation (James and Bayat, 2003).

Mal-odour was observed up to day 12 in groups 1 and 2, however in groups 3 and 4 mild mal-odour was observed up to day 8 which may be due to infection (James and Bayat, 2003). The presence of bacterial infection was the common cause for the mal-odour observed because all the wounds were infected. Serous discharge was noticed up to day 12 in group 1 and mild serous discharge was noticed up to day 8 in groups 2 and 3, subsequently, the discharge was reduced because healthy vascular granulation tissue is resistant to infection (Hosgood, 2003; Pope, 1993).

The percentage of wound contraction on post wound days 4 and 8 of all groups showed no significant difference, this may be because of an inherent property of fibroblasts that appears early in the process of wound contraction which after some time, do not contract as forcefully as those that appear later (Bohling *et al.*, 2004). Schaffer *et al.* (2004) reported that there is increased fibroblast activity of the body until post-wound day 14. On days 12, 16 and 20, group 4 was significantly better than groups 1-3, since basic fibroblast growth factor effectively accelerated wound fibroblast proliferation (Kawai *et al.*, 2000) and has a characteristic myofibroblastic appearance which plays a critical role in closure and healing (Cheng *et al.*, 2002).

CONCLUSION

Collagen-calcium alginate film along with therapeutic ultrasound can be a better wound healing biomaterial in rats. It can be used as a less expensive skin substitute in order to stimulate and promote wound healing in animals.

ACKNOWLEDGEMENT

The researchers would like to thank the Dean of the Faculty of Veterinary Medical, the Head of Department of Veterinary Clinical Studies for the facilities provided and help rendered during the study.

REFERENCES

- Altomare, M., A.P. Nascimento, B. Romana-Souza, T.P. Amadeu and A. Monte-Alto-Costa, 2009. Ultrasound accelerates healing of normal wounds but not of ischemic ones. *Wound Repair Regen.*, 17: 825-831.
- Andersen, T., B.L. Strand, K. Formo, E. Alsberg and B.E. Christensen, 2012. Alginates as biomaterials in tissue engineering. *Carbohydrate Chem.: Chem. Biol. Appr.*, 37: 227-258.

- Blaine, G., 1947. Experimental observations on absorbable alginate products in surgery: Gel, film, gauze and foam. *Ann. Surg.*, 125: 102-114.
- Bohling, M.W., R.A. Henderson, S.F. Swaim, S.A. Kincaid and J.C. Wright, 2004. Cutaneous wound healing in the cat: A macroscopic description and comparison with cutaneous wound healing in the dog. *Vet. Surg.*, 33: 579-587.
- Burrow, T., M. Welch and G. Cusick, 1983. The Development and use of Alginate Fibre in Nonwovens for Medical End-Uses. In: *Nonwoven Conference Papers*, Cusick, G.E. (Ed.). UMIST, Manchester, England, pp: 49-68.
- Cheng, B., X. Fu, Z. Sheng, X. Gu, T. Sun and X. Sun, 2002. The effect of basic fibroblast growth factor on myofibroblasts and its significance on wound healing. *Zhonghua Yi Xue Za Zhi*, 82: 1187-1191.
- Cockbill, S., 2002. Wounds the healing process. *Hosp. Pharm.*, 9: 255-260.
- Druecke, D., E.N. Lamme, S. Hermann, J. Pieper, P.S. May, H.U. Steinau and L. Steintraesser, 2004. Modulation of scar tissue formation using different dermal regeneration templates in the treatment of experimental full-thickness wounds. *Wound Repair Regen.*, 12: 518-527.
- Gillitzer, R. and M. Goebeler, 2001. Chemokines in cutaneous wound healing. *J. Leukocyte Biol.*, 69: 513-521.
- Gopinath, D., M.R. Ahmed, K. Gomathi, K. Chitra, P. Sehgal and R. Jayakumar, 2004. Dermal wound healing processes with curcumin incorporated collagen films. *Biomaterials*, 25: 1911-1917.
- Hosgood, G., 2003. Wound Repair and Specific Tissue Response to Injury. In: *Textbook of Small Animal Surgery*, Slatter, D. (Ed.). 3rd Edn., WB Saunders, Philadelphia, pp: 327-329.
- James, A.L. and A. Bayat, 2003. Basic plastic surgery techniques and principles: Chronic wound management. *Inter. Med. J. Stud. (Student BMJ)*, 11: 393-436.
- Kawai, K., S. Suzuki, Y. Tabata, Y. Ikada and Y. Nishimura, 2000. Accelerated tissue regeneration through incorporation of basic fibroblast growth factor-impregnated gelatin microspheres into artificial dermis. *Biomaterials*, 21: 489-499.
- Kumar, V., R.S. Cotran and S.L. Robbins, 2003. *Robbins Basic Pathology*. 7th Edn., WB Saunders Co., UK., ISBN: 1416025340, pp: 436-438.
- Mali, S., M.V.E. Grossmann, M.A. Garcia, M.N. Martino and N.E. Zaritzky, 2006. Effects of controlled storage on thermal, mechanical and barrier properties of plasticized films from different starch sources. *J. Food Eng.*, 75: 453-460.
- Menetrey, J., C. Kasemkijwattana, C. Day, P. Bosch and M. Vogt *et al.*, 2000. Growth factors improve muscle healing *in vivo*. *J. Bone Joint Surg. Br.*, 82: 131-139.
- Pope, E.R., 1993. Skin Healing. In: *Disease Mechanisms in Small Animal Surgery*, Bojrab, M.J. (Ed.). 2nd Edn., Lea & Febiger Publisher, Philadelphia, London, pp: 152-155.
- Richard, J.L., J.P. Daures, C. Parer-Richard, D. Vannereau and I. Boulot, 2000. Of mice and wounds: Reproducibility and accuracy of a novel planimetry program for measuring wound area. *Wounds*, 12: 148-154.
- Rubin, E. and J.L. Farber, 1994. *Pathology*. 2nd Edn., L.B. Lippincott Co., New York-Philadelphia, Pages: 1578.
- Schaffer, M.R., U. Tantry and A. Barbul, 2004. Wound fluid inhibits wound fibroblast nitric oxide synthesis. *J. Surg. Res.*, 122: 43-48.
- Takehara, K., 2000. Growth regulation of skin fibroblasts. *J. Dermatol. Sci.*, 24: 70-77.
- Tonnesen, M.G., X. Feng and R.A. Clark, 2000. Angiogenesis in wound healing. *J. Investig. Dermatol. Symp. Proc.*, 5: 40-46.
- Winter, G.D., 1995. Formation of the scab and the rate of epithelisation of superficial wounds in the skin of the young domestic pig. *J. Wound Care*, 4: 368-371.
- Young, S.R. and M. Dyson, 1990. The effect of therapeutic ultrasound on angiogenesis. *Ultrasound Med. Boil.*, 16: 261-269.