

Upregulation of HSP90 in the Tongue Tissue of Rats Exposed to Methyl Methacrylate

Abdalwhab M.A. Zwiri
College of Dentistry, Aljouf University, Sakaka, Aljouf, Saudi Arabia

Abstract: Exposure to Methyl Methacrylate (MMA) has been associated with several adverse effects including sensitivity reactions and inflammations. The objective of the present study was to explore the impacts of exposure to MMA on the tongue tissue of rat. The methodology involved the design of an experimental model of two groups control group (N = 10) and experimental group (N = 10). Experimental group rats received MMA 0.3 mgkg⁻¹ body weight every day for 30 days. After the end of experiment, indirect immunoperoxidase staining was carried out to study the expression of HSP90 in the tongue tissue of all rats. Study findings showed that the exposure of MMA increased significantly (p = 0.001) the expression of HSP90 in the tongue tissue of exposed rats. Taken together, the results of the present study demonstrated molecular impacts due to the exposure of MMA through the upregulation of HSP90 in the tongue tissue of exposed rats.

Key words: Methyl methacrylate, HSP90, upregulation, rat, tongue

INTRODUCTION

Methyl Methacrylate (MMA) is widely used in dentistry as a dental prosthetic and it is considered as one of the contents in acrylic resin of dentures as residual monomer (Keyf and Keyf, 1998). MMA has exhibited the ability to induce various adverse effects including irritation, inflammation and allergic response of the oral mucosa (Giunta *et al.*, 1979; Syed *et al.*, 2015). Other studies reported that MMA has the capability to induce stomatitis and an angular cheilitis (Stoeva *et al.*, 2008; Batchelor and Todd, 2010; Johns *et al.*, 2014).

Side effects associated with the use of MMA have been reported through several studies to include contact dermatitis (Goon *et al.*, 2006; Aalto *et al.*, 2007), respiratory distress (Sokmen and Oktemer, 1988; Gosavi *et al.*, 2010) and cardiovascular effects (Gosavi *et al.*, 2010).

Heat Shock Proteins (HSPs) are a group of synthetic proteins that their levels are elevated as a response to variations in the environmental temperature (Elsaad *et al.*, 2016). HSPs have other physiological functions based on their molecular weight in which HSPs are classified into HSP10, HSP40, HSP70, HSP90 and others (Elsaad *et al.*, 2016). In general terms, HSPs have activities as chaperones and involved in certain cellular functions including protein folding, assembly, controlling cell cycle and offering anti-stress protection (Scheibel and Buchner, 1998).

HSP90 has been found since its discovery to be highly expressed in response to heat stress and it is one of most available proteins, approximately 1-2% of total proteins in eukaryotic cells (Picard, 2002). The HSP90 has two isoforms: inducible HSP90 α and constitutive HSP90 β (Taiyab and Rao, 2011; Young *et al.*, 2001). In their study, Zhang *et al.* (2015) found that HSP90 was highly

expressed in liver cells and in serum as a response to exposure to benzene. The study of Biaoxue *et al.* (2014) found that overexpression of HSP90 in lung cancer compared with control significantly (p<0.05). According to Hojlund *et al.* (2003), the upregulation of HSP90 has been involved in several pathologies including skeletal muscles of diabetic patients, cardiac tissue of diabetic rats (Atalay *et al.*, 2004), atherosclerosis (Kilic and Mandal, 2012) and idiopathic inflammatory myopathies (Paepe *et al.*, 2009).

The tongue has been described to be made mainly of skeletal muscle (Abayomi *et al.*, 2009). The lining mucosal layer of the inferior surface is characterized by being thin, smooth and similar to the remaining parts of the oral cavity. The mucosal layer of the pharyngeal part of the dorsum has lymphoid follicles (Burkih *et al.*, 1993). The tongue has physiological functions including moving food in the mouth, in addition to sensory and secretory functions (Burkih *et al.*, 1993).

The present study was conducted in the light of lack of the studies that targeted the impacts of exposure to MMA on the tongue as a part of oral cavity.

Study objectives: The main objective of the present study is to study the expression of HSP90 in tongue tissue of rats exposed to MMA.

Study question

The main question of the present study is: Does the exposure of rats to MMA induce upregulation of HSP90 in tongue tissue?

Study hypothesis

The main hypothesis of the present study states that: the exposure of rats to MMA does not induce upregulation of HSP90 in tongue tissue.

MATERIALS AND METHODS

Animal preparation: Two groups of Wister rats (N = 10), weighing at average 180 g were chosen randomly and assigned as control group (N = 10) and experimental group (N = 10). One cage was used for each group of animals. We followed standards in treating animals before initiating the experiments so that the two groups of animals were placed in the room where experiments were planned to occur for 1 week and during that time, both groups of animals received standard diet and water. Animals in each group were labeled either “C” for Control or “E” for Experimental group. According to control group, rats were given serial numbers as C1-C10 and in experimental group, rats were given serial numbers as E1-E10.

Experimental model: Experimental group rats received MMA, freshly prepared, 0.3 mg kg⁻¹ body weight every day for 30 days. Rats in control group continued receiving standard diet and water. After 30 days, all animals were scarified using ethylene in certain chambers in which rats were exposed to ethylene soaked cotton for 5 min. Tongues from all rats were removed and placed in labeled containers, filled with 10% formalin for 24 h for fixation.

Immunohisto chemistry: All tongue samples were processed in tissue processor in which several steps from fixation, dehydration and infiltration were completed. Tongue tissues were embedded in paraffin and then cut by rotatory microtome (4 μ thickness) on charged slides.

Indirect immunoperoxidase staining was carried out in tongue tissues. Sections of tongue tissues were deparaffinized through heating slides in an oven at 65°C or 60 min. After that, sections were immersed in xylene for 5 min (2 chnges), then passed through decreasing concentrations of Alcohol (100-70% ethanol) to distilled water. To minimize endogenous peroxidase activity, sections were treated with 3% hydrogen peroxide in methanol for 10 min, then sections were washed in phosphate buffer saline (pH 7.2) for 5 min, then sections were treated with 1% albumin to minimize non-specific reactions for 10 min. To minimize the fixation effect of formalin and expose the tissue antigens for reaction with anti-sera in coming steps, sections were heated using reveal solution (Biocare medical) for 4 cycles using microwave, 2 min each cycle. After that, slides were washed using phosphate buffered saline (pH 7.2). Antibody against HSP90 (Santa cruz biotechnology) was diluted 1:100 and incubated for 1 hr in a humid chamber with tissue sections. After that, slides were washed with phosphate buffered saline (pH 7.2) for 5 min, then treated with biotinylated secondary antibodies for 30 min, washed with phosphate buffered saline (pH 7.2) for 5 min, then

incubated with streptavidin conjugated with horseradish peroxidase enzyme for 30 min, then washed with phosphate buffered saline (pH 7.2) for 5 min. To visualize the reaction, chromogen (diaminobenzidine) with 3% hydrogen peroxide was added for about 3 min to detect the color of reaction as brown at antigenic sites. After that, slides were washed with tab water to stop the reaction, stained with hematoxylin as a counter stain for 30 seconds, then dehydrated through increasing concentrations of alcohol (70-100% ethanol).

Interpretation of the results: Slides were assessed using Adopyphotoshop Software Version 7.2. Photos for sections were taken and divided into pixels. The total number of pixels was computed and represented both colors (blue and brown), then the brown color (the color of the marker under study) was computed and divided by the total number of pixels (Al-Khatib, 2013). The expression of HSP90 was compared between groups using independent t-test. p<0.05 was considered statistically significant.

RESULTS AND DISCUSSION

Expression of HSP90 in control and experimental group. As seen in Table 1 and Fig. 1 the expression rate of HSP90 in control group and experimental groups were demonstrated and showed that the average expression rate for HSP90 was 0.0520 and that for experimental group was 0.1037. The statistical significance of the expression of HSP90 between experimental and control groups. As

Table 1: The expression rate of HSP90 in experimental and control groups

| Control group | Experimental group |
|---------------|--------------------|
| 0.02 | 0.080 |
| 0.04 | 0.150 |
| 0.03 | 0.098 |
| 0.05 | 0.120 |
| 0.09 | 0.089 |
| 0.01 | 0.078 |
| 0.04 | 0.096 |
| 0.06 | 0.099 |
| 0.08 | 0.670 |
| 0.10 | 0.160 |

Average expression rate = 0.0520; 0.1037

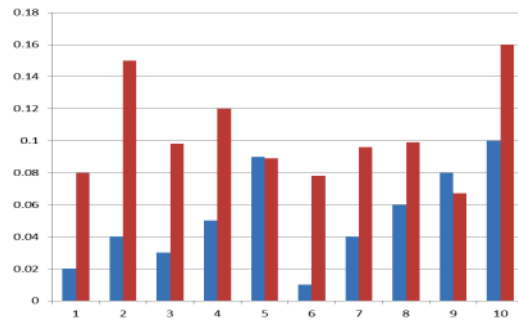


Fig. 1: The expression of HSP90 for each rat in study groups

Table 2: The expression of HSP90 in experimental and control groups

| Groups | Expression | | F-value | t-value | df | Confidence interval at 95% | | p-values |
|--------------------|------------|---------|---------|---------|----|----------------------------|--------|----------|
| | M | SD | | | | Lower | Upper | |
| Control group | 0.0520 | 0.03011 | 0.007 | -3.802 | 18 | -0.080 | -0.023 | 0.001 |
| Experimental group | 0.1037 | 0.03069 | | | | | | |

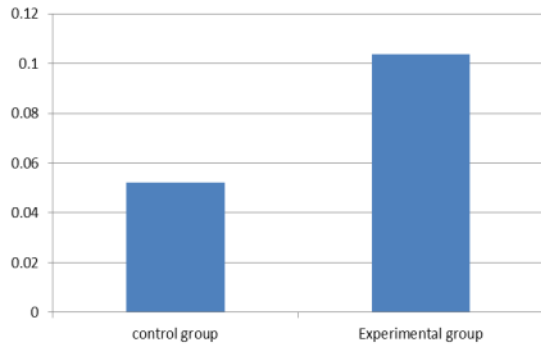


Fig. 2: The average expression rate of HSP90 in control and study group

seen in Table 2 and Fig. 2, the expression of HSP90 in control group was 0.0520 ± 0.0301 and the expression of HSP90 was further increased due to the exposure of MMA (0.1037 ± 0.03069). This variation in expression was statistically significant, based on independent t-test, ($F = 0.007$; $T = -3.802$, $df = 18$; $p = 0.001$).

The present study was conducted to explore the impacts of exposure to MMA. Exposure to MMA has been shown to widely among population either as patients or as workers (Keyf and Keyf, 1998). Because of the exposure to MMA is usually via the oral activity or nasal routes, the tongue was selected to be studied in the present study since it has a good mobile size which gives a relatively good exposure.

The results of the present study showed that exposure to MMA induced upregulation of HSP90 in tongue tissue significantly compared with control group ($p = 0.001$). Accordingly, the study hypothesis “the exposure of rats to MMA does not induce upregulation of HSP90 in tongue tissue” is rejected and the alternative hypothesis “the exposure of rats to MMA induces upregulation of HSP90 in tongue tissue” is accepted.

Although, the exposure to MMA has been associated with various adverse effects as mentioned previously, no previous studies, up to the best knowledge of researcher, have been reported in literature to describe the expression of HSP90 in the tongue of MMA exposure in rats.

Because the overexpression of HSP90 has been described in various pathological conditions such as the exposure to benzene (Zhang *et al.*, 2015), lung cancer (Biaoxue *et al.*, 2014) and others, we think that the assessment of HSP90 levels would benefit patients, particularly those involved in dental laboratories and dental patients.

CONCLUSION

The results of the present study demonstrated molecular impacts due to the exposure of MMA through the upregulation of HSP90 in the tongue tissue of exposed rats.

REFERENCES

- Aalto, K.K., K. Alanko, O. Kuuliala and R. Jolanki, 2007. Methacrylate and acrylate allergy in dental personnel. *Contact Dermatitis*, 57: 324-330.
- Abayomi, T.A., D.A. Ofusori, O.A. Ayoka, S.A. Odukoya and E.O. Omotoso et al., 2009. A comparative histological study of the tongue of rat (*Rattus norvegicus*), bat (*Eidolon helvum*) and pangolin (*Manis Tricuspis*). *Int. J. Morphol.*, 27: 1111-1119.
- Al-khatib, A., 2013. Co-expression of inos and hsp70 in diabetes type 1 makes a rational hypothesis to explain the diabetic neuropathy. *Eur. Sci. J.*, 9: 145-156.
- Atalay, M., N.K. Oksala, D.E. Laaksonen, S. Khanna and C. Nakao et al., 2004. Exercise training modulates heat shock protein response in diabetic rats. *J. Appl. Physiol.*, 97: 605-611.
- Batchelor, J.M. and P.M. Todd, 2010. Allergic contact stomatitis caused by a polyether dental impression material. *Contact Dermatitis*, 63: 296-297.
- Biaoxue, R., Y. Shuanying, L. Wei, M. Zongjuan and C. Xiguang et al., 2014. Co-overexpression of Hsp90-β and annexin A1 with a significantly positive correlation contributes to the diagnosis of lung cancer. *Expert Rev. Mol. Diagn.*, 14: 1067-1079.
- Burkitt, H.G., B. Young and J.W. Heath, 1993. *Oral Tissues. Wheaters Functional Histology: A Textbook and Color Atlas*. 3rd Edn., Churchill Livingstone, Edinburgh, Scotland, Pages: 235.
- Elsaad, A.N.M., M.S. Serrya, E.A.M. Karefa and T.M. Ibrahim, 2016. The heat shock protein 90 inhibitor, 17-AAG, attenuates thioacetamide induced liver fibrosis in mice. *Pharmacol. Rep.*, 68: 275-282.
- Giunta, J.L., I. Grauer and N. Zablotsky, 1979. Allergic contact stomatitis caused by acrylic resin. *J. Prosthetic Dent.*, 42: 188-190.
- Goon, A.T., M. Isaksson, E. Zimerson, C.L. Goh and M. Bruze, 2006. Contact allergy to (meth) acrylates in the dental series in southern Sweden: Simultaneous positive patch test reaction patterns and possible screening allergens. *Contact Dermatitis*, 55: 219-226.

- Gosavi, S.S., S.Y. Gosavi and R.K. Alla, 2010. Local and systemic effects of unpolymerised monomers. *Dent. Res. J.*, 7: 82-87.
- Højlund, K., K. Wrzesinski, P.M. Larsen, S.J. Fey and P. Roepstorff et al., 2003. Proteome analysis reveals phosphorylation of ATP synthase β -subunit in human skeletal muscle and proteins with potential roles in type 2 diabetes. *J. Biol. Chem.*, 278: 10436-10442.
- Johns, D.A., S. Hemaraj and R.K. Varoli, 2014. Allergic contact stomatitis from bisphenol-a-glycidyl dimethacrylate during application of composite restorations: A case report. *Indian J. Dent. Res.*, 25: 266-268.
- Keyf, F.A. and A.I. Keyf, 1998. Harmful effects of methylmethacrylate and formaldehyde from acrylic resin denture base materials. *Saudi Dent. J.*, 10: 23-28.
- Kilic, A. and K. Mandal, 2012. Heat shock proteins: Pathogenic role in atherosclerosis and potential therapeutic implications. *Autoimmune Dis.*, 2012: 1-10.
- Paeppe, D.B., K.K. Creus, J.J. Martin, J. Weis and D.J.L. Bleecker, 2009. A dual role for HSP90 and HSP70 in the inflammatory myopathies. *Ann. N. Y. Acad. Sci.*, 1173: 463-469.
- Picard, D., 2002. Heat-shock protein 90, a chaperone for folding and regulation. *Cell. Mol. Life Sci.*, 59: 1640-1648.
- Scheibel, T. and J. Buchner, 1998. The Hsp90 complex-a super-chaperone machine as a novel drug target. *Biochem. Pharmacol.*, 56: 675-682.
- Sokmen, S. and M. Oktemer, 1988. Histopathological examinations of rat lungs that exposed to low concentration of methylmethacrylate monomer vapor. *J. Hacettepe Fac. Dent.*, 12: 1-4.
- Stoeva, I., A. Kisselova and M. Zekova, 2008. Allergic contact stomatitis from bisphenol-a-glycidyl dimethacrylate during application of composite restorations: A case report. *J. IMAB. Ann. Proc. Sci. Pap.*, 2: 45-46.
- Syed, M., R. Chopra and V. Sachdev, 2015. Allergic reactions to dental materials-a systematic review. *J. Clin. Diagn. Res. JCDR.*, 9: ZE04-ZE09.
- Taiyab, A. and C.M. Rao, 2011. HSP90 modulates actin dynamics: Inhibition of HSP90 leads to decreased cell motility and impairs invasion. *Biochim. Biophys. Acta BBA. Mol. Cell Res.*, 1813: 213-221.
- Young, J.C., I. Moarefi and F.U. Hartl, 2001. Hsp90: A specialized but essential protein-folding tool. *J. Cell Biol.*, 154: 267-273.
- Zhang, J., K. Tan, X. Meng, W. Yang and H. Wei et al., 2015. Overexpression of G6PD and HSP90 Beta in mice with benzene exposure revealed by serum peptidome analysis. *Int. J. Env. Res. Public Health*, 12: 11241-11253.