

Splenic Hydatid Cyst and Relevation with Anaphylaxis

M.A.M. Mokhtari and A. Spoutin

Department of Parasitology and Surgical Research Center,
Mashhad University of Medical Sciences, Mashhad, Iran

Abstract: A 75-year-old farmer was brought to the emergency of Ghaem Hospital, Mashhad in a collapsed state with three day's history of abdomen pain. He was resuscitated and placed on ventilator. While the rest of examinations were normal, ultrasound examination of the abdomen revealed a cystic mass in spleen most likely to be hydatid. The patient was fully conscious the next day and was put on tab albendazole (180 mg BID). CT scan of the abdomen revealed a large cystic mass having inner undulating wall with watery content diagnosed as hydatid cyst in spleen. Since, anaphylaxis was considered consequent to hydatid cyst perforation, surgery was carried out. Approximately, 160 mL of haemorrhagic fluid was aspirated and 10% hypertonic saline instilled. After re-aspiration, cyst cavity was opened and endocyst completely removed. Portion of ectocyst projecting away from the spleen edge was also excised. He made an uneventful postoperative recovery and was discharged with the advice to continue tab albendazole 180 mg BID for four weeks and weekly follow-up in surgical OPD. He is doing well now. At finally we present a rare case of a primary hydatid cyst of the spleen with anaphylaxis symptoms that was detected incidentally. Splenectomy was the procedure advocated.

Key words: Anaphylaxis, splenectomy, hydatid cyst, echinococcus granulosus

INTRODUCTION

Hydatid disease caused by the genus *Echinococcus* is endemic in Middle East, South America, North Africa and Indian subcontinent, Australia, New Zealand and Iran. *Echinococcus granulosus* is the commonest organism involved, with dogs as the definitive host and human beings acting as an accidental intermediate host. Rarely affected organs are the spleen and the kidney. Morbidity is usually secondary to free rupture of the echinococcal cyst with or without anaphylaxis, infection of the cyst or dysfunction of affected organs. The cyst of *Echinococcus granulosus* is commonly located in the liver and frequently causes no symptoms. Clinical examination is unreliable in making the diagnosis. Serological testing has a broad range of sensitivity and specificity and is dependent on the purity of the antigens utilized. Ultrasonography is the imaging modality of choice particularly in hepatic disease. CT best demonstrates cyst wall calcification and cyst infection. Spleen hydatid cysts can be treated by medical or minimally invasive (laparoscopic and percutaneous) means or by conventional open surgery. Anaphylactic reactions as a result of cyst perforation generally occur during interventions such as needle aspiration or open surgery; however, the spillage of cyst fluid with intravascular spread resulting from trauma may also

trigger anaphylaxis. There are instances of anaphylactic shock as the single presentation of hydatid disease of the spleen. In this study we present a very rare case of splenic hydatid disease, which presented as anaphylactic shock.

Case report: A 75 year-old farmer was brought to intensive care unit of Ghaem Hospital, Mashhad in a collapsed state. He had come to the radiology department to collect his report of chest X-rays where he collapsed. He was resuscitated and put on ventilator with ionotropic support. Clinical examination of the patient did not reveal a positive clinical finding. He was extubated the same day after 3 1/2 h. His initial ECG revealed Q3, T wave inversion in lead III, ST segment depression in V1-V4 Echocardiography and chest radiograph were within normal limits, though cardiac enzymes showed abnormality. Serum CPK was 864 u L⁻¹ and CKMB 93 u L⁻¹. PT and PTTK were within normal limits. Routine investigation revealed: hemoglobin 11.1 g dL⁻¹, total leukocyte count 11.800 mm⁻³ and differential leukocyte count: neutrophils 67%, lymphocytes 21%, eosinophils 40%, monocytes 2%, basophils 2%. Renal and liver function tests were within normal limits. Plain radiological imaging of the abdomen revealed a well-defined, rounded soft-tissue opacity with calcified margins in the left hypochondrium (Fig. 1).

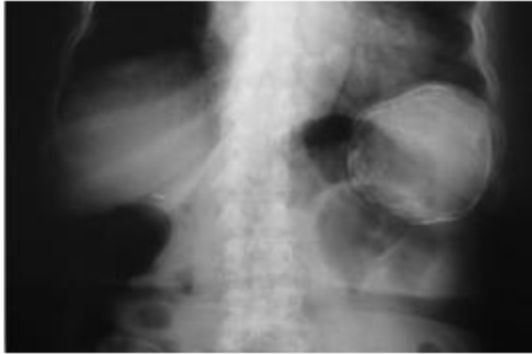

Fig. 1: Plain x-ray of the abdomen revealing a well-defined rounded soft-tissue opacity with calcified margins in the left hypochondrium

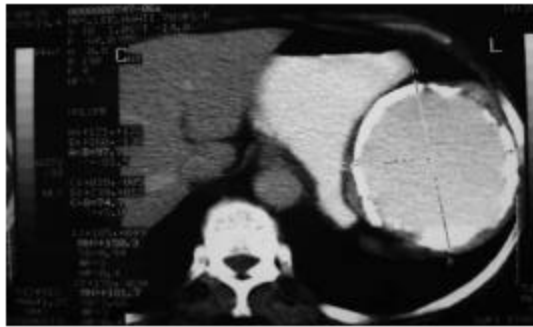


Fig. 2: CT scan of the abdomen showing a well-defined rounded mass with dense calcification in the superior pole of the spleen

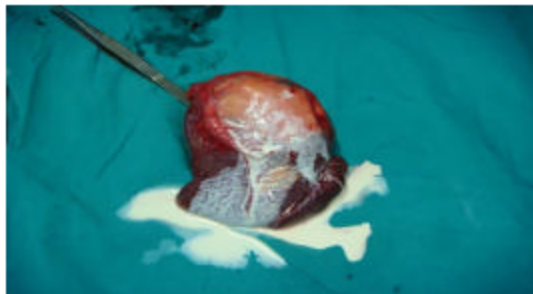


Fig. 3: Specimen of infected hydatid cyst of the spleen with abscess

Contrast-enhanced computed tomography of the abdomen showed a well-defined rounded mass with dense calcification in the superior pole of the spleen suggestive of old calcified cyst or abscess (Fig 2).

Surgical exploration was planned which revealed an infected hydatid cyst of the spleen with abscess formation (Fig 3).

It had a cyst within cyst appearance, most likely to be hydatid. The patient was fully conscious the next day and was put on tab albendazole (180 mg BID). CT scan of the abdomen was carried out (Fig 2). It revealed a large cystic mass measuring 9.0×6.3 cm in segments 5 and 6. This mass had inner undulating wall with watery content. Conservative management for the hydatid continued. It was opined that anaphylaxis was consequent to hydatid cyst perforation. Therefore, surgery was planned. This cyst occupied full of spleen. It was projecting on the visceral surface. Packs soaked in 10% hypertonic saline were placed around the swelling. Approximately 160 mL of haemorrhagic fluid was aspirated and was refilled with 10% hypertonic saline. After reaspiration, cyst cavity was opened and endocyst completely removed. Portion of ectocyst projecting away from liver edge was also excised. The patient made an uneventful postoperative recovery and was discharged on 4th postoperative day with the advice to continue tab albendazole 180 mg BID for 4 weeks and followed-up weekly in surgical OPD for 5 weeks. Stitches were removed on 7th postoperative day. It is more than 5 months now and the patient is symptom and sign-free with negative serology and ultrasound.

DISCUSSION

Splenic hydatid disease is rare and the incidence is reported between 2-3.5% by different authors. Primary infestation of the spleen usually takes place by the arterial route after the parasite has passed the two filters (hepatic and pulmonary). A retrograde venous route, which bypasses the lung and liver, is also reported. Secondary splenic hydatid disease usually follows systemic, disseminated or intraperitoneal spread following ruptured hepatic hydatid cyst (Franquet *et al.*, 1990; Uriarte *et al.*, 1991; Ionescu *et al.*, 1990; Kiresi *et al.*, 2003; Jahani *et al.*, 2004).

Severe anaphylactic reactions due to rupture of the cyst are also reported leading to fever, pruritus, dyspnea, stridor and edema of the face. Portal hypertension is also described with splenic hydatidosis (Franquet *et al.*, 1990; Singh and Arora, 2003; Elfortia *et al.*, 2000; Alba and Arribas, 1996).

The main differential diagnoses of splenic hydatidosis are splenic cystic lesions such as pseudocyst, abscess, haematoma and cystic neoplasm (Singh and Arora, 2003).

Hydatids or watery cysts have been seen in animals and humans since ancient times. Following the death of the patient, an autopsy disclosed lesions characteristic of a condition, eventually labeled as echinococcosis

of the liver"-today one of the most common parasitic diseases in sheep raising regions of the world. The larval stages of *Echinococcus granulosus* are organs cystic echinococcosis (CE or "hydatid disease"). This disease have tight links with allergic response because of the immunological characteristics that contribute to maintain the larvae in their human host as well as their potential in inducing clinical anaphylactic reactions in some patients. Clinical observations in patients and data obtained from mass screenings in various countries have identified this disease as "polar disease," i.e., disease where immunological background of the patients was related to the clinical presentation and course. In particular, abortive cases (i.e., spontaneous cures) have been found in many subjects in endemic areas. On the other hand, immune suppression was associated with severe disease. Experimental and clinical studies have shown that Th1-related immune response was associated with protection and Th2-related response was associated with parasite growth. Anaphylactic reactions, including urticaria, edema, respiratory symptoms and anaphylactic shock due to spontaneous or provoked rupture of the parasitic cyst, are well known in cystic echinococcus. *Echinococcus*-specific IgE is present in most of the patients and associated with severity. Specific histamine release by circulating basophils stimulated with *E. granulosus* antigens is present in all patients with CE.

However, despite the potential risk of allergic reactions, the dogma "never puncture a hydatid cyst" is no longer valid. International experience of therapeutic technique of "puncture, aspiration, injection, re-aspiration" of hydatid cysts developed at the beginning of the 1980s has proved to be successful in a variety of selected indications that have been reviewed by WHO recommendations. A better understanding of the immunological background of echinococcosis in humans has led to new therapeutic developments, such as immunomodulation using interferon alpha.

Otherwise, the main complications are infection, biliary duct fistula and rupture into the peritoneum or chest. Diagnosis has become easier with ultrasonic imaging and CT scanning. Surgery remains the most effective treatment but postoperative complications arise in 30% of cases, particularly when the surgical approach

is conservative. Radical surgical approaches give better results and should be used in most cases. Biliocutaneous fistula and infection of the residual cavity are the most common postoperative complications and result in prolonged hospitalization and excess costs. New therapeutic strategies incorporate endoscopic, percutaneous and medical therapies with surgery and have led to improvement in morbidity and mortality. Until immunization becomes a possibility, preventive measures are necessary to avoid disease recurrence (Sakhri *et al.*, 2004; Sayek *et al.*, 2004).

REFERENCES

- Alba, D. and P. Arribas, 1996. Splenothoracic fistula complicating primary splenic hydatidosis. *Thorac. Cardiovasc. Surg.*, 111: 1103-1104.
- Elfortia, M. *et al.*, 2000. Segmental portal hypertension due to a splenic echino cyst. *Eur. J. Ultrasound.*, 11: 21-23.
- Franquet, T., M. Montes, F.J. Lecumberri, J. Esparza and J.M. Bescos, 1990. Hydatid disease of the spleen: imaging findings in nine patients. *Am. J. Roentgenol.*, 154: 525-528.
- Ionescu, A., A. Jakab, T. Jutis, F. Forai and A. Ota, 1990. Splenic hydatid cyst (Article in Romanian). *Rev. Med. Chir. Soc. Med. Natl. Iasi.*, 94: 525-528.
- Jahani, M.R., G. Roohollahi and M.J. Gharavi, 2004. Splenic Hydatid Cysts in a 20-Year-Old Soldier. *Military Med.*, 169: 77-78.
- Kiresi, D.A., A. Karabacakoglu, K. Odev and S. Karakoese, 2003. Uncommon Locations of Hydatid Cysts. *Acta Radiol.*, 44: 622.
- Sakhri, J. and A. Ben Ali, 2004. Hydatid cyst of the liver. *J. Chir. (Paris)*, 1: 381-389.
- Sayek, I., M.B. Tirmaksiz and R. Dogan, 2004. Cystic hydatid disease: Current trends in diagnosis and management. *Surg. Today*, 34: 987-996.
- Singh, C.H. and M.S. Arora, 2003. Primary Hydatid Cyst of the Spleen. *MJAFL.*, 59: 169-170.
- Uriarte, C., N. Pomares, M. Martin, A. Conde, N. Alonso and A. Bueno, 1991. Splenic hydatidosis. *Am. J. Trop. Med. Hyg.*, 44: 420-423.