

## Association of *Schistosoma mansoni* with Infertility in a Sudanese Patient from Schistosomiasis Area of Endemicity: A Case Report

<sup>1</sup>E. Tayrab, <sup>2</sup>A.K. Ashmaig, <sup>3</sup>H. Shareef, <sup>4</sup>S.B. Bedawi and <sup>5</sup>I.E. Aradaib

<sup>1</sup>Department of Chemical Pathology, Faculty of Medical Laboratory Sciences,

<sup>2</sup>Department of Obstetrics and gynecology, Faculty of Medicine,

<sup>3</sup>Department of Parasitology, The National Ribat University, P.O. Box 55, Khartoum, Sudan

<sup>4</sup>Department of Andrology, Reproductive Health Care Center, Khartoum Sudan

<sup>5</sup>Molecular Biology Laboratory, Faculty of Veterinary Medicine, P.O. Box 32, Khartoum North, Sudan

---

**Abstract:** Schistosomiasis is a chronic debilitating infection of humans and animals and hence the disease is of a public health importance. In the present study, a male farmer from Barakat of the Gezera State, a schistosomiasis endemic area in Central Sudan was admitted to the Reproductive Health Care Center (RHCC) in Khartoum, Sudan. The patient complains of history of primary infertility for 18 years with complain of painful ejaculation, he had several semen analysis, all showed a picture of azoospermia and no sperm was detected neither in the sample nor in the pellet after centrifugation. On genital examination both testes are of average size, enlargement of epididymis on both sides vasa differences were present in both sides. Semen analysis showed that the semen was turbid, infiltrated with inflammatory cells. Hence, the patient was diagnosed with infertility due to azoospermia. In addition, numerous *Schistosoma mansoni* eggs were detected in the semen pellet. This study suggested that physician should consider *schistosoma mansoni* as a cause of male infertility in schistosomiasis endemic areas.

**Key words:** Schistosomiasis, male infertility, semen evaluation, azoospermia, inflammatory cells, Sudan

---

### INTRODUCTION

Human schistosomiasis caused by *Schistosoma mansoni* is one of the major public health problems in many parts of the world including the Sudan (Aradaib *et al.*, 1995; Aradaib and Osburn, 1995; Aradaib *et al.*, 1993). In endemic areas of the Gezera State and the White Nile Province of the Sudan, the prevalence rate of the infection is very high as judged by fecal egg counts. Monthly incidence rates estimated from fecal examinations of initially uninfected individuals showed a marked seasonal pattern with the infection level being much higher in the rainy months. This coincided with a high snail infection rate (Majid *et al.*, 1980).

In the vicinity of Khartoum, internal parasitic infections including *S. mansoni* were diagnosed in Khartoum Hospital. This constitutes a newly reported focus of the disease. In general, the prevalence of schistosomiasis increases in areas where development in agriculture and industry depends on construction of new dams and irrigation canals which provide a suitable habitat for the snail intermediate host, the *Bulinus* and *biomphalaria* sp. Therefore, it is not surprising for the

disease to be encountered in the vicinity of Khartoum as there is growing irrigated projects. Special attention has been paid to the control of the disease in the Sudan (Hussien, 1968). The control of contaminated water and/or destruction of the snail intermediate host were impractical and not economical (Bushara *et al.*, 1978). In spite of the development of effective and relatively safe drugs, prevention of rapid reinfection has remained a problem which requires repeated drug applications over a long period of time. Partial protection develops following prior exposure to *S. mansoni* (Hussien, 1968). This indicates that vaccination could be a feasible and effective method for limiting the extent of pathology and level of transmission (Aradaib *et al.*, 1995; Bushara *et al.*, 1978).

A lot of research effort has been directed to study the infertility in males caused by *S. Hematobium*. However, the literature on infertility due to *S. mansoni* is scanty and a few reports are available on the role of this parasite as a cause of infertility in Sudanese patients living in schistosomiasis endemic areas (Saad *et al.*, 1999). It was suggested that schistosomiasis of the reproductive organs is unlikely to induce male infertility in some

African countries (Patil and Elem, 1988; Pereira *et al.*, 1997; Oqubanio *et al.*, 1989). However, in the presented case, a large number of *Schistosoma mansoni* eggs were demonstrated in the semen sample of the patient and were associated with azoospermia.

## MATERIALS AND METHODS

**Case presentation:** A 48 years old male farmer was visited the Reproductive Health Care Center (RHCC) in Khartoum, Sudan. The farmer was complaining of primary infertility for 18 years associated with severe painful ejaculation. He was referred to the RHCC clinic for semen evaluation. A total volume of 2 mL semen was collected for semen evaluation and other diagnostic laboratory investigations. Semen analysis indicated that no sperms were seen in the semen sample and hence the patient was diagnosed with azoospermia. Microscopic examination revealed the presence of a trematode parasite eggs with lateral spine, characteristic of *Schistosoma mansoni* egg. Urine analysis showed that the urine sample was clear. Fecal examination revealed increased pus cells, red blood cells and mucous. However, schistosome eggs were not detected neither in the urine nor in the faeces. Reproductive hormones including serum prolactin, Follicle Stimulating Hormone (FSH) and Luteinizing Hormone (LH) indicated that the values were within the normal limits.

## RESULTS AND DISCUSSION

*Schistosoma mansoni* is one of the most abundant parasitic infections in the areas of construction of new dams and irrigation projects (Fig. 1). Schistosomiasis is a disease of public health importance in many African countries including the Sudan (Aradaib *et al.*, 1995; Hussien, 1968; Bushara *et al.*, 1978). Depending on the species, schistosome adults migrate to various organ-specific venous plexuses. *S. haematobium* migrates to urinary bladder venous plexus where as *S. mansoni* migrates to the mesenteric vessels (Connor *et al.*, 1997). Owing to the extensive anastomoses among the venous plexuses of the pelvic organs, *S. haematobium* and to a lesser extent, *S. mansoni* is the organism most often identified in genital organs in females (Feldmeier *et al.*, 1995; Helling-Giese *et al.*, 1996; Poggensee *et al.*, 1999).

The 2-3 cm adult worms may cause venous obstruction where they reside. The pathology is more commonly caused by the daily deposition of numerous eggs by the female which induces a localized host response and can lead to extensive tissue damage (Koneman *et al.*, 1997; Connor *et al.*, 1997). Live schistosome eggs excretion in feces or urine begins the

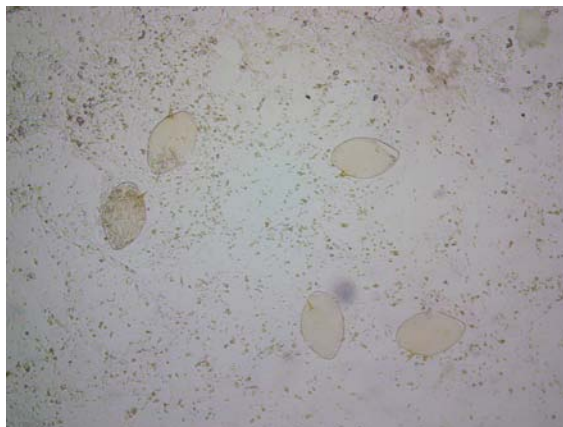


Fig. 1: Demonstration of *Schistosoma mansoni* eggs in semen sample from the patient with infertility

life cycle again (Morgan *et al.*, 2001). Schistosomiasis has been suggested to decrease the reproductive potential or castrate both invertebrate and vertebrate hosts. Furthermore, schistosomiasis may cause anatomic anomalies of the reproductive organs responsible for permanent or reversible infertility (Saad *et al.*, 1999). Urinary schistosomiasis is caused by *Schistosoma haematobium* which affects in a diffuse manner all the genitourinary tract (Pereira *et al.*, 1997). In earlier studies, it has been reported that schistosome eggs were demonstrated in the tissue of prostate and seminal vesicles in histological samples (Patil and Elem, 1988; Connor *et al.*, 1997).

The presence of the parasite eggs in tissues will probably lead to destruction of the reproductive organs or even degeneration of the germinal epithelium; thus resulting in permanent infertility in males. The seminal vesicles and the prostate are frequently affected by egg-induced inflammation in *Schistosoma haematobium* infected men. The present study demonstrated that egg excretion caused by *S. mansoni* infection is associated with sperm apoptosis and reduced production of seminal fluid. Egg induced inflammation in the seminal vesicles and the prostate could be the reason for reduced semen volume and apoptosis could be the reason for azoospermia.

## CONCLUSION

In the present study, an unusual case of schistosomiasis was reported in a male farmer from Barakat of the Gezera State, Central Sudan. The patient was admitted to the Reproductive Health Care Center (RHCC) in Khartoum, Sudan for infertility problems. The patient was diagnosed with infertility due to azoospermia. Surprisingly, numerous *Schistosoma mansoni* eggs were

demonstrated in the semen of the infected patient and were associated with painful ejaculation. This study suggests that *Schistosoma mansoni* should be considered as a cause of male infertility in schistosomiasis endemic areas.

## REFERENCES

- Aradaib, I.E. and B.I. Osburn, 1995. Evaluation of a recombinant *Schistosoma mansoni* 28-Kilodalton antigen for vaccination of zebu calves against *S. bovis* infection. *Vaccine*, 13: 130-131.
- Aradaib, I.E., B. Abbas, H.O. Bushara and M.G. Taylor, 1993. Evaluation of *Schistosoma bovis* adult worm extract for vaccination of calves. *Preventive Vet. Med.*, 16: 77-84.
- Aradaib, I.E., H.O. Omer, B. Abbas, H.O. Bushara and K.H. Elmalik *et al.*, 1995. *Schistosoma bovis* whole-egg antigen did not protect zebu calves against experimental schistosomiasis. *Preventive Vet. Med.*, 21: 339-345.
- Bushara, H.O., M.F. Hussien, A.M. Saad, M.G. Taylor, J.D. Dargie, T.E. Marshal and G.S. Nelson, 1978. Immunization of calves against *Schistosoma bovis* using irradiated cercariae or schistosomula of *S. bovis*. *Parasitology*, 77: 303-311.
- Connor, D.H., F.W. Chandler and D.A. Schwartz, 1997. Schistosomiasis, in *Pathology of Infectious Diseases*. Appleton and Lange, Stamford, CT, pp: 1537-1551.
- Feldmeier, H., G. Poggensee, I. Krantz and G. Helling-Giese, 1995. Female genital schistosomiasis: New challenges from a gender perspective. *Trop. Geogr. Med.*, 47: S2-S15.
- Helling-Giese, G., E.F. Kjetland, S.G. Gundersen, G. Poggensee, J. Richter, I. Krantz and H. Feldmeier, 1996. Schistosomiasis in women: Manifestations in the upper reproductive tract. *Acta Trop.*, 62: 225-238.
- Hussien, M.F., 1968. The pathology of natural and experimental bovine schistosomiasis. *Trans. R. Soc. Trop. Med. Hyg.*, 62: 9-12.
- Koneman, E.W., S.D. Allen and W.M. Janda, 1997. *Parasitology: Blood and Tissue Parasites*, in *Color Atlas and Textbook of Diagnostic Microbiology*. 5th Edn., Lippincott Williams and Wilkins, Philadelphia, pp: 1111-1119.
- Majid, A.A., H.O. Bushara, A.M. Saad, M.F. Hussien and M.G. Taylor *et al.*, 1980. Field testing of an irradiated *Schistosoma bovis* vaccine. *Am. J. Trop. Med. Hyg.*, 29: 452-455.
- Morgan, J.A., R.J. DeJona, S.D. Synder, G.M. Mkoi and E.S. Loker, 2001. *Schistosoma mansoni* and *biophalaria*: Past history and future. *Parasitology*, 123: S211-S228.
- Oqubanio, B.O., A.O. Osob and J. Ochei, 1989. Infective factors of male infertility among Nigerian. *Afr. J. Med. Med. Sci.*, 18: 35-38.
- Patil, P.S. and B. Elem, 1988. Schistosomiasis of prostate and seminal vesicles: Observations in Zambia. *J. Trop. Med. Hyg.*, 91: 245-248.
- Pereira, A.J.G., I.J.G. González, A.J.A. Martínez, M.M. Fernández, G.J.A. Sánchez, L.J. Simón and B.C. Malfaz, 1997. Mixed urogenital schistosomiasis. *Actas Urológicas Españolas*, 21: 272-277.
- Poggensee, G., H. Feldmeier and I. Krantz, 1999. Schistosomiasis of the female genital tract: Public health aspects. *Parasitol. Today*, 15: 378-381.
- Saad, A.H., A. Abdella, A.M. Osman, K.F. Abdalla and D. Salem, 1999. Possible role of *Schistosoma mansoni* infection in male hypogonadism. *J. Egypt. Soc. Parasitol.*, 29: 307-323.