

Contributing in the Identification of Missing Children: The Dentist's Role

¹C. Stavrianos, ²P. Kafas, ¹H. Katsikogiani, ¹G. Tretiakov and ¹A. Kokkas

¹Department of Endodontology, Forensic Dentistry, ²Department of Oral Surgery and Radiology, School of Dentistry, Aristotle University, Thessalonica, Greece

Abstract: Missing children is a multi-dimensional problem with raising percentages of children and young people that become missed lately. This fact has led all the relevant authorities to more coordinated efforts in order to facilitate the investigations and support the parents. Additionally in these procedures forensic odontology can play a very important role by the means that are now available. Parents in cooperation with their dentist can collect child's individual data by recording dental radiographs, facial photographs, studying casts, dental histories, teeth present, distinguishing features of oral structures and bite registrations. Toothprints, a trademarked product is an arch-shaped thermoplastic dental impression wafer which depicts child's individual characteristics. In addition collection of saliva DNA and engraving of serial number in their teeth can aid in the identification of a missing child. The Dentist is obliged by the law to provide copies of all the Dental Records in case of a missing child. A detailed dental record, updated at recall appointments, establishes an excellent database of confidential, state-of-the-art child identification information that can be retrieved easily stored safely and updated properly. The American Academy of Paediatric Dentistry (AAPD), recognizing the role that dental records play in forensic identification, encourages dental practitioners and administrators of child identification programs to implement simple practices that can aid in the investigation and identification of missing and unknown infants, children and adolescents.

Key words: Missing children, child identification program, antemortem dental records, toothprints, saliva DNA, identification, forensic dentistry

INTRODUCTION

Missing children is a complex and multifaceted problem. When we are referring to a missing child we mean a child whose whereabouts are unknown to the child's custodian and the circumstances of whose absence indicate that:

- The child did not leave the care and control of the custodian voluntarily and the taking of the child was not authorized by law
- The child voluntarily left the care and control of his or her custodian without the custodian's consent and without intent to return (<http://www.amber-net.org>)

However, many cases of abduction by a family member have been recorded. Today missing children is a phenomenon that has many dimensions and is in bulge lately (Fig. 1). Statistics confirm this statement.

In particular, according to the best national estimates for the number of missing children that

are found in the national incidence studies of missing, abducted, runaway and thrown away children:

- About 800,000 children younger than 18 are missing each year or an average of 2,000 children reported missing each day
- About 200,000 children were abducted by family members
- About 58,000 children were abducted by nonfamily members
- Only 115 children were the victims of stereotypical kidnapping (Sedlak *et al.*, 2002)

As far as Europe is concerned in the UK 140 cases of missing children are reported annually which corresponds to >383 cases day⁻¹ whereas in Belgium, the incidence comes up to an average of 8 new cases day⁻¹. Also Romania is one of the European countries which suffer most from this phenomenon and has >350 cases opened in a period of 6 months in the year 2007 according to the statistics provided by the European centre of missing and exploited children.

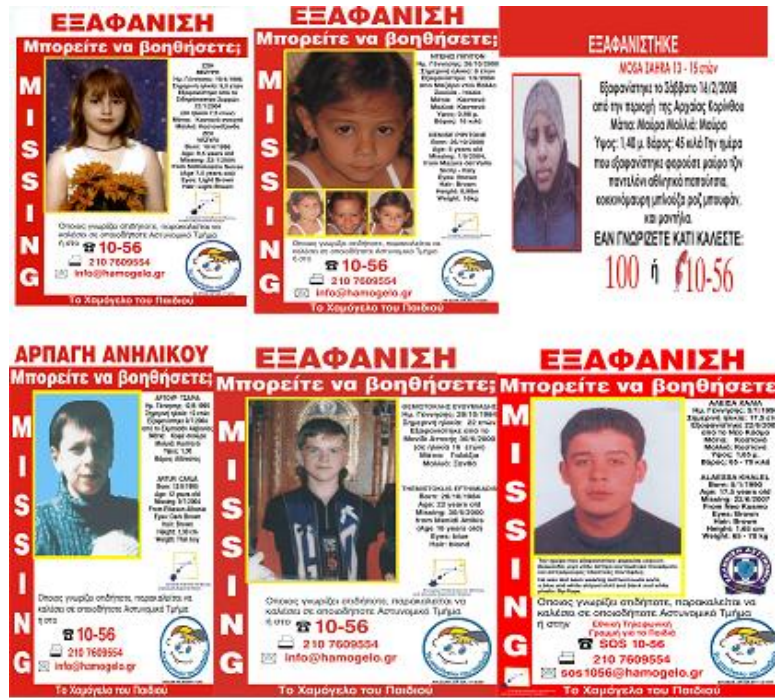

Fig. 1: Missing children (<http://www.hamogelo.gr>)

MATERIALS AND METHODS

Every day we are swamping of announcements of missing children in the mass media in mass transport, stations in milk packages, etc. Statistics referring to this phenomenon despite the fact that are really shocking and alarming they are just numbers. We can consider the real dimensions of this problem only by corresponding these figures to human lives.

For this reason there have been established many organizations in order to aid in the investigations of these cases with worldwide cooperation offering eventually great social service. The European Federation for Missing and Sexually Exploited Children, The National Centre of Missing and Exploited Children, The International Centre for Missing and Exploited Children as well as The Smile of the Child are different organizations which aid to this direction.

How can parents prepare themselves in case their child becomes missed?: The National Centre of Exploited and Missing Children provide a number of actions for the parents in case their children become missed. According to this report:

- Keep a complete description of your child on hand
- Take colour photographs of your child every 6 months

- Have your dentist prepare and maintain dental charts for your child and be sure they are updated each time an examination or dental work is performed
- Know where your child's medical records are located
- Arrange with your local law-enforcement agency to have your child fingerprinted and keep the fingerprints in a safe and easily accessible place
- Keep a DNA sample from your child, like an old toothbrush in a brown envelope licked closed by your child, at room temperature in a dry, easily accessible place that is far away from heat (Sedlak *et al.*, 2002)

The role of the dentist: The problem of missing children has turned to be a plague. Everyday emerge many tragic stories. As a result this phenomenon found worldwide attention and led to more coordinated efforts among state, law enforcement and independent organizations. These cases have altered the way we face these emergency situations and have made parents more suspicious and more prepared to confront it. An example of their activation is the development of national response systems such as the photographs of missing children on milk cartons and central resources as well as recording dental data of their children. Many people are familiar with the concept of dental identification and it is frequently

mentioned on television news. But the nuances and complexities of the process are rarely understood. The central dogma of dental identification is that postmortem dental remains can be compared with antemortem dental records. Obviously, individuals with numerous and complex dental treatments are often easier to identify than those individuals with little or no restorative treatment (Sweet and di Zinno, 1996).

There are two methods concerning the identification the conventional and the biological one. In particular the conventional method includes Comparative identification and Postmortem profiling; When antemortem dental records are unavailable and other methods of identification are not possible, the forensic dentist can assist in limiting the population pool to which the deceased is likely to belong and thus increase the likelihood of locating antemortem dental records (Sweet and di Zinno, 1996).

This process is known as postmortem dental profiling. The information from this process will enable a more focused search for antemortem records. A postmortem dental profile will typically provide information on the deceased's age, ancestry background, sex and socio-economic status. In some instances it is possible to provide additional information regarding occupation, dietary habits, habitual behaviors and occasionally on dental or systemic diseases. Forensic anthropologists most often provide details of osteological studies but forensic dentists can assist in the process (Steyn and Iscan, 1998; Burris and Harris, 1998; Hsu *et al.*, 1997; Solheim, 1993; Shapiro, 1978; Noble, 1974).

The two processes described above, comparative identification and postmortem profiling, represent the most common methods of dental identification. However, in some instances more novel and innovative techniques have been applied. There have been a number of requests from individuals and dental organizations over the years to insist that dental prostheses are labeled with the patient's name or a unique number (Borrman *et al.*, 1999). The NHS provide a fee for dentists who label their patients dentures, although this is often only used in instances where the wearer is a resident in a care home or other establishment with a central sterilizing system for dental prostheses. Labeled dentures can be of great assistance in the identification of individuals (Marella and Rossi, 1999).

Unlabelled dentures have been recovered from patients and then fitted to casts retained by the treating dentist or laboratory and this has been an accepted method of identification (Jacob and Shalla, 1987). Other

dental appliances such as removable orthodontic braces have also been used for identification purposes. (Whittaker and MacDonald, 1989) describes a case where a removable orthodontic appliance was used to identify a victim of a house fire researchers have also described the use of palatal rugae patterns rendered on dental casts to compare with found remains. Positive identifications have resulted from this technique (Thomas and van Wyk, 1988).

As far as the biological method is concerned because of the resistant nature of dental tissues to environmental assaults (incineration, trauma, mutilation, etc.) teeth represent an excellent source of DNA material (Schwartz *et al.*, 1991). When all the previously described techniques fail this biological material can provide the necessary link to prove identity (Sweet and Hildebrand, 1998).

Through the Polymerase Chain Reaction (PCR), it can replicate DNA a billion fold using it for having multiple identification tests. Comparison of DNA preserved in and extracted from the teeth of an unidentified individual can be made to a known antemortem sample (stored blood, hairbrush, clothing, cervical smear, biopsy, etc.) or to a parent or sibling (Sweet and di Zinno, 1996). Now we have available a variety of means which may facilitate the dentist in the investigation. Examples of the sources are provided as:

- Teeth: Natural and synthetic/fixed and removable
- Bone: Trabecular pattern, osseous anomalies
- Presence of foreign bodies: Implants, unretrieved amalgam particles, surgical instruments, bullets, fragments of various origins
- Sinus configuration: Maxillary and frontal
- Skull sutures:
- Soft tissue features: Rugae (Rugoscopy) and lip (cheiloscopy, quieloscopy) Prints
- Photographic comparison: Facial or dental superimposition or approximation
- DNA

It is important to underline that in order to compare either the ante-mortem or the post-disappearance findings we must have available a complete dental record. The dental clinical data that should be gathered for identification purposes include:

- Dental radiographs
- Facial photographs
- Study casts

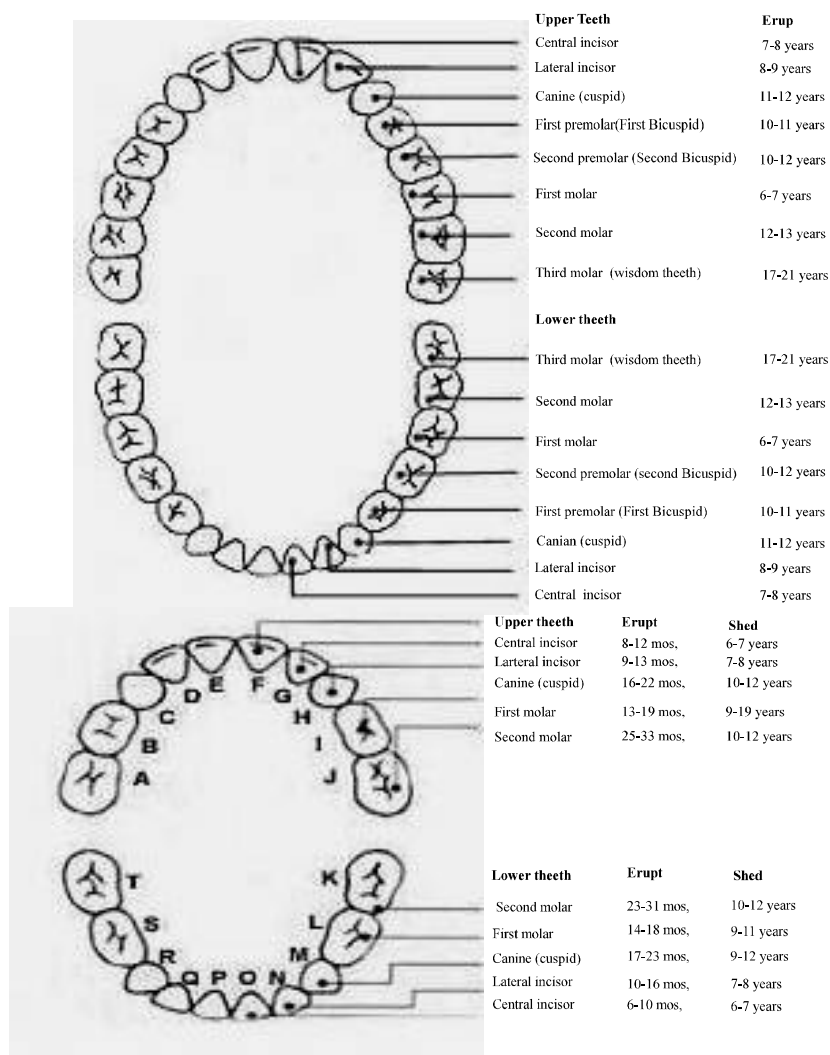


Fig. 2: Child's age according to the stage of dentition's development

- Dental histories documenting
- Teeth present
- Distinguishing features of oral structures
- Bite registrations
- Restorative history documenting restored surfaces and material used

Additionally, the surgeon in order to have a fulfilled record may collect nondental sources as well, of distinguishing information which currently include fingerprints, physical descriptions, DNA from blood, saliva and other tissue.

The question that emerges easily is how we can rely so much on teeth in order to result in a safe conclusion. We should never neglect that as we growing physical characteristics altering constantly. On the contrary, the denture has the same function as our fingerprints have.

Thus teeth not only represent a suitable repository for such unique and identifying features, they also survive most postmortem events that can disrupt or change other body tissues (Sweet and di Zinno, 1996).

Another important issue is that through the teeth present the dentist is able to identify the age of the child according to the stage of its dentition's development. The following charts have been created by Massler and Schour providing a graphical representation of the developing dentition (Fig. 2). The scientific society recognizing the catalytic role that a dentist might play in the identification of a missing child has sponsored programs in order to present the potentials of the field of Forensic dentistry.

In the 23rd Annual Day of Missing Children in 2005 underlying the dentist's role, the Department of the Attorney General's Missing Child Centre and the Friends



Fig. 3: Child identification program. The Purple Pack-Chip's kit 21, 22, 24 (<http://www.bellaonline.com>)

of The Missing Child Centre of Hawaii processed Free Child Identification Kits. Volunteers weighed, measured, photographed, fingerprinted and completed an optional dental chart of children up to age 18 in order to record individual data and allow parents to use them in the future in an emergency (Lingle, 2005). Furthermore, the American Academy of Paediatric Dentistry (AAPD, 2007b) supporting the role that dental records play in forensic identification, encourages dental practitioners and administrators of child identification programs to implement simple practices that can aid in identification of unknown infants, children and adolescents. The AAPD recommends that parents establish a dental home where clinical data is gathered, stored and updated routinely and can be made available to assist in identification of missing and/or abducted child (Adams, 2003). A dental home should be established for every child by 12 months of age by the American Academy of Paediatric Dentistry (AAPD, 2007a). Moreover, the AAPD (2007a) encourages community identification programs to include a dental component documenting the child's dental home and encouraging consistent dental visits. Child Identification Program (CHIP) had been sponsored by the Freemasons (Fig. 3). This program gathered saliva samples for DNA fingerprinting, videos, toothprints and fingerprints (<http://www.mychip.org>).

Another relevant program, the New England Kids Identification System (K.I.D.S.) sponsored by the Massachusetts Free Masons and the Massachusetts Dental Society had incorporated dental bite impression and cheek swabs to gather DNA material into the CHIPS events (<http://www.mychip.org>). Of course, neither parents nor do the majority of dentists look very familiar with all these procedures. However it's undeniable that completing a child's dental record is not painful is worth-timing can be included in the child's routine dental visit and is very helpful in case a child becomes missed. A detailed dental record, updated at recall appointments, economically establishes an excellent database of

confidential, state-of-the-art child identification information that can be retrieved easily, stored safely and updated properly (<http://www.ada.org>; Spencer, 2004).

RESULTS AND DISCUSSION

What does a complete dental record include?: The dental clinical data that are gathered for identification purposes include:

- Dental radiographs
- Facial photographs
- Study casts
- Dental histories documenting
- Teeth present
- Distinguishing features of oral structures
- Bite registrations
- Restorative history documenting restored surfaces and Material used (Adams, 2003)

Additionally, the surgeon in order to have a fulfilled record may collect nondental sources, as well, of distinguishing information which currently include fingerprints, physical descriptions, DNA from blood, saliva and other tissue (Sweet and Hildebrand, 1998; Spencer, 2004; Bowers and Johansen, 2001).

Toothprints and saliva DNA: Toothprints is an easy way to obtain precautionary the denture of a child. Toothprints is a trademarked product whose inventor is Dr. David Tesini, a paediatric dentist from Massachusetts. It is a tool that dentists use in order to help police identify and track missing children (<http://www.case.edu/news/htm>; Tesini *et al.*, 1985). Toothprints is a patented, arch-shaped thermoplastic dental impression wafer (Fig. 4). This can be taken either by a dentist or it can be done at home (Banks, 2002).

The primary purpose in the development of Toothprints® bite impressions is to record an individual's unique dental characteristics showing the size and shape of the teeth, position of the teeth within the dental arch and the relationship of the maxillary and mandibular arches to each other (Tesini *at al.*, 1999; <http://www.bellaonline.com>) Toothprints softens in hot water and then is placed on the patient's lower arch. The child bites into the Toothprint wafer for 50 sec in the same manner as a bite registration taken for prosthetics or orthodontics. After allowing a 2-3 min cool-down period in the plastic bag provided, the dentist will give the impression in the parent to save it. When the child bites into the softened Toothprint wafer, these individual tooth characteristics are recorded, plus DNA in saliva is collected, all important information for identification. These recordings on the Toothprints® produce an infinitesimal number of possible identifiers which make

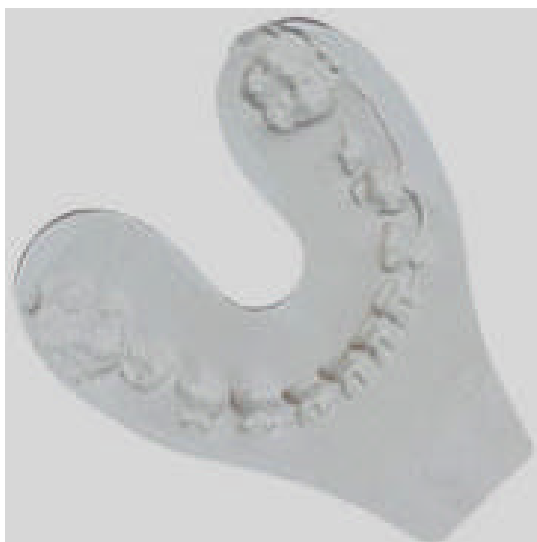

Fig. 4: Toothprints impression

dental characteristics unique to every individual. Not even identical twins have the same dental characteristics (Tesini *et al.*, 1999). It's very important to state that Toothprints bite impressions is ideal to be updated. So there is a recommended schedule in order to keep impressions useful:

- Initial impression: Age 3 (or after all primary teeth have erupted)
- Update: Age 7 or 8 (or after the upper and lower incisors and the first permanent molars have erupted)
- Update: Age 12 or 13 (or after all permanent teeth, excluding 3rd molars, have erupted) (Banks, 2002)

Saliva can be an alternative way of necessary evidence by collecting its DNA. Salivary DNA is derived from the constant shedding of epithelial cells from the oral mucosa. Objects remaining in the mouth for any period of time or the rubbing of objects against the tissues of the mouth collect this salivary DNA. It is found that saliva collected from a Toothprints® wafer left in the mouth for 50 sec or rubbing against intraoral tissues (e.g., toothbrush) would contain a significant amount of genomic or mitochondrial DNA (Banks, 2002; Sognaes *et al.*, 1982; Spencer, 1995). By the technique of PCR just tiny amounts of DNA is replicated while it's worth referring that even 1 mL is enough to realize >1,000,000 separate tests. Thus in such small quantities, the researchers can achieve high accuracy and distinguish even minor differences. Besides it can be easily collected, stored and shipped as well as it can be obtained at low

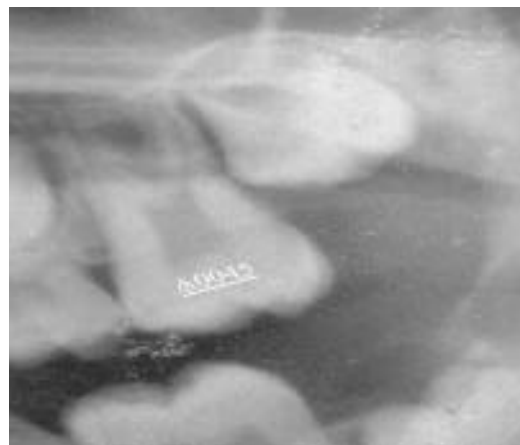


Fig. 5: The dental tag (TDS) was placed on the buccal surface of the first upper left molar of a 10 years old boy

cost in sufficient quantities. According to Banks (2002) Director of the National Center for Missing and Exploited Children, when Toothprints is taken, sufficient proteins in the saliva remain on the wafer from which a DNA test can be successfully performed for yet a 2nd means of identification from Toothprints. He also states that, since the Toothprints wafer is sealed in a zipper-type plastic bag, enough scent remains for a trained dog to identify and track with it (Banks, 2002). Also, as far as the DNA sample is concerned parents can collect it on their own easily. By using a sterile cotton swab or Q-Tip they swab the inside of their child's mouth. Then they place the Q-tip in a zip lock freezer or other plastic storage bag suitable for the freezer after the Q-tip has dried. After seal the bag, they fold it up and place it in another freezer bag, ensuring that it is securely sealed and finally they have to put in freezer so as to conserve it (Spencer, 1995, 2004).

Engrave serial numbers into children's: Another step that can be down precautionary is the denture's marking by engraving a code number in the child's permanent teeth which can be revealed only after an x-ray.

Trudent systems Inc (TDS-U.S.A) places the information about the tagged individual (name, age, date of birth, etc.) into its computer database (Fig. 5). When a tagged person is reported missing, the code number is published bimonthly in dental magazines that reach >140,000 dental offices in the USA and Canada. As long as the individual remains missing, the company will continue to publish the codes. When a code is detected during a routine dental X-ray, the dentist should check

the published codes or contact the company. If it corresponds to a missing person, the dentist should inform the law enforcement agency, the police and the company (TDS). The police in collaboration with TDS will inform the child's parents. If the child lives in another country the interpol should be informed.

There are various engraving techniques including metallic materials, microchips, microlabels and non-metallic materials. Microchips seem to be superior than the others methods as by the photochemical etching process that they are inserted, offer an acceptable aesthetic result due to their small size, they're also cost effective and come up to all the forensic requirements whether needed. As far as the procedure is concerned, appears to be similar to the procedure of filling with compounds. At the end the dentist shouldn't neglect to record the personal data of the child in a registration form by also marking the serial number one engraved and keeps it in relevant libraries so to be easily retrieved (Stavrianos *et al.*, 2006).

A range of conclusions can be reached when reporting a dental identification blended in 4 conclusions by ABFO (1994):

Positive identification: Antemortem and postmortem data match sufficiently with no unexplainable discrepancies to establish that they are from the same individual.

Possible identification: Antemortem and postmortem data have consistent features but it is not possible to establish identity positively because of the quality of either the postmortem remains or the antemortem evidence.

Insufficient evidence: The available information is insufficient to form the basis for a conclusion.

Exclusion: Antemortem and postmortem data are clearly inconsistent.

Use of the dental records: At the time a missing child report is made, the law-enforcement agency which gets involved with the case when feasible and appropriate, provide a dental record release form to the parent, custodian, health care surrogate or other legal entity authorized to release the dental records of the missing child. This authority is responsible to ask and use these evidences in order to facilitate the procedure of the investigation. Especially, the law-enforcement agency shall endorse the dental record release form with a notation that a missing child report has been made. When the dental record release form is properly completed by the parent, custodian, health care surrogate or other legal entity authorized to release the dental records of the missing child and contains the endorsement, the form is

sufficient to permit a dentist or physician in this state to release dental records relating to the missing child to the law-enforcement agency (Stavrianos *et al.*, 2006; <http://www.cbi.state.co.us>).

CONCLUSION

It's even clear that a detailed dental record, updated at recall appointments can provide us an excellent database of confidential, state-of-the-art child identification information which can have be retrieved and stored easily as well as being updated properly. Besides completing a dental record is not painful at all and can be in the scope of the child's routine dental appointment. Therefore, it is really worth-timing as can be proved to be very helpful in an emergency case. So bearing in mind that tooth is a useful tool for identification as it is one of the hardest body tissues that survives in postmortem events the goal must be to familiarize and sensitize dentists with the idea of using simple dental knowledge to produce social service.

REFERENCES

- AAPD, 2007a. Guideline on Oral Health Care for the Pregnant Adolescent. American Academy of Pediatric Dentistry, Chicago IL., pp: 9.
- AAPD, 2007b. Policy on the Dental Home. American Academy of Pediatric Dentistry, Chicago.
- ABFO. (American Board of Forensic Odontology), 1994. Body identification guidelines. J. Am. Dental Assoc., 125: 1244-1254.
- Adams, B.J., 2003. Establishing personal identification based on specific patterns of missing, filled and unrestored teeth. J. Forensic. Sci., 48: 487-496.
- Banks, P., 2002. Toothprints-toothprint DNA dental impressions. My Precious Kid Family Safety Products and Baby Gear Store. <http://www.mypreciouskid.com/toothprints.html>.
- Borrmann, H.I., J.A. DiZinno, J. Wasen and N. Rene, 1999. On denture marking. J. Forensic Odontostomatol., 17: 20-26.
- Bowers, C.M. and R.J. Johansen, 2001. Digital analysis of bite marks and human identification. Dent. Clin. North Am., 45: 327-342.
- Burris, B.G. and E.F. Harris, 1998. Identification of race and sex from palate dimensions. J. Forensic Sci., 43: 959-963.
- Hsu, J., P. Tsai, T. Hsiao, H. Chang and L. Lin *et al.*, 1997. The effect of shovel trait on Carabellis trait in Taiwan Chinese and aboriginal populations. J. Forensic Sci., 42: 802-806.

- Jacob, R.F. and C.L. Shalla, 1987. Postmortem identification of the edentulous deceased: Denture tissue surface anatomy. *J. Forensic Sci.*, 32: 698-702.
- Lingle, L., 2005. Governor of Hawaii Life Sciences Guide. Department of Business, Economic Development and Tourism, Hawaii, pp: 2.
- Marella, G.L. and P. Rossi, 1999. An approach to identification by means of dental prostheses in a burnt corpse. *J. Forensic Odontostomatol.*, 17: 16-19.
- Noble, H.W., 1974. The estimation of age from the dentition. *J. Forensic Sci. Soc.*, 14: 215-221.
- Schwartz, T.R., E.A. Schwartz, L. Mieszerski, L. McNally and L. Kobilinsky, 1991. Characterization of deoxyribonucleic acid (DNA) obtained from teeth subjected to various environmental conditions. *J. Forensic Sci.*, 36: 979-990.
- Sedlak, A.J., D. Finkelhor, H. Hammer and D.J. Schultz, 2002. NISMART: National Estimates of Missing Children: An Overview. U.S. Department of Justice, Washington, DC., pp: 5.
- Shapiro, H.L., 1978. Forensic anthropology. *Ann. N. Y. Acad. Sci.*, 318: 3-8.
- Sognaes, R.F., R.D. Rawson, M. Graff and N.B. Nguyen, 1982. Computer Comparison of bitemark patterns in identical twins. *J. Am. Dent. Assoc.*, 105: 449-451.
- Solheim, T., 1993. A new method for dental age estimation in adults. *Forensic Sci. Int.*, 59: 137-147.
- Spencer, D.E., 1995. Bite Marks in Child Abuse: Manual of Forensic Odontology. 3rd Edn., Printing Specialists, Montpelier VT, pp: 78.
- Spencer, D.E., 2004. Child abuse: Dentist's recognition and involvement. *J. Calif. Dent. Assoc.*, 32: 299-303.
- Stavrianos, C., I. Stavrianou and N. Petalotis, 2006. Identification of missing children using dental tag. *Balk J. Stom.*, 10: 213-216.
- Steyn, M. and M.Y. Iscan, 1998. Sexual dimorphism in the crania and mandibles of South African whites. *Forensic Sci. Int.*, 98: 9-16.
- Sweet, D. and D. Hildebrand, 1998. Recovery of DNA from human teeth by cryogenic grinding. *J. Forensic Sci.*, 43: 1199-1202.
- Sweet, D. and J.A. di Zinno, 1996. Personal identification through dental evidence-tooth fragments to DNA. *J. California Dental Assoc.*, 24: 35-42.
- Tesini, D.A., D.B. Harte and K. Crowley, 1999. Dentistry's role in identification of missing and unknown children: Update on the dental bite impression technique. *J. Mass Dent. Soc.*, 48: 29-34.
- Tesini, D.A., K.D. O'Malley and S. Schwartz, 1985. Development of bite impression technique for use in identification of unknown and missing children. *J. Mass Dent. Soc.*, 34: 61-69.
- Thomas, C.J. and C.W. van Wyk, 1988. The palatal rugae in identification. *J. Forensic Odontostomatol.*, 6: 21-27.
- Whittaker, D.K. and D.G. MacDonald, 1989. A Colour Atlas of Forensic Dentistry. Wolfe Medical Publications Ltd., London.