

## 808 nm Diode Laser in Oral Surgery: A Case Report of Laser Removal of Fibroma

<sup>1</sup>A. Eliades, <sup>1</sup>C. Stavrianos, <sup>1</sup>A. Kokkas, <sup>2</sup>P. Kafas and <sup>2</sup>I. Nazaroğlu  
<sup>1</sup>Department of Endodontics, <sup>2</sup>Department of Oral Surgery and Radiology,  
School of Dentistry, Aristotle University, Thessaloniki, Greece

---

**Abstract:** A number of reports have been published concerning laser applications in oral and facial practice. Laser performance is a common surgical procedure in the field of oral surgery, implant dentistry, endodontic treatment and periodontic therapy as well. Fibroma excision is a procedure usually done for aesthetic and functional reasons. The role of laser surgery in the oral cavity is well established. The use of diode laser removing a fibroma is currently under investigation. The benefits of oral-laser surgery i.e., a relatively bloodless surgical and post-surgical course, minimal swelling and scarring and reduction of post-surgical pain are discussed. An interesting case of removal of a fibroma with a 808 nm diode laser is presented.

**Key words:** Laser applications, oral surgery, diode laser, fibroma, frenectomy, Greece

---

### INTRODUCTION

The role of laser in dentistry is well-established in conservative management of oral disease, although in oral surgery it is in primary levels (Pick and Colvard, 1993; Kafas and Kafas, 2008). In the field of oral laser surgery there are little or minimal organized double-blind randomized controlled trials. The diode laser system has found wide recognition in the area of lasers as a result of its practical characteristic and is considered an important tool for a large number of applications (Jackson and Lauto, 2002). Already, diode laser showed satisfactory results as an extra adjunct to the conservative methods in the management of inflamed periodontal tissues, endodontics and periimplant tissues as well (De Souza *et al.*, 2008; Kafas *et al.*, 2009). Also according to a review study (Depepe and Horch, 2007), the use of diode laser systems for the treatment of oral and maxillofacial diseases has found apply in removal of premalignant lesions of the oral mucosa.

The laser surgery can be used for ablation of lesions, incisional and excisional biopsies, gingivectomies, gingivoplasties, soft tissue tuberosity reductions and certain crown lengthening procedures (Kafas and Kafas, 2008; Pick and Colvard, 1993; Wigdor *et al.*, 1995). This case report refers to a patient with a fibroma on the buccal mucosa and its following laser removal without infiltrated local anaesthesia. The reassurance of the patient about the painless procedure is one of the most important criteria followed.

### MATERIALS AND METHODS

**Case report:** A 52 years old Mediterranean male was referred to the School of Dentistry of Aristotle University of Thessaloniki in February, 2010. A small tumor was appeared on the right buccal mucosa and its overgrowth constricts the oral cavity's function and causes aesthetic problem. When questioned for his late seek of dental assistance the patient neglect to report this information. The patient's medical history was remarkable and local factors such as local tumor infiltration and metastasis of cancer all of which have been proven to be responsible for such a clinical appearance were eliminated. No allergies were reported. The weight of the patient was 78 kg. His height was 175 cm. In the clinical examination, there was no lymphadenopathy. The intraoral examination revealed the presence of a fibroma on the buccal mucosa (Fig. 1). As a consequence this presented a pathological mechanical pressure of the associated nature denture and it is very common finding in oral and maxillofacial pathology. It was decided to perform laser excision of the pathological tissue without infiltrated anaesthesia by the use of specific laser parameters. The laser equipment was defined by the manufacturer (Lamda Scientifica Srl) as a class-II B device according to the CE conformity statement and the parameters were 1100 mW at 808 nm with continuous output. The optical fiber used was 300 µm diameter allowing a very fine soft tissue cut. According to the manufacturer, the optical protective glasses had an optical density >5 at the wavelength of emission from the diode.

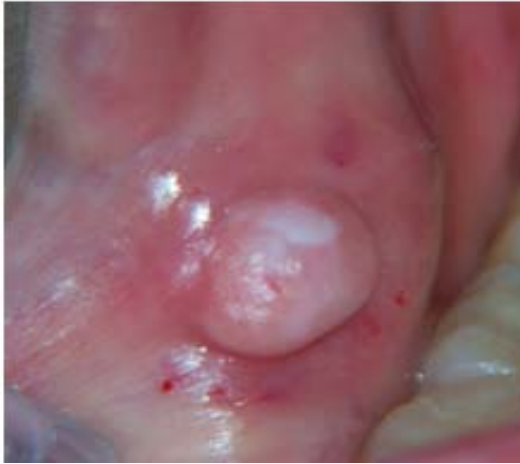

Fig. 1: The fibroma on the right buccal mucosa was referred as a dysfunction problem by the patient

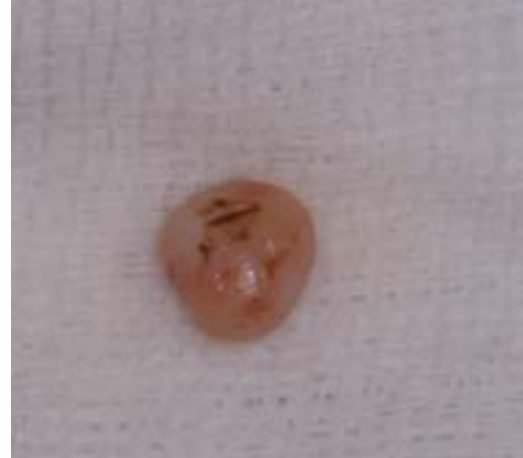

Fig. 4: The fibroma after the laser surgery removal

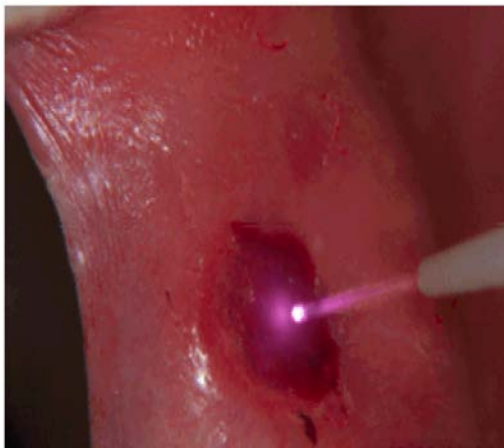

Fig. 2: The fiber-optic of diode laser applied on the lesion using specific pain-free parameters

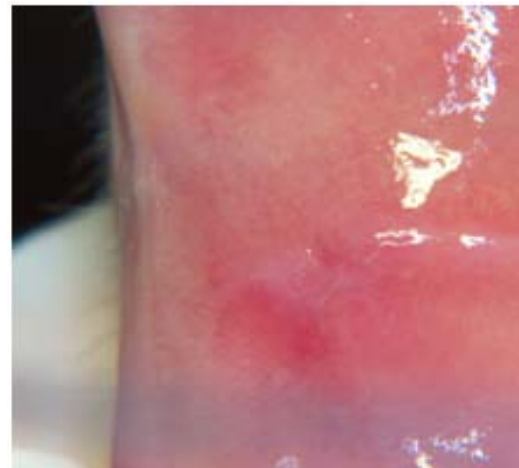

Fig. 5: About 10 days after the laser surgery the patient was recalled. The photograph shows the satisfactory healing

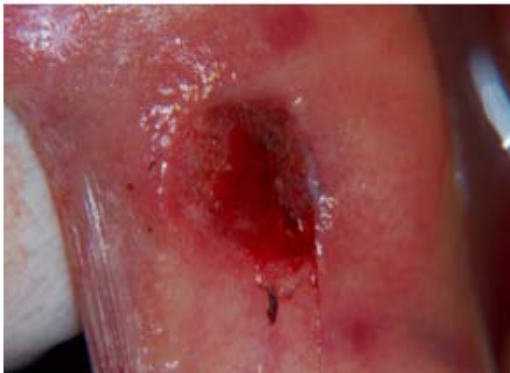


Fig. 3: The final ovoidal laser cut did not require sutures and postoperative haemostasis was a fact

According to standard EN 60825 CEI 76-2 II, the minimum optical density has been estimated to be 4.96 at 0.05 m. The fibroma was sprayed with lidocaine 10% four times in 1 min intervals.

The laser fiber was applied almost vertically and anteriorly to the junction with the healthy mucosa and initially causing disruption of the mucosa continuity. This easily allowed performing a deeper cut of the fibroma in a horizontal dimension (Fig. 2).

The design of the excision was ovoidal allowing easy pass of the fiber-optic peripherally to the fibroma (Fig. 3). The whole procedure took about 10 min. The patient referred no pain, either intra-operative nor

post-operatively and no sutures were required. Also haemostasis was optimum immediately after the procedure (Fig. 3).

The fibroma was sent for histopathologic examination where at it was testified (Fig. 4). After a 10 days period, the region was found completely healed (Fig. 5). Pre-operatively, the patient had been informed verbally about the procedure finally signing a written consent form.

## RESULTS AND DISCUSSION

Several researchers refer to the clinical uses for lasers with the aim of bringing the laser to the dental practitioner to improve dental care (Wigdor *et al.*, 1995). Currently, soft tissue applications have constituted the primary area for the clinical use of lasers in dentistry. Surgical removal of fibroid tumor (fibroma) is a common procedure in the field of oral and maxillofacial surgery.

The safety and efficacy of laser systems and especially the diode laser is already evaluated for the treatment of facial pigmented and vascular lesions and in oral surgery for example upper and lower frenulectomy, fibroma and excision of epulis fissuratum and gingivae hyperplasia (Desiate *et al.*, 2009). The advantages of lasers include a relatively bloodless surgical and post-surgical course, minimal swelling and scarring, coagulation and cutting minimal or no suturing, reduction in surgical time when infiltrated anaesthesia is used and in a majority of cases much less or no post-surgical pain (Pick and Colvard, 1993).

Also no sutures are required and the risk of a post-operative infection is limited (kafas epoulis). Laser transmits energy to the cells causing warming, welding, coagulation, protein denaturization, drying, vaporization and carbonization (Kafas and Kalfas, 2008; Pick and Colvard, 1993). Furthermore, another benefit of the removal of fibroma with a diode laser is the possible avoidance of needle-infiltrated anaesthesia which is desired by many patients i.e., geriatric patients (according to its size). On the other hand, main disadvantage of the laser surgery of such a case is the time required in comparison to electrotome and blade incision which always requires anaesthesia.

The clinician has to decide which technique is medically superior for his patients. In the case described above, the use of diode laser was preferred in order to avoid any painful needle injection even if the clinician needs more time to complete the surgery procedure. The whole procedure was performed without pain and no sutures were necessary. However, haemostasis was optimum immediately after the removal of the fibroma. The

patient was content with the laser surgery due to the painless procedure either intra-operatively or post-operatively. The healing period of ten days was found to be uneventful.

## CONCLUSION

Diode lasers contribute significantly to the field of oral surgery providing an invaluable resource for clinicians who perform treatment of soft tissue issues. Diode laser provides benefit to dental patients and professionals and also is very useful in surgical dental procedures. The use of diode laser seems to be promising in patients who need to be treated with a technique where the operative and post-operative blood loss and post-operative discomfort are reduced. Also pain perception is an important issue in creating guidelines for surgical procedures.

According to the case described above and other articles every patient may have different pain thresholds which are not dependent to age so the soft tissue laser treatment without infiltrated anaesthesia has to be initiated in >1000 mW and if there is no pain to increase slowly until reaching the pain threshold. A knowledge of the efficiency and safety of this technique is needed. Randomized controlled clinical trials must be performed to prove the efficacy of any technique. It is particularly important that diode laser removal of fibroma may be performed without infiltrated anaesthesia with a completely and satisfactory healing post-surgically. Finally the need of infiltrated anaesthesia is determined according to the individual's hypersensitivity and the case of soft tissue excision (i.e., the size of the lesion and the region of its appearance).

## REFERENCES

- De Souza, E.B., S. Cai, M.R. Simionato and J.L. Lage-Marques, 2008. High-power diode laser in the disinfection in depth of the root canal dentin. *Oral Surg. Oral Med. Oral Pathol. Oral Radiol. Endod.*, 106: e68-e72.
- Deppe, H. and H.H. Horch, 2007. Laser applications in oral surgery and implant dentistry. *Lasers Med. Sci.*, 22: 217-221.
- Desiate, A., S. Cantore, D. Tullo, G. Profeta, F.B. Grassi and A. Ballini, 2009. 980 nm diode lasers in oral and facial practice: Current state of the science and art. *Int. J. Med. Sci.*, 6: 358-364.
- Jackson, D.S. and A. Lauto, 2002. Diode-pumped fiber lasers: A new clinical tool. *Lasers Surg. Med.*, 30: 184-190.

- Kafas, P. and S. Kalfas, 2008. Carbonization of a radicular cyst using fiberoptic diode laser: A case report. *Cases J.*, 1: 113-113.
- Kafas, P., C. Stavrianos, W. Jerjes, T. Upile, M. Vournachis, M. Theodoridis and I. Stavrianou, 2009. Upper-lip laser frenectomy without infiltrated anaesthesia in a paediatric patient: A case report. *Cases J.*, 2: 7138-7138.
- Pick, R.M. and D.M. Colvard, 1993. Current status of lasers in soft tissue dental surgery. *J. Periodontol.*, 64: 589-602.
- Wigdor, A.H., J.T. Walsh, J.D.B. Featherstone, S.R. Visuri, D. Fried and J.L. Waldvogel, 1995. Lasers in dentistry. *Lasers Surg. Med.*, 16: 103-133.