

## The Role of Dentist in the Distinguish of Child Abuse: A Case Report

<sup>1</sup>C. Stavrianos, <sup>2</sup>L. Zouloumis, <sup>1</sup>E. Samara, <sup>1</sup>D. Tatsis and <sup>1</sup>A. Eliades

<sup>1</sup>Department of Endodontology (Forensic Dentistry),  
School of Dentistry, University of Aristotle, Thessaloniki, Greece

<sup>2</sup>Department of Oral and Maxillofacial Surgery, Greece

---

**Abstract:** When a child presents for examination particularly if there is any evidence of severe or repeated trauma involved, the history may alert the dentist to the possibility of a child abuse. Abuse may cause serious injury to the child and may even result in death. These behaviors are serious crimes, both as misdemeanors and felonies, punishable by arrest and imprisonment. Dentists should be aware that physical or sexual abuse may result in oral or dental injuries or conditions that sometimes can be confirmed by laboratory findings. When questions arise or when consultation is needed, a pediatric dentist or a dentist with formal training in forensic odontology can ensure appropriate testing, diagnosis and treatment. This case report aims to present a case of a physically abused child 12 years old. The examination revealed fracture of the left ocular area and as a result the adipose tissue all around the eyeball fall like a drop into the sinus. The CT scan of the facial skull was done so as to detect the consequences of the fracture. In conclusion, the ability to properly identify suspicious injuries to the head, face, mouth and neck of a child is imperative for dentists. Dentists are encouraged to be knowledgeable about such findings and their significance and to meticulously observe and document them.

**Key words:** Child abuse, dentist's role, forensic dentistry, imperative, consultation, imprisonment

---

### INTRODUCTION

Child abuse is a public health problem existing all over the world. The victims of child abuse can be separated in two categories: the ones who lived through and those who did not. Child abuse can be defined as any non-accidental trauma, failure to meet basic needs or abuse inflicted upon a child by the caretaker that is beyond the acceptable norm of childcare in the culture. Abuse may cause serious injury to the child and may even result in death (Misawa, 2001; Kenney and Spencer, 1995). Abuse can range from habitually humiliating a child to not giving the necessary care and from excessively shaking a child to rape (Stavrianos and Metska, 2002).

These behaviors are serious crimes, both as misdemeanors and felonies, punishable by arrest and imprisonment (Kenney and Spencer, 1995). Dentists should be aware that physical or sexual abuse may result in oral or dental injuries or conditions that sometimes can be confirmed by laboratory findings. Furthermore, injuries inflicted by one's mouth or teeth may leave clues regarding the timing and nature of the injury as well as the identity of the perpetrator. Dentists are encouraged to be knowledgeable about such findings and their significance and to meticulously observe and document them. When

questions arise or when consultation is needed, a pediatric dentist or a dentist with formal training in forensic odontology can ensure appropriate testing, diagnosis and treatment (Stavrianos, 2009). As dentists will probably have more chances to see those cases of hypodermal bleeding in faces, abrasions and mandibular fractures, they need to keep it in mind all times (Misawa, 2001). Dental professionals seldom report cases of child abuse of any kind. A child may be physically or sexually abused but it is important to note that these types of abuse are more typically found in combination than alone. For example, a physically abused child is often emotionally abused as well and a sexually abused child also may be neglected (Kenney and Spencer, 1995, Vale, 1997). International research in the literature has shown that more than the last 30 years dentists lack the appropriate knowledge for recognising and reporting the cases of child abuse.

### CASE REPORT

In this study a case of physically abused child 12 years old is reported. The evaluation revealed fracture of the left ocular area and as a result the adipose tissue all around the eyeball fall like a drop into the sinus (Fig. 1).

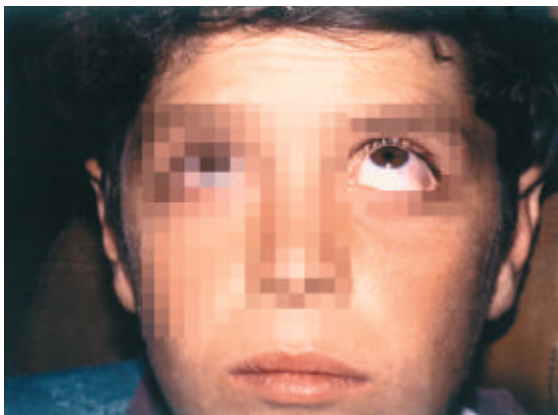

Fig. 1: Fracture of the area of the left ocular

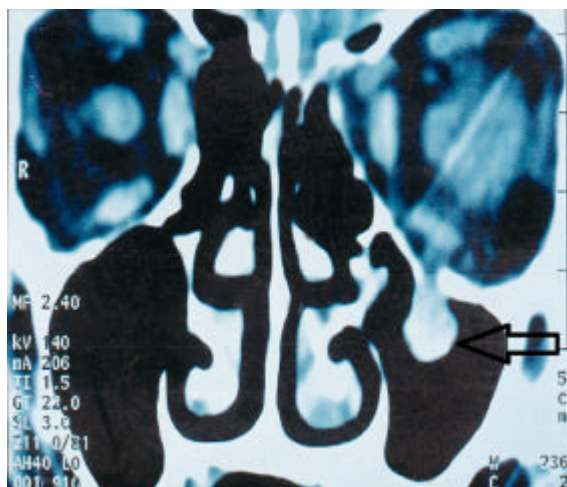


Fig. 2: CT scan. In this frontal section, the fracture of left lower ocular wall is shown clearly. This allows the adipose tissue under the eyeball fall in the sinus like a drop

Injuries of the area in front of the eye, like lenses that abide diastasis or detach the retina are due to contusion or fracture of the surface or the dome of the skull. The CT scan of the facial skull was done so as to detect the consequences of the fracture (Fig. 2).

## DISCUSSION

**Distinguishing the abuse in the dental office:** The evidence of severe and repeated trauma should alert the dentist to identify possible child abuse. The ability of proper identification of suspicious injuries to the head, face, mouth and neck of the child is of great importance for the dentists. History can be the only valid source of information and as legal procedures. People with a history

of child abuse in their own childhood or of abuse against other children with problems with alcohol or drug abuse, with anger management especially to poor parenting skills and with poor coping skills especially related to problem solving and making or having choices (Vale, 1997; Stavrianos and Metska, 2002).

Children born prematurely have been shown to have three times a greater risk of being abused (Kenney and Spencer, 1995). Children who generally have poor general hygiene are clothed inappropriate for the weather or suffer from medical or educational deprivation, all indicate a child at risk.

Culture, religion and inappropriate social models may play a part. Risk assessment is based on outcomes of actual cases. It is important to know that in case to protect a child going to be adopted, mental health, penal records of both parents and authentication of these documents are required (Kenney and Spencer, 1995; Vale, 1997; Mouden, 1998a, b).

Child maltreatment can undoubtedly be considered a breakdown in the parenting skills of the child's caregivers. One theory holds that parents unrealistic expectations for the child and for themselves can contribute to the abuse. Another theory is based on the conviction that children exist to satisfy parental needs. Some mothers are simply not satisfied by the unresponsiveness and lack of feedback from an infant. Other abusers explain the maltreatment of children as a suitable means of parenting (Mouden, 1998a, b). On the other hand, many cases involving a father occurred during times he was stressed by his family troubles or a child's continuous crying. Recently financial worries, bad residential environments and children's defiant attitudes have been added to the contributing factors of abuse (Misawa, 2001).

**Identifying:** The dentist should consider of an abuse or neglect when the history reveals the following:

- History of multiple injuries
- The family offers an explanation that is not compatible with the nature of the injury (i.e., if the dental injuries resulted from a fall, one would usually expected to also find bruised or abraded knees, hands or elbow) (Vale, 1997)
- Delay in seeking care for the injury
- The family avoids discussing about the injury (Stavrianos *et al.*, 2005)
- The parent refuses to cooperate with the planned course of treatment or refuses to be separated from the child
- The parent takes the child from office to office or from one hospital emergency room to another, so as to avoid the chances of recognition

- Refusal to consent to diagnostic studies for the child (In USA the law allows photos or x-rays may be taken without parental consent if abuse is reasonable suspected)
- Parent persists in presenting symptoms unrelated to the obvious condition of the child (Kenney and Spencer, 1995)

Moreover, the victim's and the abuser's behaviour reveal a lot about the situation at home. The abused child may appear unduly aggressive or may be withdrawn. Maybe his behaviour change suddenly when the family or health provider appear. He/she may commence stuttering, bedwetting or having nightmares (perhaps a sign of sexual abuse). Any intraoral soft tissues injuries of the infant or very young child, oral mucosa lesions, incisors missing and early resorption of the roots of the maxillary primary central incisors must make one highly suspicious of abuse. Oral injuries may be inflicted with instruments such as eating utensils or a bottle during forced feedings. The abuse may result in contusions, burns or lacerations of the tongue, lips, buccal mucosa, palate, gingival alveolar mucosa or frenum; fractured, displaced or avulsed teeth or facial bone and jaw fractures. In older children, gags used to silence or punish a child can leave bruises at the corners of the mouth.

A child presenting with fractured or missing teeth, multiple root fractures or unusual malocclusions in the absence of adequate explanation, call for a careful case review.

**Typical oral lesions:** Bruises, lacerations, abrasions or fractures-Tears of the labial or lingual frenula-Oral mucosa torn from gingiva-Loosened, fractured or avulsed teeth-Darkened and/or nonvital teeth-Previously missing teeth-Trauma to the lip-Trauma to the tongue-Other soft tissue injuries-Fractures of jaws and associated structures-General neglect of the mouth (Kenney and Spencer, 1995; Vale, 1997).

The Innocenti Research Center of UNICEF in Florence did a thorough research and reported that in the industrialized countries 3.500 children under 15 years old are abused and die each year. Interesting enough is the fact that in Germany and Great Britain two children who get abused die every week, three in France, four in Japan and in the United States about twenty-four every week. (Report of Innocenti Research Center of Unicef in Florence, September 2003).

Taking into account these numbers we understand that the role of dentist is of great importance as he has a unique opportunity and ethical obligation to assist in the struggle against child abuse because most of the abused children suffer injuries to the face and head including oral and perioral regions. Indeed it was reported that 23% of head and neck injuries that were not caused by

automobile accidents were attributed to the domestic violence and 94% of domestic violence victims had head or neck injuries or both (Love *et al.*, 2001). The dentist can detect the injuries during the treatment or even before having the child seated. The evidence of severe or repeated trauma should arouse the dentist to the possibility of child abuse. As crying and speaking are produced from the mouth, this area is frequently the attack in cases of violent child abuse. Dentists should aid in the fight against child abuse because high percentage of the abused children are injured to the face and head, including oral and perioral regions.

## CONCLUSION

Dentists should understand that child abuse cause oral and dental injuries and so they should be able to observe charily recognize the signs and document them explicitly. Appropriate knowledge should be provided to the dentists and also the dentists should make the patient feel confident so as to reveal more information about the abuse or disclose it immediately. When the dental professionals understand the magnitude and the seriousness of the problem they will take their role seriously because the abused child does not only suffer but most of the times die.

## REFERENCES

- Kenney, J.P. and D.E. Spencer, 1995. Manual of Forensic Odontology. In: DNA and Forensic Odontology, Bowers, C.M. and G.L. Bell (Eds.). American Society of Forensic Odontologists, UK., pp: 191-199.
- Love, C., B. Gerbert, N. Caspers, A. Bronstone, D. Perry and W. Bird, 2001. Dentists attitudes and behaviors regarding domestic violence. JADA, 132: 85-93.
- Misawa, S., 2001. Feature: Child abuse and what dentists can do. Forensic Odontol. Today JFOC., 5: 1-1.
- Mouden, L.D., 1998a. The Dentist's role in detecting and reporting abuse. Quintessence Int., 29: 452-455.
- Mouden, L.D., 1998b. The role for dental professionals in preventing child abuse and neglect. J. California Dental Assoc., 26: 737-737.
- Stavrianos, C. and M.E. Metska, 2002. Dentistry's role in detection and prevention of child abuse and neglect. (in Greek), pp: 82-88.
- Stavrianos, C., 2009. Forensic Dentistry. 1st Edn., Vol. 1-2, University Studio Press, Thessaloniki, pp: 45-98.
- Stavrianos, C., M.E. Metska and N. Petalotis, 2005. Child abuse: It's recognition by dentists. Balkan J. Stomatol., 9: 204-207.
- Vale, G.L., 1997. Dentistry's Role in Detecting and Preventing Child Abuse. In: Forensic Dentistry, Stimson, P.G. and C.A. Mertz (Eds.). 1st Edn., CRC Press, Boca Raton, New York, pp: 161-162.