

Chronic Ethanol Administration Reduces Neuronal Cells Population in the Lateral Geniculate Body and the Superior Colliculus of Adult Wistar Rats (*Rattus norvegicus*)

¹P.B. Fakunle, ¹A.J. Ajibade, ²L.O. Ehigie, ¹O.A. Alamu and ¹E.A. Ashamu
¹Department of Anatomy, ²Department of Biochemistry,
Ladoke Akintola University of Technology, Ogbomoso, Nigeria

Abstract: Alcohol abuse and misuse has been widely reported to impair vision with majority of information available implicating the retina but with very scanty literature laying emphasis on the visual relay centers. Hence, some effects of chronic administration of ethanol was studied on the neuronal cells population in the visual relay centers Lateral Geniculate Body (LGB) and Superior Colliculus (SC) of 40 adult Wistar rats of both sexes grouped into treatments T₁ and T₂ and controls C₁ and C₂. The treatment groups received 25% ethanol in 2% sucrose (*ad libitum*) for 6 weeks except T₂ animals that were made to undergo an additional 2 weeks of ethanol withdrawal period while the control groups C₁ and C₂ received tap water and 2% sucrose solution, respectively for 6 weeks. At the end of administration, the animals were sacrificed and process for routine histological techniques and stained for nissl substances. Body weight loss was significantly ($p < 0.05$) observed as well as significantly ($p < 0.05$) reduced neuronal cells population of 47 and 40% for LGB and 42 and 38% for SC neuronal loss, respectively in treatment groups T₁ and T₂ compared to control group. Hence, these alterations may again underline visual imbalance associated with the malfunctioning of the visual relay center most especially in the maintenance of saccade and recoding of visual signals which are postretinal related functions.

Key words: Ethanol, vision, superior colliculus, lateral geniculate body, Wistar rats, Nigeria

INTRODUCTION

The intemperance in the use of alcohol has created many problems in the modern society, the important of which can be judged by the repeated emphasis they received in contemporary publications both literary and scientific (Thun *et al.*, 1997). However, overindulgence in ethanol consumption which has always culminated into chronic alcohol consumption has been a problem of public health concern as it provides the basis for alcoholism which is a chronic disease (Fakunle *et al.*, 2011).

This is generally characterized by a loss of control over use of alcohol and an inability to modify drinking in spite of harmful health consequences (Jyrki, 2002). However, more neurological disorders have been linked to ethanol than any other drug, toxin or environmental agent (Charness *et al.*, 1989) as it has been estimated that 9% alcohol-dependent individuals have clinically diagnosable organic brain syndrome with 50-70% of alcoholics displaying significant cognitive impairment (Eckardt and Martin, 1986). In the brain, ethanol acts on neuronal and glial membrane containing

protein and lipid molecule (Lovinger, 1993; Joyce, 1994; People *et al.*, 1996; Synder, 1996). In the glia cell, ethanol could promote the production of cytotoxic cytokines which could damage neuronal structure directly or indirectly through an autoimmune response indicated by macroglia/macrophage cell or astrocytes (Lancaster, 1993; Synder, 1996). The formation of Nitric Oxide (NO) has been linked to increased performance for and tolerance for alcohol in recent studies (Zima *et al.*, 2001). The comparison of chronically fed rats and controls demonstrates that exposure to ethanol causes a decrease in NADPHd (Nicotinamied Adenine Dinucleotide Phosphate diaphorase) activity and neuronal NOS (Nitric Oxide Synthase) in the neurons and fibres of the superior colliculus and cerebellum (Zima *et al.*, 2001) and even in the dorsal lateral geniculate nucleus.

In acute exposure model of fetal alcohol syndrome, effect of acute exposure to ethanol on postnatal optic nerve have been examined in pregnant mouse (5B1/6) mode and it was established that there was no significant difference between experimental and control animals in the neuronal population of dorsal lateral geniculate nucleus and superior colliculus (Ashwell and Zhang, 1994).

Although, this is suggestive of the fact that the axonal deficit is due to direct retinal damage than increased postnatal axonal loss arising from retinorecipient nuclei damage hence, chronic administration of ethanol was investigated in the visual relay centers of lateral geniculate body and superior colliculus in this study using adult rat model.

MATERIALS AND METHODS

All animal experiments were performed using the protocol approved by the Animal Care and Use Committee of Obafemi Awolowo University, Ile-Ife, Nigeria. The experiment was performed on 40 adult wistar rats of both sexes age 2 months (190-200 g). The animals were housed at constant room temperature 20-22°C. Food (Standard Laboratory mouse chow from Ladokun feeds, Ibadan, Nigeria) and water were available *ad libitum*. Previous to the experiment, all animals were subjected to an acclimatization period of 14 days after which they were randomly distributed into 4 groups (n = 10) of experimental T1 and T2 and control C1 and C2. Groups T1 and T2 received 25% ethanol in 2% sucrose solution as their drinking water while the animals in group C1 and C2 received tap water and 2% sucrose solution, respectively as their drinking water, all for a period of 6 weeks. The animals in group T2 continued with tap water for another 2 weeks following the replacement of their 25% ethanol in 2% sucrose solution as the withdrawal period. Daily consumption of ethanol was monitored and determined by fresh replacement at 20.00 h GMT.

Body weight, feeding and ethanol consumption pattern were also determined. At the end of ethanol administration, the rats were sacrificed by whole body intracardiac perfusion fixation under gravity using 10% formol calcium fixative. The rate of fixation was monitored by decolouration of the tongue and eyeballs after which the skull was then opened and the brain was removed en-mass and the regions of LGB and SC were trimmed out using the stereotaxis coordinate method of Paxinos and Watson (1998). The tissue specimens were then processed for routine histological techniques and stained for nissl's substance using cresyl violet as previously described by Venero *et al.* (2000). Qualitative observations of stained sections were done with every 10th section chosen from each animal. Using brightfield compound Nikon microscope, YS100 (attached with Nikon camera), the slides were examined under 400X objective. Using Image-Pro Express software, counts of neurons with prominent nucleolus were done. The neuronal transverse diameter of the stained sections were also

determined. The absolute neuronal density per unit area of section for each region was estimated as described by Abercrombie (1946).

Statistical analysis: The data were analyzed using the computerized statistical package SPSS Version 11. Mean and Standard Error of Mean (SEM) values for each group was determined. The means were compared by analysis of variance at a level of significance of 95 and 99%.

RESULTS AND DISCUSSION

There was a gradual weight loss in the treatment groups T1 and T2 from the 2nd week (Fig. 1), these changes were also significant (p<0.05) compared to a gradual weight gain in the controls throughout the experiment. The ethanol consumption curves (Fig. 2) for the treatment groups T1 and T2 showed the same pattern of ethanol intake although with lower volume of ethanol consumption. The curve revealed a brief initial drop in the consumption followed by a steady rise in the rate of consumption which continued throughout the duration of ethanol administration.

Ethanol severely and significantly (p<0.01) (Table 1) depressed feeding in the treatment groups T1 and T2 with Mean±SEM (103.0±9.3 and 103.0±8.4) g, respectively and significantly at (p<0.01) (Table 1) compared to the control groups C1 and C2, Mean±SEM (130.0±10.6 and 126.0±9.4) g. The morphometry results obtained from Table 2 clearly showed that treatment groups T1 and T2 had significantly (p<0.05) reduced neuronal density of Mean±SEM of (365.16±11.56 and 326.61±11.63)/m⁻², respectively and which translates to a percentage neuronal loss of 47 and 40% in the LGB while (311.06±12.04 and 326.61±11.63)/m⁻², respectively and which translates to a percentage neuronal loss of 42 and 38% in the SC. Although, reduced neuronal density was also noticed in

Table 1: Mean±SEM of feed consumed at the end of administration

Groups	N	Mean±SEM (g)	D.O.F	2-Prob
T1	10	103.0±9.30*	10.2	0.004
T2	10	103.0±8.40*	-	-
C1	10	130.0±10.6	-	-
C2	10	126.0± 9.4	-	-

*Significant at (p<0.01)

Table 2: Mean±SEM (neuronal density)

Groups	Neuronal cells cm ⁻¹	Neuronal loss (%)
C1	ξ650.10±10.13	-
	¶536.22±10.19	-
C2	ξ643.27±21.11	1
	¶529.06±12.20	1
T1	ξ365.16±11.56*	47
	¶311.06±12.04*	42
T2	ξ391.25±21.06*	40
	¶326.61±11.63	38

*Significant difference p<0.05 when compared to the control; ξ Values for LGB; ¶ Values for SC

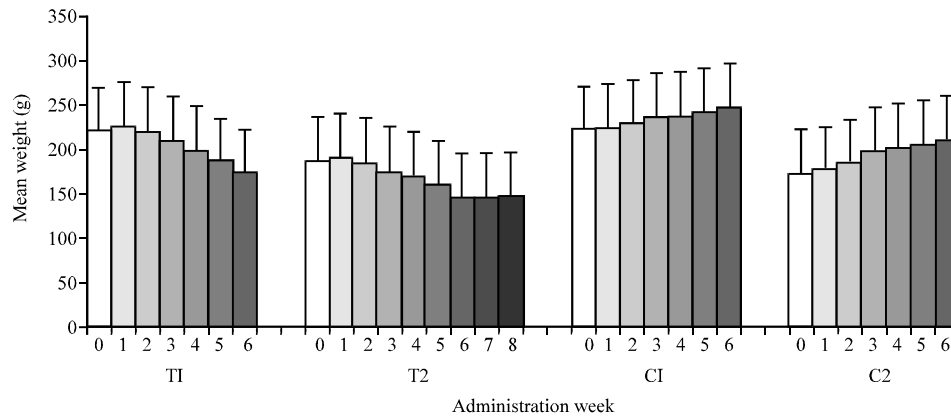


Fig. 1: Histogram of body weight (Mean±SEM) g distribution at the end of administration

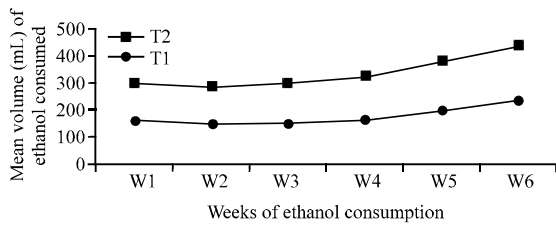


Fig. 2: Ethanol consumption curve

the control section C2 with Mean±SEM of (643.27±21.11 and 529.06±12.20)/m⁻², respectively for LGB and SC compared to the control group C1 with neuronal density of Mean±SEM of (650.10±10.13 and 536.22±10.19)/m⁻², respectively for LGB and SC which translate in both organs into an insignificant p>0.05 1% neuronal loss.

The results of this study confirmed that chronic intake of ethanol has a deleterious effect on the body weight and neuronal density and thus confirming the earlier reports of Lancstar (1993), Pfefferbaum *et al.* (1993, 1997) and Thun *et al.* (1997). Ethanol can be administered in drinking water or by intragastric intubation or intraperitoneally or by vapor as well as in liquid diet. The control animals in groups C1 and C2 displayed an insignificant (p>0.05) weight gain throughout the experimental period (Fig. 1). This was not so for the animals in the treatment groups T1 and T2 as weight gain was seen in the first 2 weeks which was followed by gradual weight loss throughout the experiment duration especially for T1 animals although, the T2 animals showed some slight weight gain at the end of the 2 weeks of withdrawal period. Hence, the subsequent slow recovery was due to the administered ethanol. Also there is a correlation with the pattern of ethanol consumption (Fig. 2) which increased steadily from 2nd week of administration and the pattern of feed

consumption as shown in Table 1 where ethanol severely depressed feeding most especially in the treatment groups T1 and T2.

Although, ethanol has a relatively high caloric value, 7.1 calories g⁻¹ (as a point of reference, 1 g of carbohydrate contains 4.5 calories and 1 g of fat contains 9 calories), ethanol consumption does not necessarily result in increased body weight. This is quite evident in the earlier reports of Weenberg (1984) that despite normal calories in the diet, ethanol significantly reduces weight gain whether or not ethanol calories are considered as a contributor to the dietary total. An analysis of data collected from the first National Health and Nutrition Examination Survey (NHANES1) found that although, drinkers had significant higher intake of total calories than non-drinkers, drinkers were not more obese than non-drinkers. Gruchow *et al.* (1985) has affirmed that as ethanol intake among men increases, their body weight decreases.

Although, moderate dose of ethanol added to the diets of lean men and women do not seem to lead to weight gain as some studies have reported weight gain when ethanol is added to the diet of overweight persons (Clevidence *et al.*, 1995). The fact that alcohol also inhibits the breakdown of nutrients into usable substances by decreasing the secretion of digestive enzymes from the pancreas as reported by Leiber can also point to possible mechanism suggesting implication of ethanol consumption as regards weight loss. One of the suggested mechanisms by which chronic ethanol exposure can cause neuronal distortion is through the formation of acetaldehyde (Hunt, 1996). Although, acetaldehyde is 10 times toxic than ethanol, there is as yet no evidence that any biologically relevant form of acetaldehyde can enter the brain from circulation or be produced by ethanol metabolizing enzymes *in situ*

(Lindros, 1978). The lack of acetaldehyde in the CNS has been attributed to an efficient blood-brain barrier to acetaldehyde or the low capacity of enzymes such as alcohol dehydrogenase, catalase or CYP450IIE1 to metabolize ethanol in the brain (Coon and Koop, 1987; Hansson *et al.*, 1990).

One of the possible mechanisms by which ethanol could produce brain tissue alteration is through the formation of covalent bonds with brain proteins, thereby producing Acetaldehyde Protein Adducts (APA) which in turn, might trigger an autoimmune response similar to that found in peripheral tissues (Isreal *et al.*, 1986). Hence, reduced neuronal density seen in this research as shown in Table 2 can be said to be due to effects of chronic ethanol consumption. Neuroglia are present between the neurons of LGB and SC (Friedlader *et al.*, 1981). Their interaction with neurons play vital role in adult brain (Gueric *et al.*, 2001) and their sparse distribution as reported in the earlier research of Lancaster (1993) and Synder (1996) can also compromise their support functions.

The slight onset of neuronal regeneration as seen in group T2 that underwent withdrawal period Table 2 points to the possibilities of cellular rearrangements which if continued with total abstinence may lead to restoration cellular integrity and this is in conformity with the earlier reports of the deleterious effects of ethanol on the lateral geniculate body and superior colliculus observed in this study may underline the visual incompetence following chronic ingestion of ethanol. The lateral geniculate body and superior colliculus (Notback and Demarest, 1981) control visual acuity, accommodation and papillary reflexes.

CONCLUSION

Ethanol is widely used, misused and abused worldwide and efforts and attention had been drawn to its effects on the general well being of the body in recent times. This study had shown that ethanol causes significant acute weight loss with increased consumption. The microanatomical changes observed in the visual relay centres, lateral geniculate body and superior colliculus was discussed in the light of neuronal distortion and scanty neuroglia distribution.

REFERENCES

Ashwell, K.W. and L.L. Zhang, 1994. Optic nerve hypoplasia in acute ethanol exposure model of fetal rat. *J. Neurotoxicol. Teratol.*, 16: 161-167.
Charness, M.E., R.P. Simon and D.A. Greenberg, 1989. Ethanol and nervous system. *N. Eng. Med.*, 321: 442-454.

Clevidence, B.A., P.R. Taylor, W.S. Campbell and J.T. Dudd, 1995. Learn and heavy women may not use energy form alcohol with equal efficiency. *J. Nutr.*, 125: 2536-2540.
Coon, M.J. and D.R. Koop, 1987. Alcohol widicible cytochrome P-450 (P-450ALC). *Arch. Toxicol.*, 60: 16-21.
Eckardt, M.J. and P.R. Martin, 1986. Clinical assessment of cognition in alcoholism. *Alcohol Clin. Exp. Res.*, 10: 123-127.
Fakunle, P.B., F.A. Fakoya and P.D. Shallie, 2011. Impairment activities of succinic dehydrogenase in the lateral geniculate body and superior colliculus of adult wistar rats (*Rattus norvegicus*) as a result of long term intake of ethanol consumption. *J. Neurosci. Behav. Health*, 3: 57-65.
Friedlader, M., C.S. Lin, L.R. Stanford and S.M. Sherman, 1981. Morphology of functionally identified neutrons in Lateral geniculate body of the Cat. *J. Neurophysiol.*, 46: 80-129.
Gruchow, H.W., K.A. Sobocinski, J.J. Barboriak and J.G. Scheller, 1985. Alcohol consumption, nutrient intake and relative body weight among US adults. *Am. J. Cincinal Ntrition*, 42: 289-295.
Gueric, C., M. Pascual and J. Renau-Piqueras, 2001. Glia and fetal alcohol syndrome. *Neurotoxicology*, 22: 304-312.
Hansson, T., N. Tindberg, M. Ingelman-Sundberg and C. Kohler, 1990. Regional distribution of ethanol-inducible cytochrome P450 IIE1 in the rat central nervous system. *Neuroscience*, 34: 451-463.
Hunt, W.A., 1996. Role of acetaldehyde in the actions of ethanol on the brain-A review. *Alcohol*, 13: 147-151.
Isreal, Y., E. Hurwitz and R. Amon, 1986. Monoclonal and polylonal antibodies against acetaldehyde-containing epitopes in acetaldehyde-protein adducts. *Proc. Nad Acad. Sci.*, 83: 7923-7927.
Joyce, E.M., 1994. Etiology of Alcohol brain damage: Alcoholic neurotoxicity or thiamine malnutrition? *Br. Med. Bull.*, 50: 99-114.
Jyrki, R., 2002. Neuropathology of aging and long-term ethanol consumption. Ph.D. Thesis, University of Tampere.
Lancaster, F.E., 1993. Ethanol and White Mater Damage in the Brain. In: *Alcohol-Induced Brain Damage*. Hunt, W.A. and S.J. Nixon (Eds.). NIAAA Research Monograph No. 22, US Government Printing Office, Rockville, pp: 387-399.
Lindros, K.O., 1978. Acetaldehyde: Its metabolism and role in the actions of alcohol. In: *Research advances in alcohol and drug problems*, Israel, Y., F.B. Glaser and H. Kalant (Eds.). Plenum Press, New York, pp: 111-176.

- Lovinger, D.M., 1993. Excitotoxicity and alcohol-related brain damage. *Alcohol Clin. Exp. Res.*, 17: 19-27.
- Notback, R. and A. Demarest, 1981. *The Human Nervous System, Basic Principles of Neurology*. 3rd Edn., McGraw-Hill International Book Company, Japan, pp:413-435.
- Paxinos, G. and C. Watson, 1998. *The Rat Brain in Stereotaxic Coordinates*. Academic Press, London.
- People, R.W., C. Li and F.F. Weight, 1996. Lipid vs protein theories of alcohol actions in the nervous system. *Annu. Rev. Pharmacol. Toxicol.*, 36: 185-201.
- Pfefferbaum, A., E.V. Sullivan, D.H. Mathalon and K.O. Lim, 1997. Frontal lobe volume loss observed with magnetic resonance imaging in older chronic alcoholics. *Alcohol Clin. Exp. Res.*, 21: 521-529.
- Pfefferbaum, A., E.V. Sullivan, M.J. Rosenbloom, P.K. Shear, D.H. Mathalon and K.O. Lim, 1993. Increase in brain cerebrospinal fluid volume is greater in older than in younger alcoholic patients: A replication study and CT/MRI comparison. *Psychiatry Res.*, 50: 257-274.
- Synder, A.K., 1996. Responses of Glia to Alcohol. In: *The Role of Glia in Neurotoxicity*, Schner, M.A. and H.K. Kimelberg (Eds.). C.R.C. Press Boca Raton, USA., pp: 111-129.
- Thun, M.J., R. Peto, A.D. Lopez, J.H. Monaco, S.J. Henley, C.W.Jr. Health and R. Doll, 1997. Alcohol consumption and mortality among middle-aged and elderly U.S. adults. *N. Engl. J. Med.*, 337: 1705-1714.
- Venero, J.L., M.L. Vizuete, M. Revuelta, C. Vargas, J. Cano and A. Machado, 2000. Upregulation of BDNF mRNA and trkB mRNA in the nigrostriatal system and in the lesion site following unilateral transection of the medial forebrain bundle. *Exp. Neurol.*, 161: 38-48.
- Weenberg, C.S., 1984. Does alcohol calories count? *Am. J. Clin. Nutr.*, 54: 972-975.
- Zima, T., L. Fialova, O. Mestek, M. Janebova and J. Crkocska *et al.*, 2001. Oxidative stress, metabolism of ethanol and alcohol-related diseases. *J. Biomed. Sci.*, 8: 59-70.