

Broad Ligament Pregnancy: A Case Report

¹Zahra Naeiji, ²Maasoumeh Saleh and ¹Elham Keshavarz
¹Mahdijeh Hospital,
²Department of Gynecology and Obstetric,
Shahid Beheshti University of Medical Sciences, Tehran, Iran

Abstract: Abdominal pregnancy is an extremely rare type of ectopic pregnancy with potential life threatening complications if not diagnosed and treated early enough. We present a case and ultrasound image of broad ligament pregnancy who was successfully treated with surgery.

Key words: Surgery, ectopic pregnancy, abdominal pregnancy diagnosed, complications, image

INTRODUCTION

Abdominal pregnancy is an extremely rare condition. It may account for up to 1.4% of ectopic pregnancies (Atrash *et al.*, 1987; Fisch *et al.*, 1996). While rare, it have a higher mortality rate than other ectopic pregnancies. Abdominal pregnancies refer to those with extrauterine implantations in omentum, vital organs or large vessels. Implantations have been reported in the cul-de-sac, broad ligament, bowel and pelvic sidewal (Dover and Powell, 1995; Varma, 2003; Ludwing *et al.*, 1999). There are two types of abdominal pregnancy: primary and secondary. A primary abdominal pregnancy refers to a pregnancy that implanted directly in the abdominal cavity. Typically an abdominal pregnancy is a secondary implantation which means that it originated from a tubal pregnancy and reimplanted. Risk factors include tubal damage, pelvic inflammatory disease, endometriosis, assisted reproductive techniques and multiparity (Ludwing *et al.*, 1999; Tsudo *et al.*, 1997). A patient with an abdominal pregnancy may have non-specific symptoms such as abdominal pain, nausea, vomiting and less frequently vaginal bleeding. The diagnosis is often made using ultrasound and x-ray. Diagnostic laparascopy may also be of value when there is a doubt about pregnancy location (Morita *et al.*, 1996). In some cases, the diagnosis is not made until laparotomy (Onan *et al.*, 2005). The diagnosis is frequently missed despite the routine use of ultrasound. We report a broad ligament pregnancy with gestational age of 13 weeks that resected successfully by abdominal laparotomy.

Case report: A 42 years old woman, gravida 4 with history of three natural vaginal delivery at full term presented to our hospital with abdominal pain. Gestational

age of pregnancy according to last menstrual period was 14 weeks and 4 days. Her pregnancy was intended and she did not any contraception. The patient did not check serum B-HCG after menstrual retardation but also had a sonography in early period of pregnancy. She presented with mild, gradual onset colicky abdominal pain in left lower quadrant of abdomen since, 2 days prior to coming to our center and her symptom was progressed since morning of admission. In this period, she did not have any vaginal bleeding, nausea, vomiting and other symptoms. Due to abdominal pain, transvaginal ultrasound was done for her outpatient one day and also several hours prior to coming to our hospital that showed ectopic pregnancy and due to its result referred here. Baseline transvaginal ultrasound, after menstrual retardation showed a gestational sac in uterus cavity, with diameter of 5 mm and gestational age of <4 weeks without yolk sac and fetal pole and also normal adnexa. A repeat transvaginal ultrasound after 2 months, 1 day prior to coming hospital showed a fetus with heart rate, gestational age of 12 weeks and CRL: 12 mm, NB: 2.5 mm, NT: 1 mm, probably female gender in left adnexa. In this ultrasound, uterus was well defined and without gestational sac and right adnexa was normal. No free fluid was detected in abdominopelvic cavity. The other repeat transvaginal ultrasound after one day confirmed a heart rate positive fetus in left adnexa with gestational age of 13 week and 1 day, CRL: 70 mm and placenta in posterior site. Transvaginal ultrasound in our center showed a well defined uterus with endometrial thickness: 11 mm and a heart rate positive fetus in left adnexa, gestational age of 13 weeks and 4 days, in favor of tubal ectopic pregnancy. No free fluid was detected. On arrival, her vital sign was stable and had tenderness and rebound tenderness in left lower quadrant of abdomen. Speculum exam did not show any bleeding and in bimanual examination a tender mass

(approximately 10×20 cm) palpated in left adnexa. Due to acute abdomen and with diagnosis of tubal pregnancy, laparotomy was done for her.

Operation: Patient was draped and prepared in usual manner. Under general anesthesia, Pfannenstiel incision was made and the peritoneal cavity was opened. Pelvic viscera explored. A large well defined mass (approximately 15×20 cm) without active bleeding detected in left broad ligament (mesosalpinx) adjacent to left adnexal tube. The left tube was impaired and it seems that abdominal pregnancy was originate from the adnexal tube (secondary type). This mass was resected, then left salpingectomy and right tubal ligation was done. Resected mass was opened and a fetus with placenta was seen. The abdomen was closed in anatomical layers. Patient was returned to recovery room in good condition.

MATERIALS AND METHODS

Pathology report

Macroscopic examination: A discoid brown placenta partly covered by membranes measuring 10×6×3 cm, laterally attached umbilical cord measuring 11×0.5 cm, containing three vessels attached oviduct measuring 7×1.3 cm with a male fetus measuring 8 cm in CRL, 6 cm in head circumference and 2 cm in femur length. No grossly visible pathologic change is seen.

Microscopic examination in left oviduct and its content with fetus: Oviduct with ectopic pregnancy, umbilical cord with three vessels, unremarkable parenchyma and membranes. Written informed consent was obtained from the patient to publish this case (Fig. 1-8). It is a video showing a short time of operation.

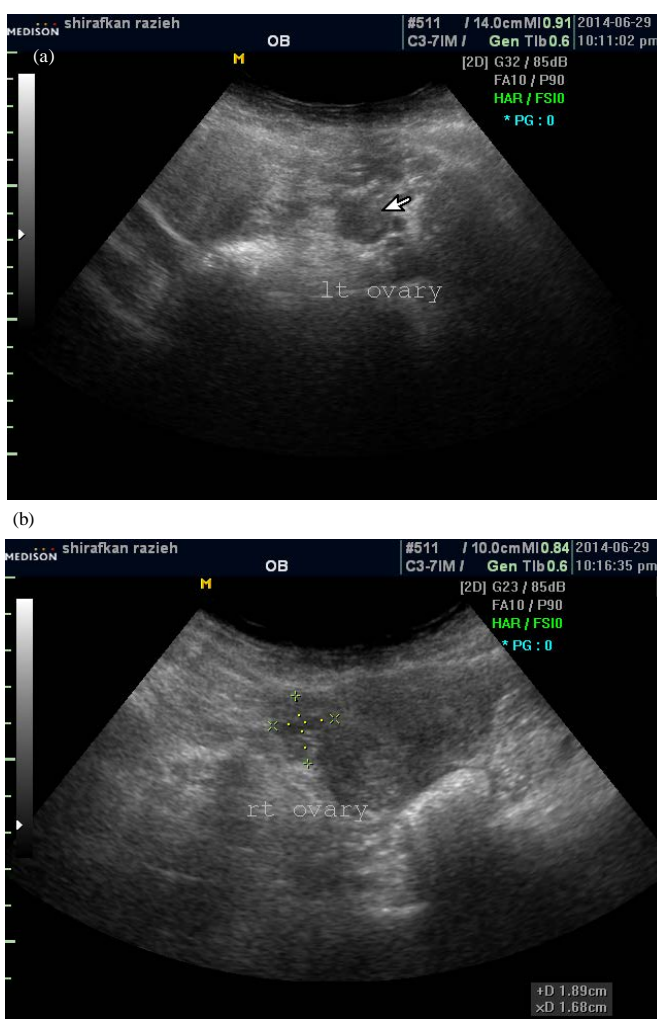


Fig. 1: Left ovary showed in this view

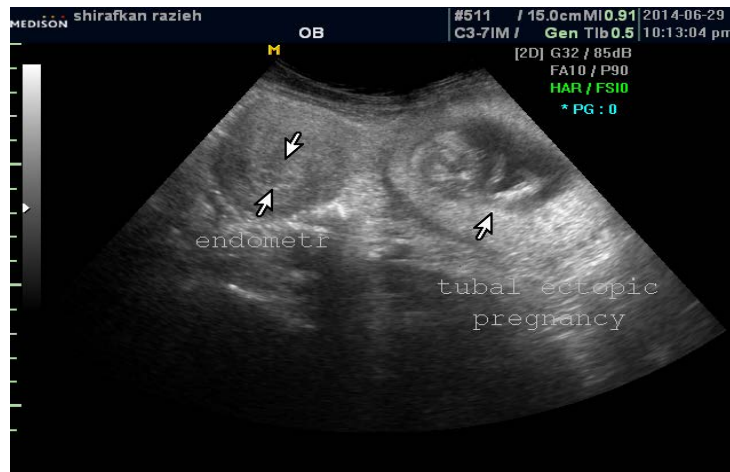


Fig. 2: Uterus and ectopic pregnancy in left adnexa showed in this view

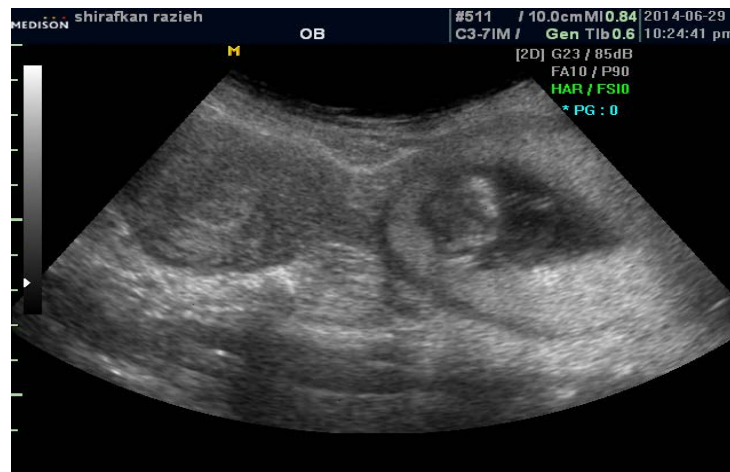

Fig. 3: Uterus and ectopic pregnancy in left adnexa in larger view

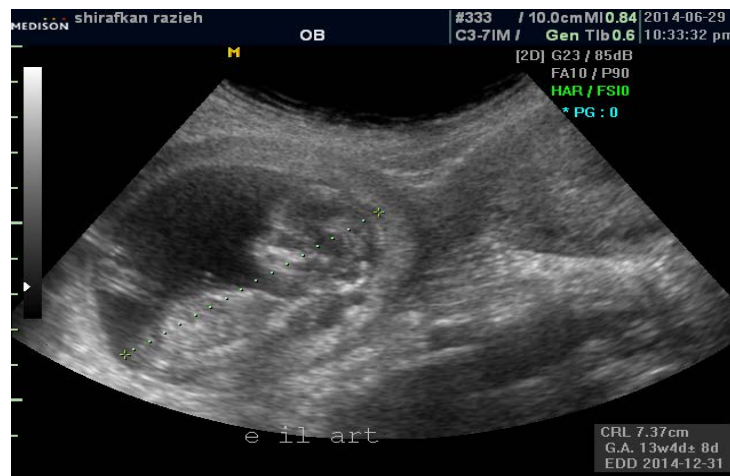

Fig. 4: The fetus in left adnexa with CRL

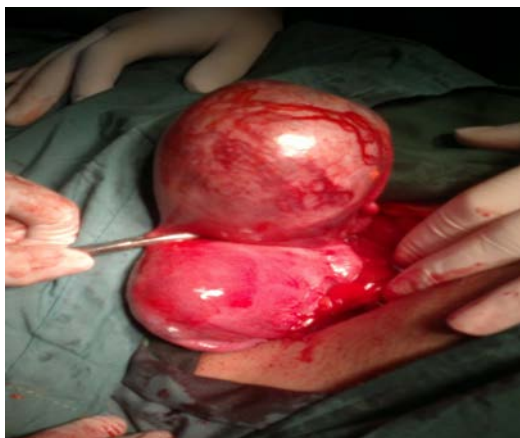


Fig. 5: Ectopic pregnancy mass during operation showed in this picture grossly

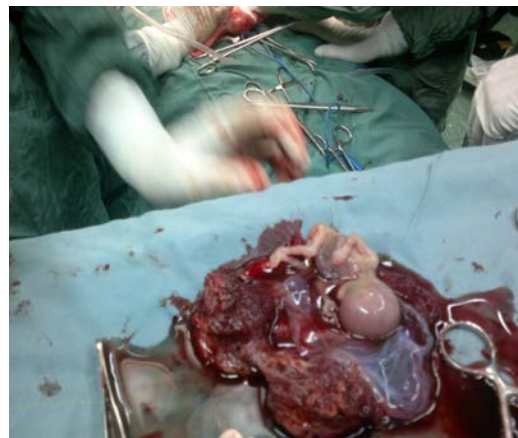

Fig. 8: The fetus after resection and rupture of amniotic membrane

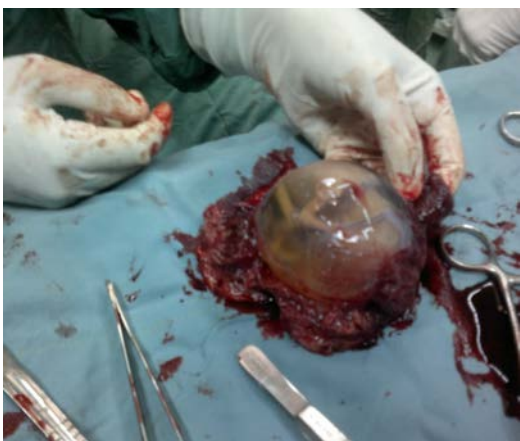

Fig. 6: This picture shows fetus in gestational sac and placenta in posterior side after resection

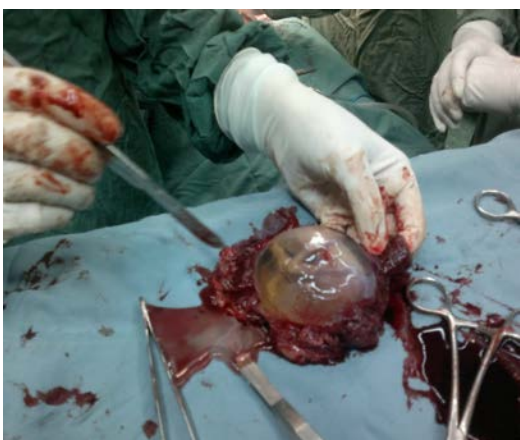

Fig. 7: The other view of resected mass

RESULTS AND DISCUSSION

The incidence of abdominal pregnancy appears to be increasing in both developed and developing countries. In our patient, the fetus was implanted in broad ligament (Crabtree *et al.*, 1994). The uterus was empty and the gestational sac showed evidence of fetal heart rate in three different ultrasounds. Our patient presented with abdominal pain. Ultrasound diagnosed, it as a tubal pregnancy because it was near to tube but broad ligament pregnancy diagnosed at laparotomy. Most cases of broad ligaments pregnancy were diagnosed in the first and early srcond trimester (Paternoster and Santarossa, 1999; Morita *et al.*, 1996; Siow *et al.*, 2004; Apantaka *et al.*, 2006; Phupong *et al.*, 2001; Deshphande *et al.*, 1999). In our case, diagnosis was made in the second trimester. Abdul *et al.* (2008) reported two broad ligament pregnancies with gestational ages of 22 weeks and 6months that diagnosed at laparotomy. Atis *et al.* (2014), a left broad ligament pregnancy (8 weeks) who presented with acute abdomen and mass resected by laparotomy 16. Apantaka *et al.* (2006) reported a case of broad ligament pregnancy following *in vitro* fertilization in a patient with previous bilateral salpingectomy. Nalinee *et al.* (1999) reported a case of left broad ligament twin pregnancies with heart rate, 7 weeks, following *in vitro* fertilization with history of left salpingo-oophorectomy due to endometriosis. Denke (1997) reported a term broad ligament pregnancy (3000 g) in an Ethiopian nulliparous mother who presented with antepartum hemorrhage and underwent surgery for a suspected placenta previa. Heterotopic pregnancy involving the broad ligament has been reported (Atalla *et al.*, 1997).

Broad ligament pregnancy is a life threatening condition, if not diagnosed and treated early, So this is required that ectopic pregnancy was included in differential diagnosis of women presenting with vaginal bleeding and abdominal pain for early diagnosis and treatment. Treatment choice of broad ligament pregnancy is laparotomy with excision of pregnancy products. In our case, the fetus grewed in the left broad ligament. Because, it was not tubal pregnancy, the patient did not have any symptom till second trimester and also because the gestational sac was adjacent to adnexal tube in mesosalpinx, the ultrasound showed it as a tubal pregnancy. Diagnosis left broad ligament ectopic pregnancy.

CONCLUSION

Ectopic pregnancy must always be considered in patients of child-bearing age and abdominal pregnancy should include in differential diagnosis of tubal pregnancy especially in advanced gestational ages.

REFERENCES

- Atrash, H.K., A. Friede and C. Hogue, 1987. Abdominal pregnancy in the united states: frequency and maternal mortality. *Obstet. Gynecol.*, 69: 333-337.
- Apantaka, O., P. Rana and T. Inglis, 2006. Broad ligament ectopic pregnancy following *in vitro* fertilization in a patient with previous bilateral salpingectomy. *J. Obstet. Gynecol.*, 26: 474.
- Abdul, M.A., A.M. Tabari, D. Kabiru and N. Hamidu, 2008. Broad ligament pregnancy: A report of two cases. *Annals of African Medicine*, 7 (2): 86-87.
- Atis, A., O.D. Gunduz, T. Karacan and A. Kublay, 2014. A rare form of ectopic pregnancy on mesoovarium; Case report. *J. Clin. Case Rep.*, 4: 5.
- Atalla, R.K., P.C. Murphy and C. Balachadar, 1997. Combined intrauterine and broad ligament ectopic pregnancy. *J. Obstet. Gynecol.*, 17: 203.
- Crabtree, K.E., B. Collet and S.J. Kilpatrick, 1994. Puerperal presentation of a living abdominal pregnancy. *Obstet. Gynecol.*, 84 (4pt2): 646-648.
- Denke, F., 1997. Advanced abdominal pregnancy in an Ethiopian mother. *East Afr. Med. J.*, 74: 535-536.
- Deshphande, N., A. Matters and U. Acharya, 1999. U. Broad ligament twin pregnancy following *in vitro* fertilization. *Hum Reprod.*, 14: 854.
- Dover, R.W. M.C. Powell, 1995. Management of a primary abdominal pregnancy. *Am. J. Obstet. Gynecol.*, 172: 1603-1604.
- Fisch, B., Y. Peled, B. Kaplan, S. Zehavi, A. Neri, 1996. Abdominal pregnancy following in vitro fertilization in a patient with previous bilateral salpingectomy. *Obstet. Gynecol.*, 88 (44): 642-643.
- Ludwing, M., M. Kaisi, O. Bauer and K. Diedrick, 1999. The forgotten child-a case of heterotopic, intraabdominal and intrauterine pregnancy carried to term. *Hum Reprod.*, 14 (5): 1372-1374.
- Morita, Y., O. Tutsumki, K. Kuramochi, M. Momoeda, H. Yoshikawa and Y. Tuketani, 1996. Successful laparoscopic management of primary abdominal pregnancy. *Hum Reprod.*, 11 (11): 2546-2547.
- Nalinee, D., A. Mathers and U. Acharya, 1999. Broad ligament twin pregnancy following *in vitro* fertilization: A case report. *Hum Reprod.*, 14 (3): 852-854.
- Onan, M.A., A.B. Turp, A. Saltik, N. Akyurell, C. Taskiran, O. Himmetoglu, 2005. Primary omental pregnancy: case report. *Hum Reprod.*, 20 (3): 807-809.
- Phupong, V., P. Tekasakal and K. Kankaew, 2001. Broad ligament twin pregnancy: A case report. *J. Reprod. Med.*, 46: 144-146.
- Paternoster, D.M. and C. Santarossa, 1999. Primary abdominal pregnancy: a case report. *Minerva Ginecol.*, 51: 251-253.
- Siow, A., B. Chern, Y. Soong, 2004. Successful laparoscopic treatment of an abdominal pregnancy in the broad ligament. *Singapore Med. J.*, 45: 88-89.
- Tsuda, T., T. Harada, H. Yoshioka and N. Terakawa, 1997. Laparoscopic management of early unruptured abdominal pregnancy. *Obstet. Gynecol.*, 90 (4): 687-688.
- Varma, R., 2003. Mascarenhas R, Jame D. Successful outcome of advanced abdominal pregnancy with exclusive omental resection. *Ultrasound Obstet. Gynecol.*, 21:192-194.