

## Local Inflammatory Reaction at Soft Tissue Defects Reconstruction

Vladimir F. Kulikovskiy, Alexander M. Mishustin, Andrei L. Iarosh,  
Alexander V. Soloshenko, Alexander A. Karpachev,  
Arman A. Oganesyan and Yurii Y. Vlasuk  
Belgorod State University, Pobeda 85, 308015 Belgorod, Russia

**Abstract:** The study analyzed the results of surgical treatment among 185 patients with postoperative ventral hernias. All patients were divided into two matched groups. The first group consisted of 128 patients who underwent the plastic operation of abdominal wall defect with the use of mesh prosthesis “Esfil light” (“linteks”, Russia). The second group included 57 patients with the plastic operation of abdominal wall defect using the mesh endoprosthesis “Esfil light” and TachoComb® was used additionally (RF patent number 2391051 “Ventral hernia treatment method”). It was found that use of the drug TachoComb® during the implantation of the mesh prosthesis “Esfil light” allowed to reduce significantly the severity of the inflammatory response in the area of operation which was characterized by lower level of pro-inflammatory cytokines TNF $\alpha$ , IL 1 $\beta$ , IL 6 and a higher level of anti-inflammatory cytokines IL 10 and IL 1RA in the wound fluid at all stages of the study.

**Key words:** TachoComb®, hernia, cytokines, linteks, Russia

---

### INTRODUCTION

Until recently, the issue that synthetic materials implants provoke adverse effects for the outcome of an operation was not discussed. Recently, however, literature started to provide increasingly the information about the fact that the implantation of mesh prosthesis triggers a cascade of complex histopathological processes which are a body's response to the introduction of a foreign body (Jacob *et al.*, 2007; Cavallaro *et al.*, 2010; Sergent *et al.*, 2010).

One of the possible ways improving the direct results of prosthetic plastic operation for anterior abdominal wall in our opinion is the creation of the most favorable conditions for rapid “implantation” of synthetic prostheses. This goal may be achieved using some biological material which is a kind of “shock absorber” in the process of an implant and body tissue contact. Recently literature started to describe experimental and clinical data on the respective use of amniotic membrane, cultural fibroblasts, collagen preparations, cellulose, silicone, biodegradable bacterial polymers, etc. (Baillie *et al.*, 2007; Tanaka *et al.*, 2007; Jacob *et al.*, 2007; Cavallaro *et al.*, 2010; Chavarriaga *et al.*, 2010; Petter-Puchner *et al.*, 2010).

We believe that the combined fibrin-collagen substance known as TachoComb® (Nycomed Austria GmbH) is an interesting and perspective one from this point of view. TachoComb® is used successfully and widely in

abdominal surgery during the operations in the parenchymal organs to achieve hemostasis. It was also used in lung surgery which not only the hemostatic effect of the drug but also an opportunity of aerostasis is used in cardiovascular surgery, urology, traumatology, gynecology, etc. (Rickenbacher *et al.*, 2009; Toro *et al.*, 2011; Yamaguchi *et al.*, 2013).

### MATERIALS AND METHOD

In this study, we analyzed the results of surgical treatment among 185 patients with postoperative ventral hernias. The patients were hospitalized in the Surgical Department No. 1 of Belgorod Regional Clinical Hospital of St. Joasaph in 2008-2011.

All patients were divided into two groups matched by sex, age, duration, localization of hernia, hernia defect size and the number of relapse in a group. The first group (PP) included 128 patients who underwent plastic operation of abdominal wall defect with the use of surgical mesh prosthesis made of polypropylene “Esfil light” (“linteks” Russia). The second group (PP+TachoComb®) included 57 patients with the plastic operation of abdominal wall defects by the mesh endoprosthesis “Esfil light”. The patients also used TachoComb®. At that the latter was laid on a fixed prosthesis, completely isolating it from subcutaneous cellular tissue (RF patent number 2391051 “Ventral hernia treatment method”).

All the patients experienced the plastic nonstrain operation according to “in lay” method. The place of prosthesis implantation was equipped with a drainage with an active aspiration according to Redon. In order to assess the local inflammatory response in the implantation area of an endoprosthesis, the concentrations of pro-inflammatory cytokines TNF $\alpha$ , IL: 1 $\alpha$ , 2, 6, 8 and anti-inflammatory cytokines IL-10 and IL 1 RA were determined on the 1st, 3rd, 7th and 10th days after implantation in wound fluid obtained from drainage or during puncture.

**RESULTS**

In the study of local cytokine status in the wound fluid of the first group Patients (PP) the significant changes in the level of IL 2, IL 6 and IL 1 RA were revealed. At that if the concentration of one of the major pro-inflammatory cytokine IL-6 was significantly increased (more than twice) during the 10th day the level of IL 1 and IL 2 RA were significantly reduced after the same period. It should be noted that the concentration of pro-inflammatory cytokines TNF $\alpha$ , IL 1 $\beta$ , 8 and 10 were quite high during the first day and were significantly higher than the norm and were not changed during the period of follow-up (Table 1).

During the study of local cytokine status in the wound fluid of the second group patients (PP+TachoComb<sup>®</sup>) we also found relatively high initial concentrations of pro and anti-inflammatory cytokines

which were significantly higher than the norm. On the 3rd day of the postoperative period there was a significant progressive decrease of TNF $\alpha$ , reaching minimum values by the 10th day of observation. On the 7th day a sharp decrease of IL 1 $\beta$  and IL 2 concentration took place, reaching minimum values on the 10th day of postoperative period. The concentration of pro-inflammatory cytokine IL 10, showing the relative stability from the first to the 7th day was significantly reduced (twice) by the end of the observation period in comparison with the original data (Table 2).

The comparative analysis of the cytokine profile in the wound fluid on the 1st day after the operation showed that both groups are characterized by relatively high concentrations of both pro and anti-inflammatory cytokines. At that TNF $\alpha$  and IL-10, belonging to the group of pro-inflammatory agents in the group PP+TachoComb<sup>®</sup> exhibit significantly lower rates than in the first group. In the future, the differences in the dynamics of study group cytokine profile became even more pronounced. It was characterized by a progressive significant reduction in the concentrations of proinflammatory cytokines TNF $\alpha$  and IL 1 $\beta$  among PP+TachoComb<sup>®</sup> patients at a relative stability of their levels in PP group during the entire period of observation. The concentration of proinflammatory cytokine IL 6, on the contrary, progressively increased in PP group and reached the maximum values on the 10th day while it remained virtually unchanged at all periods of observation in the group of PP+TachoComb<sup>®</sup> (Fig. 1).

Table 1: Cytokine concentration dynamics in the wound fluid during the plastic operation of anterior abdominal wall defects using the endoprosthesis “Esfil light” (PP)

	1st day	3rd day	7th day	10th day
Cytokines	1	2	3	4
TNF ( $\alpha$ )	18.06 $\pm$ 4.43	14.4 $\pm$ 3.02	12.14 $\pm$ 6.28	14.76 $\pm$ 8.24
IL 1 ( $\beta$ )	201.44 $\pm$ 37.45	138.96 $\pm$ 20.29	161.5 $\pm$ 29.86	160.54 $\pm$ 14.71
IL 2	88.78 $\pm$ 8.39	85.2 $\pm$ 6.81	69.33 $\pm$ 7.06 <sup>1</sup>	61.2 $\pm$ 14.9 <sup>1,2</sup>
IL 6	409.22 $\pm$ 21.07	587.63 $\pm$ 37.2 <sup>1</sup>	747.58 $\pm$ 60.8 <sup>1,2</sup>	996.4 $\pm$ 2.83 <sup>1,2,3</sup>
IL 8	277.8 $\pm$ 7.03	255 $\pm$ 22.8	256.7 $\pm$ 30.1	261.2 $\pm$ 18.9
IL 10	81.11 $\pm$ 13.46	68.11 $\pm$ 10.83	70.76 $\pm$ 10.9	71.3 $\pm$ 16.7
IL 1 RA	2170 $\pm$ 220.3	970.8 $\pm$ 101.3 <sup>1</sup>	715.3 $\pm$ 82.6 <sup>1,2</sup>	880.9 $\pm$ 92.6 <sup>1,2</sup>

\*The accuracy of the average differences (p<0.05), the next figure determines the column for which these differences are true

Table 2: The dynamics of cytokine concentration in the wound fluid during the plastic operation of anterior abdominal wall defect using the endoprosthesis “Esfil light” in combination with the drug TachoComb<sup>®</sup> (PP+TachoComb<sup>®</sup>)

	1st day	3rd day	7th day	10th day
Cytokines	1	2	3	4
TNF ( $\alpha$ )	12.64 $\pm$ 5.4	6.18 $\pm$ 0.45 <sup>1</sup>	6.27 $\pm$ 0.68 <sup>1</sup>	4.26 $\pm$ 0.21 <sup>1,2,3</sup>
IL 1 ( $\beta$ )	189.51 $\pm$ 44.06	168.3 $\pm$ 21.5	93.17 $\pm$ 13.8 <sup>1,2</sup>	24.2 $\pm$ 2.21 <sup>1,2,3</sup>
IL 2	88.5 $\pm$ 7.24	79.25 $\pm$ 5.44	60.1 $\pm$ 6.71 <sup>1,2</sup>	34.2 $\pm$ 4.1 <sup>1,2,3</sup>
IL 6	356 $\pm$ 20.2	362 $\pm$ 30.2	282.5 $\pm$ 56.3	362.1 $\pm$ 23.1
IL 8	266.25 $\pm$ 16.25	273.33 $\pm$ 13.3	271.8 $\pm$ 18.2	266.25 $\pm$ 6.25
IL 10	47.5 $\pm$ 9.3	46.67 $\pm$ 16.7	63.08 $\pm$ 22.8	23.3 $\pm$ 5.48 <sup>1,2,3</sup>
IL 1 RA	2080 $\pm$ 560.64	2733.33 $\pm$ 266.67	2266.67 $\pm$ 538.4	2645 $\pm$ 727.57

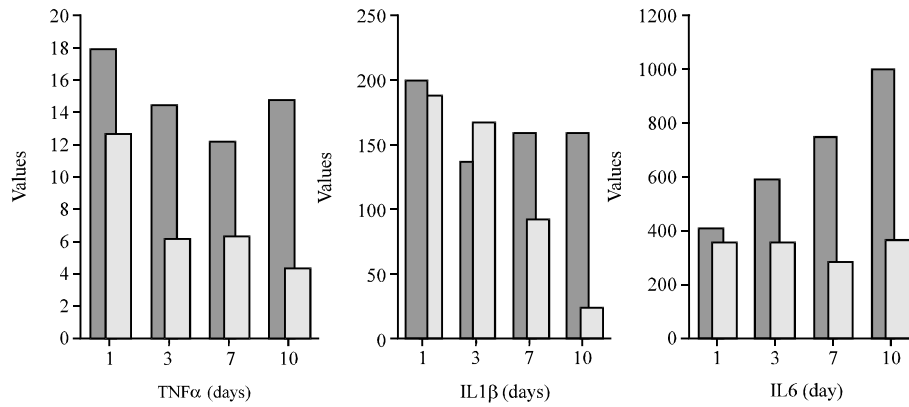


Fig. 1: The comparative analysis of pro-inflammatory cytokine TNF $\alpha$ , IL 1 $\beta$  of IL 6 dynamics in the wound fluid among the patients of studied groups (dark color indicate the parameters of PP patients, light color indicates the parameters of the patients PP+TachoComb<sup>®</sup>)

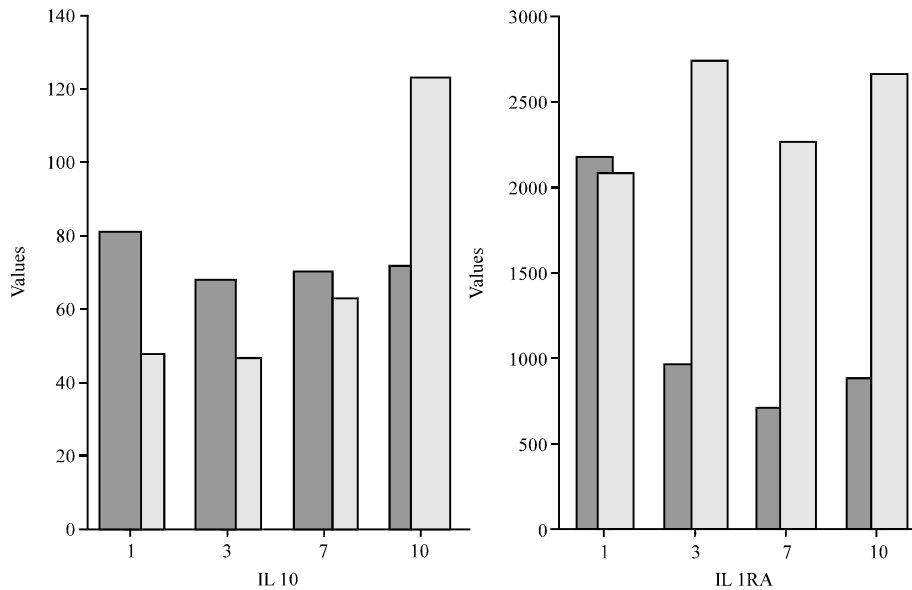


Fig. 2: The comparative analysis of pro-inflammatory cytokine IL 10 and IL 1 RA dynamics in the wound fluid among the patients of studied groups (dark color indicate the parameters of PP patients, light color indicates the parameters of the patients PP+TachoComb<sup>®</sup>)

During the analysis of anti-inflammatory cytokines IL-10 and IL 1 RA dynamics the following patterns are revealed in the groups under study. At the relative stability of IL-10 concentration in the wound fluid of PP patients at all stages of the research, the group PP+TachoComb<sup>®</sup> had its evident increase with a maximum value on the 10th day after the operation (Fig. 2).

The concentrations of IL 1 RA in the wound fluid of studied group patients were not significantly different from each other on the 1st day, however on the 3rd day of observation the PP group experienced its sharp evident decrease as compared with the values of PP+TachoComb<sup>®</sup> patients. In the future, during all

subsequent periods of the study, the difference in IL 1 RA values among the patients of both groups was evident and did not change.

## DISCUSSION

At the comparative assessment of pro and anti-inflammatory cytokine dynamics in the wound fluid of studied group patients we revealed serious differences. At that they were expressed not only quantitatively but also qualitatively. The obtained results allowed to conclude that the use of the drug TachoComb<sup>®</sup> at the implantation of mesh prosthesis “Esfil light” among the

patients with ventral hernias reduced significantly the severity of such inflammatory response in the area of operation. The mechanism of this TachoComb® effect is not sufficiently clear and is not described in the literature (Rickenbacher *et al.*, 2009; Toro *et al.*, 2011; Yamaguchi *et al.*, 2013). In our opinion, this can be caused not only by the ability of a fibrin-collagen plate to create a water and air-tight layer during the contact with body fluids for 3-5 min, at that limiting the contact area of the prosthesis with the surrounding tissues, thereby significantly reducing the production of proinflammatory and anti-inflammatory cytokines but its direct and/or indirect effect on the chemistry of an inflammatory response. These statements and conclusions dictate the need for further comprehensive research concerning the influence of TachoComb® drug on the local inflammation process as in a clinic so as in an experiment.

### CONCLUSION

The study analyzed the results of surgical treatment among 185 patients with postoperative ventral hernias. In order to prevent post-operative complications 57 patients with the plastic operation of anterior abdominal wall defect with mesh endoprosthesis “Esfil light” used TachoComb® (RF patent number 2391051 “Ventral hernia treatment method”). It was found that use of the drug TachoComb® allowed to reduce the severity of the inflammatory response in the area of operation which was characterized by significantly lower level of pro-inflammatory cytokines TNF $\alpha$ , IL 1 $\beta$ , IL 6 and a higher level of anti-inflammatory cytokines IL-10 and IL 1RA in the wound fluid at all stages of the study.

### REFERENCES

- Baillie, D.R., S.P. Stawicki, N. Eustance, D. Warsaw and D. Desai, 2007. Use of human and porcine dermal-derived bioprostheses in complex abdominal wall reconstructions: A literature review and case report. *Ostomy. Wound. Manage.*, 53: 30-37.
- Cavallaro, A., E.L. Menzo, M. Di Vita, A. Zanghi and V. Cavallaro *et al.*, 2010. Use of biological meshes for abdominal wall reconstruction in highly contaminated fields. *World J. Gastroenterol.*, 16: 1928-1933.
- Chavarriga, L.F., E. Lin, A. Losken, M.W. Cook and L.O. Jeansonne *et al.*, 2010. Management of complex abdominal wall defects using acellular porcine dermal collagen. *Am. Surg.*, 76: 96-100.
- Jacob, B.P., N.J. Hogle, E. Durak, T. Kim and D.L. Fowler, 2007. Tissue ingrowth and bowel adhesion formation in an animal comparative study: Polypropylene versus proceed versus parietex composite. *Surg. Endosc.*, 21: 629-633.
- Petter-Puchner, A.H., R.H. Fortelny, K.S. Glase and H. Redl, 2010. Collagen implants in inguinal and ventral hernia repair. *J. Invest. Surg.*, 23: 280-284.
- Rickenbacher, A., S. Breitenstein, M. Lesurtel and A. Frilling, 2009. Efficacy of TachoSil a fibrin-based haemostat in different fields of surgery: A systematic review. *Expert Opin. Biol. Ther.*, 9: 897-907.
- Sergent, F., N. Desilles, Y. Lacoume, J.J. Tuech, J.P. Marie and C. Marie, 2010. Biomechanical analysis of polypropylene prosthetic implants for hernia repair: An experimental study. *Am. J. Surg.*, 200: 406-412.
- Tanaka, K., D. Mutter, H. Inoue, V. Lindner and G. Bouras *et al.*, 2007. In vivo evaluation of a new composite mesh (10% polypropylene/90% poly-L-lactic acid) for hernia repair. *J. Mater. Sci. Mater. Med.*, 18: 991-999.
- Toro, A., M. Mannino, G. Reale and I. Di Carlo, 2011. TachoSil use in abdominal surgery: A review. *J. Blood Med.*, 2: 31-36.
- Yamaguchi, H., T. Nakao, N. Tokunaga, H. Nakamura and M. Takagaki, 2013. Off-pump suture repair of left ventricular rupture utilizing TachoComb® sheet: A case report and literature review. *World J. Emerg. Surg.*, Vol. 8.