

Ischemic Patient Treatment Experience Due to Atherosclerosis of Brachiocephalic Arteries

¹Igor B. Kovalenko, ¹Hanna Yu. Chefranova, ¹Vyacheslav D. Polyansky, ²Irina Yu. Kisil', ¹Nadezhda S. Zueva, ¹Maxim V. Filatov, ²Maxim I. Boyarincev, ²Maxim V. Pletyanov and ²Sergey S. Grishin
¹Belgorod State University, Pobedy Str., 85, 308015 Belgorod, Russia
²Belgorod Region Clinical Hospital St., Ioasaf, Nekrasova Str., 8/9, 308009 Belgorod, Russia

Abstract: The study performed a retrospective analysis of endovascular and conservative treatment of patients with ischemic stroke, caused by atherosclerotic lesions of brachiocephalic arteries. The studied group consisted of 80 patients who underwent the stenting of carotid arteries. The control group consisted of 90 patients who underwent a conservative therapy. The analysis of groups is performed according to risk factors of ischemic stroke development. The group under study included 66 men and 14 women. The median age of this group made 58.6 years. The control group included 69 men and 21 women. The average age of the patients made 62.6 years. The stenting was performed using distal embolic protection. The conservative therapy was carried out in accordance with the Federal standard. The result of treatment was assessed according to NIHSS scale. The article described the tactics worked out in the hospital during the treatment of patients with ischemic stroke, caused by atherosclerotic lesions of brachiocephalic arteries.

Key words: Ischemic stroke, ICA, carotid, stenting, analysis

INTRODUCTION

According to WHO data ischemic stroke occupies the 2nd place in the structure of population mortality, yielding only to ischemic heart disease. In Russia, the incidence of stroke is one of the highest in the world and makes 3.4 per 1,000 people a year. In absolute terms this amounts to this makes >450,000 of new strokes per year (Yahno and Vilensky, 2005; Bogousslavsky, 2005). At that the direct cause of daily activity limitations are not only motor and speech disorders but also cognitive impairments. According to epidemiological data, dementia develops within 6 months among 4-6% of patients who underwent a mild stroke. After 5 years, this rate is increased to 20-25%. Non dementia mild or average cognitive impairments occur more often (Madureira *et al.*, 2001; Pasquier *et al.*, 1999; Pasquier and Leys, 1997; Tham *et al.*, 2002).

ACAS (Asymptomatic Carotid Atherosclerosis Study) data indicate that the risk of an ipsilateral stroke for a patient with an asymptomatic stenosis of the Internal Carotid Artery (ICA) makes 20.6% for 47.9 months without surgical treatment on the background of a single medicament therapy while a surgical treatment reduces the risk of stroke down to 8%. Normal blood flow for brain makes 55 mL 100⁻¹ g of tissue and the consumption

of oxygen makes 3.7 mL 100⁻¹ g of tissue per minute. The perfusion of brain in constant limits is supported by autoregulation. The narrowing of artery lumen causing ischemia and lead to disruption of metabolic processes in a brain. The reduction of blood flow leads to notable first functional disorders (e.g., brain cell function) and with a further decrease in perfusion, it leads to the structural damage of cells and irreversible neurological damages.

The issue of ischemic stroke surgical treatment is not solved fully. In the world surgical practice the benefits of endovascular treatment concerning an ischemic stroke, caused by atherosclerotic lesions of brachiocephalic arteries are not revealed completely in comparison with conservative therapy (Abbott, 2009; Mathew *et al.*, 2005; Taylor *et al.*, 2003).

The purpose of the study is the analysis of the immediate treatment results among the patients with ischemic stroke, caused by the atherosclerotic lesions of brachiocephalic arteries and the development of treatment algorithm.

MATERIALS AND METHODS

We performed a retrospective analysis of 170 patients with an ischemic stroke. The studied group consisted of 80 patients who underwent ICA stenting.

Table 1: Installed stents

Stent name	No. of patients
Cristallo ideale	42
XACT	22
Protege	15
Coronary stent	2

The control group consisted of 90 patients. The patients of the control group underwent a conservative therapy. The study inclusion criteria were the presence of a transient ischemic attack or an ischemic stroke during the most severe or an acute period, the presence of stenosis is >70% in a symptom-related artery and/or an unstable plaque in a symptom-related artery. Both groups were comparable in age, sex and comorbidity.

The study group included 66 men and 14 women. The median age made 58.6 years. The control group included 69 men and 21 women. The average age of the patients made 62.6 years.

Stents were used with an open, closed and a combined cell. A coronary stent was set in 2 cases of intracranial stenosis. The distribution of stents is shown in Table 1.

All stenting was performed with the protection of brain from the distal embolism. In 9 cases a proximal protection was used in 71 cases the distal protection was used. On clinic admission the patients were given a loading dose of clopidogrel. When a distal cerebral protection from distal embolization was used during an operation, the washing of a guide catheter with saline solution was performed. In 2015 all surgeries started were performed without heparin. Prior to 2015, heparin was administered intraoperatively at the rate of 50 Units of Activity (UA) per kilogram.

The second group patients had a conservative treatment in accordance with the federal standard of care for the patients with cerebral infarction.

All patients on admission to an emergency department after the examination performed by a neurologist had a Spiral Computed Tomography (SCT) and the brain Duplex Sonography (DS) of brachiocephalic arteries and a Transcranial Color Duplex Ultrasonography (TCDU) of cerebral arteries.

RESULTS AND DISCUSSION

The result of treatment was assessed according to NIHSS scale. In the studied group the hypertensive disease was experienced by 75 patients (94%), 17 (21%) had the Coronary Heart Disease (CHD) with a high functional class of angina, hypercholesterolemia was

Table 2: Distribution of patients by risk factors

Risk factor	Group under study	Control group	p-values
Hypertensive disease	75 (94%)	84 (93%)	0.05
IHD	17 (21%)	61 (68%)	0.05
Ischemic stroke in history	13 (16%)	78 (87%)	0.05
Hypercholesterolemia	30 (37%)	50 (56%)	0.05
Atrial fibrillation	11 (14%)	14 (16%)	0.05
Diabetes mellitus	14 (17%)	8 (9%)	0.05
The >1 risk factor	80 (100%)	90 (100%)	0.05

observed among 30 patients (37%), ischemic stroke or Transient Ischemic Attack (TIA) had a history was observed among 13 patients (16%), 11 patients (14%) had atrial fibrillation, diabetes affects 14 patients (17%).

In the control group of hypertensive disease suffered 84 patients (93%), ischemic heart disease with high functional class of angina, 61 people (68%), hypercholesterolemia was in 50 patients (56%), ischemic stroke or TIA were 78 patients (87%), atrial fibrillation in 14 patients (16%) and 8 patients (9%) had diabetes mellitus.

All patients had more than one risk factor. Table 2 shows the distribution of patients according to risk factors.

Stenting was successful in 100% of cases. Stenting was performed in 27 cases (33.75%) during the first 6 h of disease onset. In 7 (8.75%) cases ICA stenting was combined with ICA thrombectomy and cerebral arteries. At 2 cases of ICA occlusion thrombectomy was performed using Penumbra System device in 1st case by the system ThromCat, 1 patient had an aspiration thrombectomy through a guide catheter, 1 patient was had embolus in the middle third of ICA which was removed by Spyder. In 2 cases there was the embolism in M1 segment of the middle cerebral artery-thrombectomy was performed by the stent retriever Solitaire AB. The stenting combined with thrombectomy was performed in all cases during the first 6 h after the disease onset. In 53 (66.25%) cases, stenting was performed later than 6 h after the disease onset. The indication for surgery after >6 h of the onset of disease were presented by twinkling symptoms an ischemic lesion <3 cm² and the presence of penumbra zone.

Postdilation was performed among 66 patients (83%). The 4 patients had embolism in distal branches after stenting. The intervention was complemented by the selective thrombolytic therapy.

Conservative therapy was administered to the patients at the absence of technical capability to perform an endovascular treatment. Therapy included neuroprotectors and anti-platelet drugs.

Hemorrhagic transformation was observed in 8 (10%) cases among the patients of the study group. At that in 4 cases, stenting was performed >6 h after the disease onset and ICA occlusion was observed in 3 cases. In 2015, there were no cases of hemorrhagic transformation.

The control group the hemorrhagic transformation was not observed. At discharge, the mean value according to NIHSS scale made 6.1 in the control group and 3.5 in the study group.

Patients (12.2%) died in the control group and 6 patients (7.5%) died in the study group. In all cases, edema and cerebral dislocation were an immediate cause of death.

In our clinic we developed the patient treatment tactics with an ischemic stroke, caused by atherosclerotic lesions of brachiocephalic arteries. After the examination by a duty neurologist, the patient is sent for brain SCT and DS with TCCS. If you find >70% of stenosis or an unstable plaque in a symptom-related artery, a patient is sent for a surgery with an X-ray. After the performance of angiography a treatment strategy is determined. Heparin is not administered during a preoperative and an intraoperative stage. Stenting is performed using the protection system against distal embolism. When a filter is used as a protection means filter the use of a physiological saline for a guide-catheter washing is necessary. If the residual stenosis makes >40% postdilatation is performed.

Clinical example: A patient A. at the age of 59 was hospitalized in the cardiology department of the Belgorod Regional Clinical Hospital (BRCH) named after St. Ioasaph since 01/21/2015 till 01/31/2015 with the

diagnosis of coronary artery disease. Exertional angina, the second Functional Class (FC) (Class 1). Postinfarction cardiosclerosis (acute myocardial infarction) in September 2014. Stenosing hemodynamically significant coronary sclerosis according to coronary angiography data, the hypertension of the 3rd and 2nd stage with the damage of heart and brain blood vessels with the achievement of arterial pressure target level. Second type of diabetes mellitus, additionally insulin demanding, subcompensation stage. Risk 4, Chronic heart failure II A, Cholelithiasis. Calculous cholecystitis without exacerbation.

The patient was hospitalized in the cardiac surgery department for surgical treatment on 02/02/2015. In 8:20 am. of 02.05.2015 the patient's state deteriorated he became unavailable for a contact and has weakness of the right extremities. An acute ischemic stroke was suspected. A neurologist was invited and the following examination was scheduled: spiral computed tomography of the brain, SCT angiography of cerebral arteries. During SCT angiography (8 h 46 min) the contrasting defect of the left Common Carotid Artery (CCA) is revealed, ICA. The patient was sent for an X-ray. During the performance of cerebral artery angiography the occlusion of the left CCA was revealed in the proximal third, the filling of intracranial departments was performed through the anterior communicating artery (Fig. 1-3).

It was decided to perform the recanalization of occluded CCA. The guide catheter Cello was used as the protection system against distal embolization. After the performance of aspiration thrombectomy, the stenosis at the mouth of the left ICA was revealed. The stenting of the right ICA was performed. During the

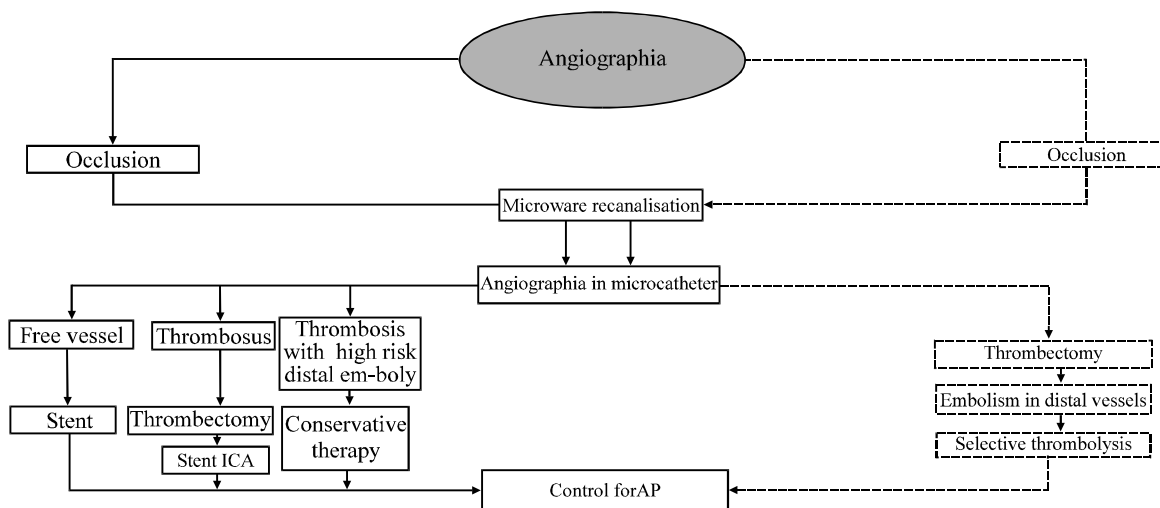


Fig. 1: Patient treatment scheme with ischemic stroke

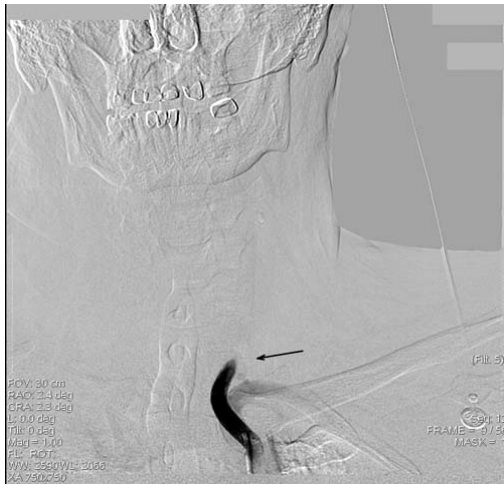

Fig. 2: Left ICA occlusion

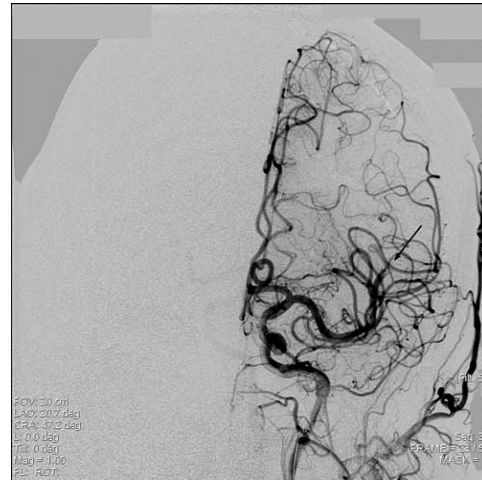


Fig. 4: MCA embolism

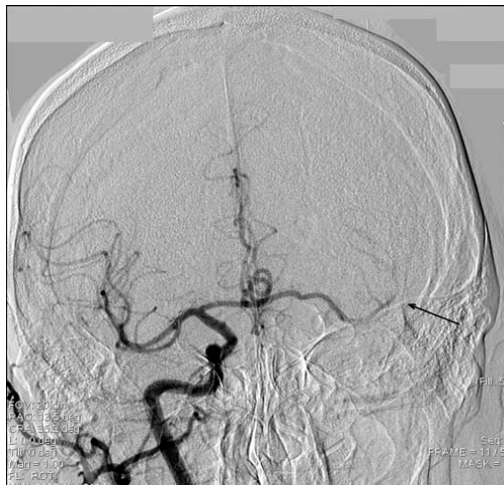

Fig. 3: Filling of intracranial departments through ACA

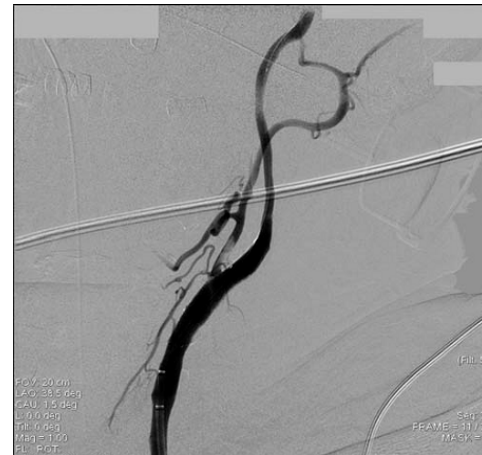

Fig. 5: Restored blood flow in ICA

control angiography an embolic occlusion in M3 segment of the left middle cerebral artery (Fig. 4) was determined. The intervention was supplemented by selective thrombolytic therapy with Actilyse® drug.

During the control angiography the blood flow of ICA is completely restored, embolism in the segment M5 of left middle cerebral artery is revealed (Fig. 5 and 6).

The result is regarded as a satisfactory one. At the control SCT an infarct hematoma of the 1st type was determined, caused by the damage of the middle cerebral artery branch from a micro conductor. An additional intervention was not required.

The patient was discharged on the 15th day with the neurological deficit of 6 points according to NIHSS scale.

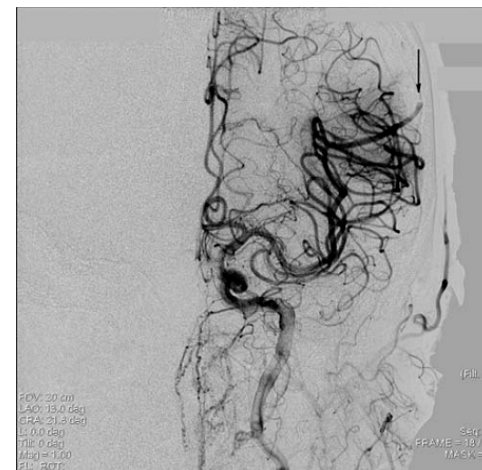


Fig. 6: M5 MCA embolism

CONCLUSION

Carotid artery stenting is an effective and a safe treatment method for the patients with an ischemic stroke, caused by atherosclerotic lesions of brachiocephalic arteries. The patients who underwent ICA stenting had a lower mortality (12.2% in the control group, 7.5% in the study group) and a more complete recovery at discharge (6.1 in the control group and 3.5 in the study group). ICA occlusion is not a limitation to an endovascular treatment. If there are shimmering symptoms, a small ischemic outbreak and the presence of penumbra zone the performance of endovascular intervention later than 6 h after the disease onset is possible. Endovascular interventions are carried out without perioperative heparin introduction and at the use of a filter protecting against distal embolism the use of washing with a saline solution is necessary.

REFERENCES

- Abbott, A.L., 2009. Medical (Nonsurgical) intervention alone is now best for prevention of stroke associated with asymptomatic severe carotid stenosis, results of a systematic review and analysis. *Stroke*, 40: 573-583.
- Bogousslavsky, J., 2005. The global stroke initiative, setting the context-with the international stroke society. *J. Neurol. Sci.*, 238: S28-S28.
- Madureira, S., M. Guerreim and J.M. Ferro, 2001. Dementia and cognitive impairment 3 months after stroke. *Eur. J. Neurol.*, 8: 621-627.
- Mathew, B., V. Bhatia and L. Francis, 2005. Nonsurgical carotid revascularization. *Cardiology Rev.*, 13: 197-199.
- Pasquier, F. and D. Leys, 1997. Why are stroke patients prone to develop dementia?. *J. Neurol.*, 244: 135-142.
- Pasquier, F., H. Henon and D. Leys, 1999. Risk factors and mechanisms of post-stroke dementia. *Rev. Neurol.*, 155: 749-753.
- Taylor, S., F. Alcocer and W.D. Jordan, 2003. Controversies in carotid stenting. *Vasc. Endovascular. Surg.*, 37: 79-87.
- Tham, W., A.P. Auchus, M. Thong, M.L. Goh and H.M. Chang, 2002. Progression of cognitive impairment after stroke: 1 year results from a longitudinal study of Singaporean stroke patients. *J. Neurol. Sci.*, 203: 49-52.
- Yahno, N.N. and B.S. Vilensky, 2005. Stroke as a medical and a social problem. *Russ. Med. J.*, 13: 807-815.