

Wound Healing Potential of Total Sulfated Glycosaminoglycan (GAG) from Malaysian Sea Cucumber, *Stichopus vastus* Coelomic Fluid

¹Siti Fathiah Masre, ²George W. Yip, ³K.N.S. Sirajudeen and ⁴Farid Che Ghazali
¹Biomedical Science Programme, School of Diagnostic and Applied Health Sciences,
Faculty of Allied Health Sciences, Universiti Kebangsaan Malaysia,
50300 Kuala Lumpur, Malaysia
²Department of Anatomy, Yong Loo Lin School of Medicine,
National University of Singapore, 117597 Singapore, Singapore
³Department of Chemical Pathology, School of Medical Sciences,
⁴Biomedical Sciences Programme, School of Health Sciences,
Universiti Sains Malaysia, 16150 Kubang Kerian, Malaysia

Abstract: Massive nutritional and medicinal values of sea cucumbers have long been reported in the past that may be due to sulfated Glycosaminoglycan (GAG). Thus, the effects of total sulfated GAG from local *Stichopus vastus* coelomic fluid were analyzed for its potential in full-thickness excisional wound healing. The 20 μL of 1 $\mu\text{g mL}^{-1}$ total sulfated GAG was applied topically to 6 mm diameter of full thickness wound from day 0-12 on the dorsal part of female sprague-dawley rats ($n = 10$). Whilst control group was treated with 20 μL of normal saline. Wound healing activities were assessed through wound contraction rate (%) and semi-quantitative measurement on the histology analysis of epithelial migration, inflammatory responses, fibroblasts proliferation, new vessels formation and collagen organization. Results showed significantly improve wound contraction rate on each observation day in the treatment group compared to the control group. Total sulfated GAG from *S. vastus* coelomic fluid showed significantly acceleration on wound healing process in epithelial migration, fibroblasts proliferation, new vessels formation and collagen organization. Data strongly documented the wound healing effects of sulfated GAG from the local sea cucumber *S. vastus* coelomic fluid.

Key words: Sea cucumber, wound healing, glycosaminoglycan, sulfated GAG, *S. vastus*

INTRODUCTION

Wound healing is a complex event that involved the interactions of cell and extracellular matrix which can affect various hard, soft tissues and organ systems (Cohen and Mast, 1990). Generally, wounds progress through a four well-defined phases: hemostasis (or coagulation), inflammation, repair (cell migration, proliferation, matrix repair and epithelialization) and remodeling (or maturation) of the scar tissue (Lawrence, 1998). Both acute and chronic cutaneous wounds occurred globally. Chronic wounds have become major healthcare problems in the United States of America by costing billions of dollars a year (Fonder *et al.*, 2008) and even the world facing wound care expenditures amount about 13-15 billion annually (Walmsley, 2002). Thus, massive numbers of new treatment for both acute and

chronic wounds have become actively growing over the past decade (Bello and Phillips, 2000). Several natural products from marine invertebrates (Pujol *et al.*, 2007) have been reported to promote the process of wound healing.

Sea cucumbers are marine invertebrates with a tube-shaped structure. Sea cucumbers have long been purported as a source of traditional medicines due to their various essential nutrition and medicinal values (Shimada, 1969; Sit, 1998; Masre *et al.*, 2010). The presence of Glycosaminoglycans (GAGs) in sea cucumbers (Masre *et al.*, 2012) that has many physiologically active functions made them as one of poly-anion-rich food (Li *et al.*, 1985). GAGs are long, unbranched polysaccharides composed of repeating disaccharide units that can be divided into sulfated GAGs and non-sulfated GAGs (Yip *et al.*, 2006). Literature has

reported that sulfated GAGs improved skin appearance, healed wounds and also essential for the healthy functioning of joints. Studies have shown that chondroitin sulfate and heparan sulfate (Zou *et al.*, 2004; Stringer and Gallagher, 1997) were actively involved in the wound healing processes (Zou *et al.*, 2004; Annika *et al.*, 2007) together with the formation of connective tissue components (Bentley, 1967).

As part of efforts to elucidate the pharmaceutical activities and medicinal potential, hence, evaluation on wound healing properties of sulfated GAGs extracted from the coelomic fluid of Malaysian sea cucumber *Stichopus vastus* was performed in this study through analysis of wound contraction rate and wound histology.

MATERIALS AND METHODS

Sample preparation: Sea cucumbers *Stichopus vastus* (Sluiter, 1887) (n = 5) were freshly harvested from the Perhentian Island coast of Malaysia. Extraction of GAG from sea cucumbers was carried out by the method by Ledin *et al.* (2004) adapted from Staatz *et al.* (2001). The 2.0 mL of coelomic fluid was collected using a hypodermic needle from the *S. vastus* to extract the Glycoaminoglycans (GAGs). Then, 0.5 mL protease buffer containing 0.8 mg mL⁻¹ unspecific protease (Protease Type XIV, Sigma) was added to the coelomic fluid. This step was followed by incubating the sample at 55°C for 16 h using a water bath with constant rotation to make sure the whole samples were suspended. Next, the protease was inactivated by heating at 96°C for 5 min and then added 0.5 mL of 1 M MgCl₂ to achieve a final concentration of 2 mM. After that 0.5 µL of benzonase (= 25 U µL⁻¹) was added to the samples and incubated in a water bath at 37°C for 2 h. Samples were mixed regularly and followed by heat inactivation of the benzonase for 2 min at 96°C. The samples then were mixed with 0.5 mL of 4 M NaCl (final concentration of 0.1 M NaCl) before spinning in an Eppendorf centrifuge for 10 min at 15,000 rpm. The extracted GAGs in the supernatant was collected in a 2.0 mL microcentrifuge tube (Axygen, Union City, California) and stored at -20°C until used. Total sulfated GAG from sea cucumber *S. vastus* coelomic fluid was measured from the total extracted GAGs using Blyscan™ sulfated GAG assay according to the manufacturer's instructions. The concentration of total sulfated GAG from the *S. vastus* coelomic fluid (16.37±1.86 µg mL⁻¹) was diluted to 1 µg mL⁻¹ and applied topically on wound healing study. Dilutions were made fresh on the day of an assay or stored at -20°C.

Wound healing study: Sprague-Dawley rats weighing 160-180 g, aged nine to eleven weeks old were utilized in this study (n = 10 per group). All rats were healthy, fertile and did not display any evidence of infection or disease. Each rat was acclimatized for at least 5 days to reduce stress and make them familiarized with human contacts. Rats were housed in individual clean cages in the animal house facility under 12 h light-dark cycle together with free access to standard rat chow and water throughout the study. The animal house facilities were maintained accordance with Laboratory Animal Research Unit, Universiti Sains Malaysia Health Campus (LARU USM) guidelines and this study has received approval from the Animal Ethics Committee Universiti Sains Malaysia.

Rats were grouped randomly with 10 rats per group that consist of treatment group for the topical application of *S. vastus* coelomic fluid and control group (20 µL of normal buffered saline). Under anesthetic condition, the dorsal area of each rat was shaved and wiped with 70% alcohol swab followed by a povidone-iodine solution. Then, 6 mm in diameter of a full-thickness excisional wound was excised by using a standardized sterile biopsy punch (Stiefel, USA) on the dorsal area. Topical treatment of 20 µL of 1 µg mL⁻¹ concentration of total sulfated GAG from the *S. vastus* coelomic fluid was applied to each rat daily from day 0-12.

Wound contraction rate: For macroscopic evaluation, the progression of wound healing was recorded on days 1, 6 and 12 for both treated and control groups (McLennan *et al.*, 2008) by measuring the wound diameter (mm) using a standard caliper measurement. Then, wound contraction percentage on each specified day was calculated as mentioned previously (Sardari *et al.*, 2006; Masre *et al.*, 2010).

Percentage of wound contraction (%) =

$$[(A_{\text{Day 0}} - A_{\text{Day x}}) / A_{\text{Day 0}}] \times 100$$

(Day x = Day 1; Day 6; Day 12)

Histological analysis of wound healing: Full-thickness of skin biopsy was obtained on day 12 from the treatment and control groups for histological study. The tissues were fixed in 10% buffered formalin, dehydrated in alcohol, cleared in xylene and paraffin-embedded. The 5 µm tissue sections were cut and stained with Hematoxylin and Eosin (H&E) and Masson's Trichrome. Histological analysis of the tissue was done by using light microscopy to visualize and semi-quantitate the

Table 1: Details of used scale in the semi-quantitative evaluation of histological morphology changes

Scale	Epithelization	Inflammatory response	Fibroblasts	New vessels	Collagen
0	Absent	Absent	Absent	Absent	Absent
1	Migration of cells (<50%)	Mild ST	Mild-ST	Mild-SCT	Minimal-GT
2	Migration of cells (≥ 50%)	Mild GT	Mild-GT	Mild-GT	Mild-GT
3	Bridging the excision	Moderate GT	Moderate-GT	Moderate-GT	Moderate-GT
4	Keratinization	Marked GT	Marked-GT	Marked-GT	Marked-GT

ST: Surrounding Tissue, i.e., tissue out of GT; GT: Granulation Tissue; SCT: Subcutaneous Tissue) (Gal *et al.*, 2008)

histomorphological changes parameters of wound healing (epithelization, inflammatory cells, fibroblasts proliferation, new vessels formation and collagen organization) (Table 1). This semi-quantitative method was adapted from previous research by Gal *et al.* (2008). Three slides (e.g., a, b, c) were randomly selected from each animal per group and the score scale of histomorphological changes was evaluated in ten different spots for each slide under same scale magnification power (x40 objective) using light microscope. The results expressed as mean±SEM.

Statistical analysis: Statistical analysis was performed using a standard software package (Statistical Package for Social Sciences (SPSS) Version 12.0.1). The statistical difference between the treated group and control group of wound healing was calculated by using independent t-test with $p < 0.05$ was considered as significantly different.

RESULTS AND DISCUSSION

Effects of total sulfated GAG from *S. vastus* coelomic fluid on wound contraction: The 6 mm circular full-thickness excisional wound was created on the dorsum of rats for each treatment and control group. The wound diameter was recorded on 1, 6 and day 12 for the measurement of wound contraction rate (%) on the specified day as the percentage of wound area that healed (Table 2). Data showed that the total sulfated GAGs from *S. vastus* coelomic fluid accelerated the wound contraction to heal significantly in each interval day as compared to control group.

Effects of total sulfated GAG from *S. vastus* coelomic fluid on wound histology: Table 3 showed the score of wound healing parameters in both treated and control groups through histological analysis based on the method as mentioned above. Wounds treated with total sulfated GAG of *S. vastus* coelomic fluid showed rapid and significant signs of healing as compared to control group in each histomorphological parameters of wound

Table 2: Wound contraction rate (%) in mean±SEM on day 1, 6 and 12 between the treated and control groups

Groups	No. of animals	Wound contraction rate (%)		
		Day 1	Day 6	Day 12
Sulfated GAGs of <i>S. vastus</i> coelomic fluid	10	10.42±2.08*	34.72±3.35*	73.61±1.39*
Control by PBS	10	0.00±0.00	10.42±2.08	55.56±4.12

* $p < 0.05$ significantly different as compared to control group (by PBS)

Table 3: Histomorphological parameters of wound healing between treated and control groups

Histomorphological parameters	Sulfated GAGs of <i>S. vastus</i> coelomic fluid (mean±SEM)	Control by PBS (mean±SEM)
Epithelization	3.83±0.17*	2.30±0.60
Inflammatory responses	1.49±0.15	0.77±0.19
Fibroblasts	3.29±0.20*	2.39±0.23
New vessels	2.47±0.18*	2.01±0.70
Collagen fibers	3.55±0.19*	2.30±0.33

* $p < 0.05$ significantly different as compared to control group

healing (Table 3). The significance formation of epithelization, together with the significance increased in fibroblasts, blood vessels and higher density of collagen fibers in the treated group as compared to the control group indicated the positive effect of total sulfated GAG from *S. vastus* coelomic fluid on wound healing.

Marine invertebrates have been and continue to be examined as a source of biologically active compounds with various biomedical applications (Kelly, 2005). It is reported that marine invertebrates which comprises over 150,000 species are the major producers of biologically active compounds (Venugopal, 2008). Furthermore, there are still many questions whether the active compound, sulfated GAGs particularly from the local sea cucumber *S. vastus* coelomic fluid has any healing potential since many studies in the past have reported on the roles of sulfated GAGs in human (Toshihiko *et al.*, 2003).

In this study, data indicate that the sulfated GAGs from *S. vastus* coelomic fluid showed significant effects in wound healing progression via rapid wound contraction rate (%) and histomorphological parameters. Since, wound contraction is one of key contributor events in wound healing (Gupta and Lawrence, 2008), thus, data in this study showed that sulfated GAGs from the *S. vastus* coelomic fluid can play as a promoter by rapid closure of the wound as shown on the three observation days

(day 1, 6 and 12) compared to the control group. This process might be due to the influence of sulfated GAGs into the Extracellular Matrix (ECM) of the wound which can have important consequences on cell proliferation including fibroblasts and subsequently enhanced the wound contraction rate (Nikitovic *et al.*, 2005).

For histological analysis, data showed that total sulfated GAGs from *S. vastus* coelomic fluid significantly improved the wound healing event assessed through the score of histomorphological parameters on day 12th. The wound healed successfully by the influence of sulfated GAGs as complete epithelial layers with keratin formation appeared in the treated group. Data also revealed significant fibroblasts proliferation into the wound matrix, increased in new vessels formation together with dense collagen fibers organization appeared in the treated group. The significance influence of sulfated GAGs to fibroblasts proliferation in this study appeared to support the findings from Clark *et al.* (2004) where they have shown through *in vitro* study that unglycanated CD44H

could transform into glycanated CD44H which is necessarily important for fibroblast invasion into fibrin gel with the occurrence of sulfated GAGs. This may suggests that sulfated GAGs from *S. vastus* coelomic fluid showed a big influence to stimulate fibroblast proliferation during wound healing.

Through, histological analysis, the sulfated GAGs from *S. vastus* coelomic fluid showed to significantly involved in the intense formation of new vessels. This finding is congruent with research by Tapon-Brethaudiere *et al.* (2002) where they revealed that intense angiogenic activity with marked formation of capillary-like network was formed after Human Umbilical Vein Endothelial Cells (HUVEC) treated with fucosylated chondroitin sulfate which is part of sulfated GAGs from sea cucumber *Ludwigothurea grisea*. The increased new vessels formation delivers more oxygen and nutrients to wound bed, leading to the deposition of newly vascularized connective tissue and subsequently may account for the improved wound (Tong *et al.*, 2008) (Fig. 1-4).

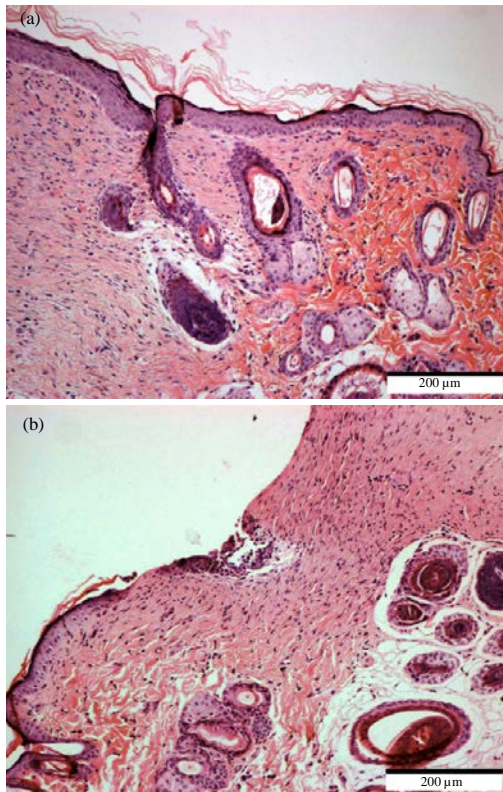


Fig. 1: Complete epithelization formation shown by light microscope with H&E staining in the treated group (sulfated GAG of *S. vastus* coelomic fluid): a) as compared to the control group and b) on the 12th day (x10)

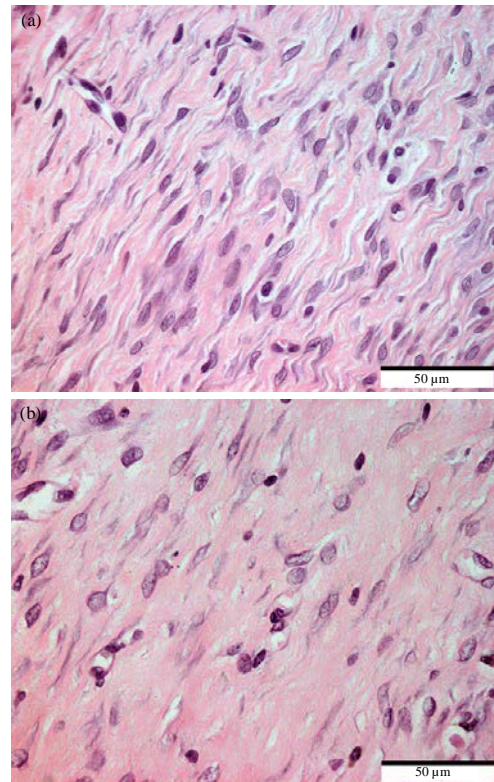


Fig. 2: Increased fibroblasts proliferation shown under light microscope with H&E staining in the treated group (sulfated GAG of *S. vastus* coelomic fluid): a) as compared to the control group and b) on the 12th day (x40)

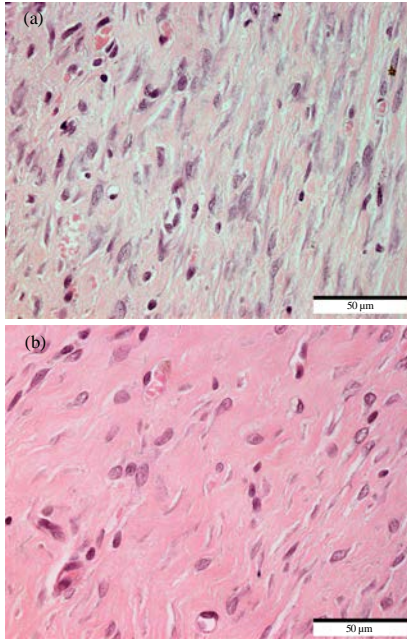


Fig. 3: Increased new vessels formation shown under light microscope with H&E staining in the treated group (sulfated GAG of *S. vastus* coelomic fluid): a) as compared to the control group and b) on the 12th day (x40)

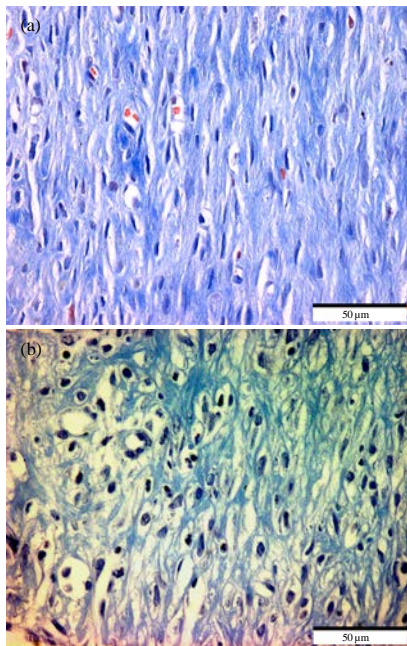


Fig. 4: Increased and organized collagen fibers shown by light microscope with Masson's Trichrome staining the treated group (sulfated GAG of *S. vastus* coelomic fluid): a) as compared to the control group and b) on the 12th day (x40)

CONCLUSION

In conclusion, this study showed that total sulfated GAG from *S. vastus* coelomic fluid can strongly augment the natural wound healing by accelerating the wound contraction rate, enhancing epithelization formation, fibroblasts proliferation, improving vascular capacity and collagen fibers organization. Further studies are warranted on the molecular mechanisms underlying the miraculous effects of total sulfated GAG from *S. vastus* coelomic fluid in wound healing activities.

ACKNOWLEDGEMENTS

Greater appreciation to Universiti Sains Malaysia for providing the short term research grant (304/PPSK/6139058) and Universiti Kebangsaan Malaysia for the scholarship to carry out this study.

REFERENCES

- Annika, N.A., A.B. Hinke-Multhaupt and R.C. John, 2007. Syndecans in wound healing, inflammation and vascular biology. *Int. J. Biochem. Cell Biol.*, 39: 505-528.
- Bello, Y.M. and T.J. Phillips, 2000. Recent advances in wound healing. *JAMA*, 283: 716-718.
- Bentley, J.P., 1967. Rate of chondroitin sulfate formation in wound healing. *Annal. Surg.*, 165: 186-191.
- Clark, R.A., F. Lin, D. Greiling, J. An and J.R. Couchman, 2004. Fibroblast invasive migration into fibronectin/fibrin gels requires a previously uncharacterized dermatan sulfate-CD44 proteoglycan. *J. Invest. Derm.*, 122: 266-277.
- Cohen, K.I. and B.A. Mast, 1990. Models of wound healing. *J. Trauma*, 1: S149-S154.
- Fonder, M.A., G.S. Lazarus, D.A. Cowan, B. Aronson-Cook and A.R. Kohli *et al.*, 2008. Treating the chronic wound: A practical approach to the care of nonhealing wounds and wound care dressings. *J. Am. Acad. Derm.*, 58: 185-206.
- Gal, P., R. Kilik, M. Mokry, B. Vidinsky and T. Vasilenko *et al.*, 2008. Simple method of open skin wound healing model in corticosteroid-treated and diabetic rats: Standardization of semi-quantitative and quantitative histological assessments. *Vet. Med.*, 53: 652-659.
- Gupta, S. and W.T. Lawrence, 2008. Wound Healing: Normal and Abnormal Mechanisms and Closure and Closure Techniques. In: *The Physiologic Basis of Surgery*, O'Leary, J.P. and A. Tabuenca (Eds.). 4th Edn., Lippincott Williams and Wilkins, USA.

- Kelly, M.S., 2005. Echinoderms: Their Culture and Bioactive Compounds. In: Echinodermata, Matranga, V. (Ed.). Springer, Berlin, Germany, ISBN-13: 9783540244028, pp: 139-165.
- Lawrence, W.T., 1998. Physiology of the acute wounds. Clin. Plast. Surg., 25: 321-340.
- Ledin, J., W. Staatz, J.P. Li, M. Gotte, S. Selleck, L. Kjellenand and D. Spillmann, 2004. Heparan sulfate structure in mice with genetically modified heparan sulfate production. J. Biol. Chem., 279: 42732-42741.
- Masre, S.F., G.W. Yip, K.N.S. Sirajudeen and F.C. Ghazali, 2010. Wound healing activity of total sulfated Glycosaminoglycan (GAG) from *Stichopus vastus* and *Stichopus hermanni* integumental tissue in rats. Int. J. Mol. Med. Adv. Sci., 6: 49-53.
- Masre, S.F., G.W. Yip, K.N.S. Sirajudeen and F.C. Ghazali, 2012. Quantitative analysis of sulphated glycosaminoglycans content of Malaysian sea cucumber *Stichopus hermanni* and *Stichopus vastus*. Nat. Prod. Res., 26: 684-689.
- McLennan, S.V., J. Bonner, S. Milne, L. Lo and A. Charlton *et al.*, 2008. The anti-inflammatory agent Propolis improves wound healing in a rodent model of experimental diabetes. Wound Rep. Reg., 16: 706-713.
- Nikitovic, D., A. Zafiroopoulos, G.N. Tzanakakis, N.K. Karamanos and A.M. Tsatsakis, 2005. Effects of glycosaminoglycans on cell proliferation of normal osteoblasts and human osteosarcoma cells depend on their type and fine chemical compositions. Anticancer Res., 25: 2851-2856.
- Pujol, C.A., M.J. Carlucci, M.C. Matulewicz and E.B. Damonte, 2007. Natural sulfated polysaccharides for the prevention and control of viral infections. Topics Heterocyclic Chem., 11: 259-281.
- Sardari, K., M.M. Dehgan, M. Mohri, M.R. Emami and A. Mirshahi *et al.*, 2006. Macroscopic aspects of wound healing (contraction and epithelialisation) after topical administration of allicin in dogs. Comp. Clin. Pathol., 15: 231-235.
- Shimada, S., 1969. Antifungal steroid glycoside from sea-cucumber. Sci., 163: 1462-1471.
- Staatz, W.D., H. Toyoda, A. Kinoshita-Toyoda, K. Chhorand and S.B. Selleck, 2001. Analysis of Proteoglycans and Glycosaminoglycans from *Drosophila*. In: Methods in Molecular Biology, Proteoglycan Protocols, Iozzo, R.V. (Ed.). Humana Press Inc., Totowa, NJ USA., pp: 41-52.
- Stringer, S.T. and J.T. Gallagher, 1997. Heparan sulphate. Int. J. Biochem. Cell Bio., 29: 709-714.
- Tapon-Breaudiere, J., D. Chabut, M. Zierer, S. Matou and D. Helley *et al.*, 2002. A fucosylated chondroitin sulfate from echinoderm modulates *in vitro* fibroblast growth factor 2-dependent angiogenesis. Mol. Cancer Res., 1: 96-102.
- Tong, M., M.M. Zbinden, I.J.M. Hekking, M. Vermeij and D. Barritault *et al.*, 2008. RGTA OTR 4120 a heparin sulfate proteoglycan mimetic, increases wound breaking strength and vasodilatory capability in healing rat full-thickness excisional wounds. Wound Rep. Reg., 16: 294-299.
- Toshihiko, T., C. Amornrut and R.J. Linhardt, 2003. Structure and bioactivity of sulfated polysaccharides. Trends Glycosci. Glyc., 15: 29-46.
- Yip, G.W., S. Martin and G. Martin, 2006. Therapeutic value of glycosaminoglycans in cancer. Am. Assoc. Cancer Res., 5: 2139-2148.
- Zou, X.H., W.C. Foong, T. Cao, B.H. Bay, H.W. Ouyang and G.W. Yip, 2004. Chondroitin sulfate in palatal wound healing. J. Den. Res., 83: 880-885.