

## The Non-Urological Findings of CT Urography

<sup>1</sup>Mwaffaq El-Heis, <sup>1</sup>Maha Gharaibeh, <sup>1</sup>Mammon Al-Omari, <sup>2</sup>Qusai Aljarrah and <sup>1</sup>Ruba Khasawneh

<sup>1</sup>Department of Radiology,

<sup>2</sup>Department of Vascular, Faculty of Medicine, Jordan University of Science and Technology,  
Irbid, Jordan

---

**Abstract:** CTU an imaging model is used to investigate hematuria and can provide good details of non-urological findings. To assess the frequency of non-urological pathologies on CT Urography (CTU) and to categorize the findings in order of importance and to determine the percentage of clinically significant findings that would require immediate management. A total of 340 consecutive CT urograms were respectively reviewed between from August 2011-2012. The CTU were performed using a 2 phase split doses (50+50 mL) protocol using a 16 or 64 slices CT (Philips, Netherlands). All reported non-urological findings were recorded and classified according to reporting standard for the extra colonic findings in CT colonography. E0 = Inadequate examination, E1 = Normal findings/variant, E2 = Abnormal finding requiring no change in the management, E3 = Abnormal findings with potential change in management and E4 = Significant abnormal findings that urgent action required. The mean age of participants was 66.65 years. About 71% of participants were males. A total of 136 (40%) of all cases of CT urograms were non-urological pathology, most of cases were in E2 (90) and E3 (82). CTU detected 40% of cases with non-urological pathologies. CTU offers added advantage-in detecting non-urological pathology, however, radiologists need a pragmatic approach when reporting these findings.

**Key words:** CTU, non-urological pathologies, E0, E1, E2, E3, E4

---

### INTRODUCTION

CTU is an examination of the urinary tract before and after administration of intravenous iodine contrast material using CT in which a scan in Excretory Phase (EP) is included (Van Der Molen *et al.*, 2008).

In their study, Silverman *et al.* (2009) reported that among adults, CT urography or MR urography is the preferred choice of examination in most historical indications for intravenous urography. CT urography gives more detailed anatomic depiction of urinary system which permits patients with haematuria to be fully assessed.

CT urography is used to examine a variety of urinary tract disorders including renal masses (Zagoria, 2000; Silverman *et al.*, 2008) urinary tract calculi (Fielding *et al.*, 1998; Sourtzis *et al.*, 1999) genitourinary trauma (Herschorn *et al.*, 1991) and renal infection (Kawashima *et al.*, 1997).

Devlin *et al.* (2015) conducted a study on a total of 1086 patients who attended the haematuria clinics. The study included 168 males and 78 females who were recommended to have further CTU investigation after

Ultrasonography (USS) and cystoscopy. The study findings showed that Visible Haematuria (VH) was reported in 95% of cases. The overall negative predictive CTU rate was 96%.

**Study objectives:** The objectives of this study were to assess the distribution of non-urological pathologies on CT Urography (CTU) and to categorize the findings in order of importance and to determine the percentage of clinically significant findings that would require immediate management.

### MATERIALS AND METHODS

A total of 340 consecutive CT urograms were respectively reviewed between August 2011 and 2012. The CTU were performed using a two phase split doses (50+50 mL) protocol using a 16 or 64 slices CT (Philips, Netherlands). The 4 urologists assessed all the CT urograms.

All reported non-urological findings were recorded and classified according to reporting standard for the extra colonic findings in CT colonography in the following

patterns; E0 = Inadequate examination, E1 = Normal finding/variant, E2 = Abnormal finding requiring no charge in management, E3 = Abnormal finding with potential change in management, E4 = Significant abnormal findings that urgent action required.

Dual pathologies or more were often found on an individual scan. Every pathology was categorized separately, therefore, findings from a scan overlapped among 2 or more categories. The number of non-urolological findings in each group was as follows E0 = 0, E1 = 4 (there were few findings in this group as radiologists often tend not report normal variants) E2 = 90, E3 = 82, E4 = 29.

The obtained data were analyzed using SPSS Version 20. Descriptive statistics were used to present data in Table 1 and Fig. 1-4.

**RESULTS AND DISCUSSION**

The data presented in Table 1 showed demographic variables of study participants. A total of 340 patients were included. The mean age of study participants is 66.56 years. The study included 241 males and 99 females.

The results showed that a total of 136 (40%) of all cases of CT urograms detected non-urolological pathology. The findings were then categorized using the extra-colonic CT colonography criteria.

As shown in Fig. 1, the distribution of non-urolological pathologies in each classification included that 4 cases were classified in E1, 90 in E2, 82 in E3 and 29 in E4.

Figure 2 illustrates the distribution of E2 non-urolological findings. A total of 25 cases with hernias without bowels followed by 19 cases with ovarian cyst <5 cm, 15 cases with fibroids, 13 cases with hepatic hemangioma, 12 cases with porcelain gallbladder and 3 cases with lipoma. The distribution of gallstones, liver cysts and degenerative spinal disease included one case for each.

As shown in Fig. 3, the distribution of E3 non-urolological findings included the involvement of 45 cases with diverticulosis, 38 cases with adrenal adenomas, 32 cases with infrarenal aneurysm <5 cm, 26 cases with chronic pancreatitis, 19 cases with mesenteric panniculitis, 13 cases with hernias (containing bowel) and 3 cases with lung pathologies (excluding malignancy).

As shown in Fig. 4, non-neurological pathologies in the E4 group included 6 cases with pleural effusion, 6 cases with abdominal lymphadenopathy secondary to non-urolological causes, 5 cases with intra/extra hepatic duct dilatation and 4 cases with abdominal aortic aneurysm >5 cm. Figure 4 also showed that there was 1 case for each of the following pathologies: colon cancer, small bowel cancer, liver metastasis, foreign body

Table 1: Demographic variables of study variables

Variables	Description
<b>Gender</b>	
Male	241 (70.88%)
Female	241 (70.88%)
Age (M)	66.65 years
Total participants	340

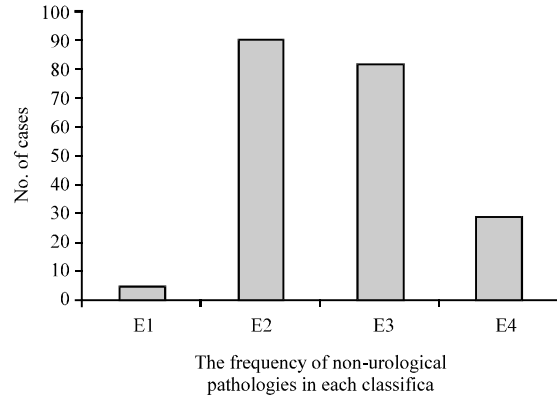


Fig. 1: The distribution of non-urolological pathologies in each classification

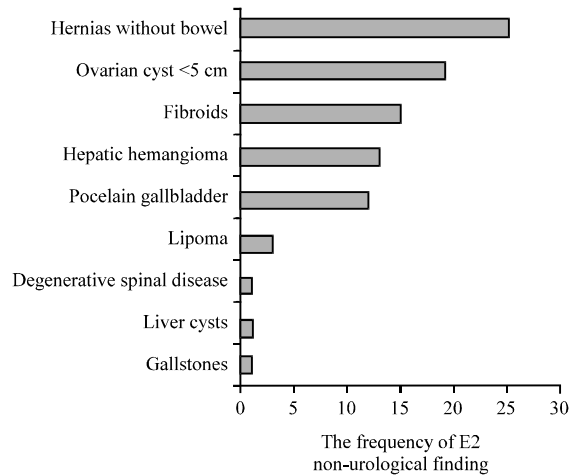


Fig. 2: The distribution of E2 non-urolological finding

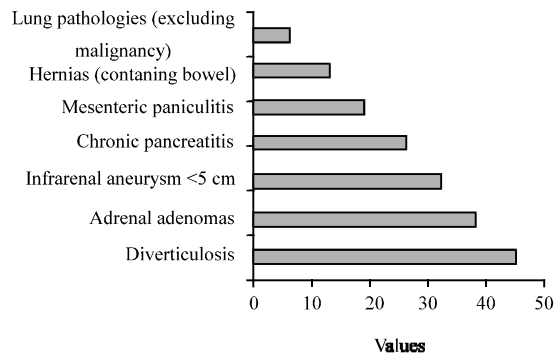


Fig. 3: The distribution of E3 non-urolological findings

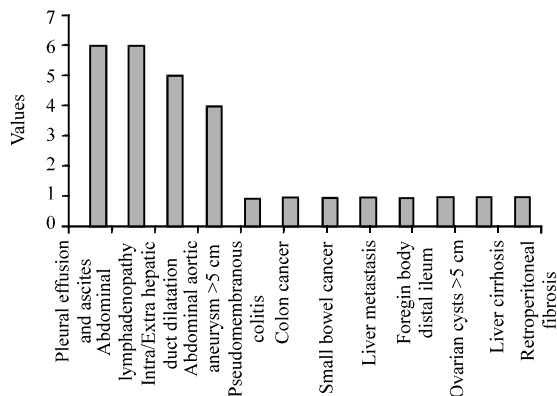


Fig. 4: The frequency of non-neurological pathologies in the E4 group

distal ileum, ovarian cyst >5 cm, liver cirrhosis and retroperitoneal fibrosis. From a historical point of view, IVU was the first imaging technique to be used for investigating haematuria (Smith *et al.*, 1995). The introduction of CTU has brought more diagnostic preference due to being more sensitive and specific imaging modality for renal tract disease than both IVU and ultrasound (Richenberg, 2008).

CTU has advantages over previous imaging techniques including the detection of clinically significant non-urological abnormalities (Devlin *et al.*, 2015). In their study, Liu *et al.* (2005) reported an incidence of highly significant non-urological findings at 18%. Our study reports a similar rate of 40%. In comparison, the rate of significant extra colonic finding in CT colonography was 11% (Zalis *et al.*, 2005).

The findings of the present study are consistent with other studies in which the majority of findings were within the E2 and E3 group. Gastroenterological and gynecological pathologies were the highest incidence of non-urological pathologies detected.

It is important to detect non-urological findings because significant morbidity and mortality may be prevented and can help in detecting the true underlying diagnosis (Liu *et al.*, 2005). However, the use of CTU has its own disadvantages such as the exposure to the re is a radiation dose involved. The dose of CTU is approximately three times the dose of IVU (Richenberg, 2008).

### CONCLUSION

A significant number of non-urological pathologies are detected on CTU of which in our study 40% are highly significant. In the investigation of haematuria, CTU offers

added advantage in detecting non-urological pathology, however, radiologists need a pragmatic approach when reporting these findings.

### REFERENCES

- Devlin, C.M., G. Hull, A. Coupland, K. Gill and A. Browning, 2015. CT urography as the first line investigation for haematuria: Is it truly indicated? A single centre analysis of the use of CT urography in the haematuria clinic. *J. Clin. Urol.*, 8: 390-395.
- Fielding, J.R., S.G. Silverman, S. Samuel, K.H. Zou and K.R. Loughlin, 1998. Unenhanced helical CT of ureteral stones: A replacement for excretory urography in planning treatment. *AJR. Am. J. Roentgenology*, 171: 1051-1053.
- Herschorn, S., S.B. Radomski, D.A. Shoskes, J. Mahoney and E. Hirshberg *et al.*, 1991. Evaluation and treatment of blunt renal trauma. *J. Urol.*, 146: 274-276.
- Kawashima, A., C.M. Sandler, R.D. Ernst, S.M. Goldman and B. Raval *et al.*, 1997. Renal inflammatory disease: The current role of CT. *Crit. Rev. Diagn. Imaging*, 38: 369-415.
- Liu, W., K.J. Morteale and S.G. Silverman, 2005. Incidental extraurinary findings at MDCT urography in patients with hematuria: Prevalence and impact on imaging costs. *Am. J. Roentgenology*, 185: 1051-1056.
- Richenberg, J., 2008. Haematuria. *Imaging*, 20: 57-72.
- Silverman, S.G., G.M. Israel, B.R. Herts and J.P. Richie, 2008. Management of the incidental renal mass. *Radiol.*, 249: 16-31.
- Silverman, S.G., J.R. Leyendecker and E.S. Amis, 2009. What is the current role of CT urography and MR urography in the evaluation of the urinary tract?. *Radiol.*, 250: 309-323.
- Smith, R.C., A.T. Rosenfield, K.A. Choe, K.R. Essenmacher and M. Verga *et al.*, 1995. Acute flank pain: Comparison of non-contrast-enhanced CT and intravenous urography. *Radiol.*, 194: 789-794.
- Sourtzis, S., J.F. Thibeau, N. Damry, A. Raslan and M. Vandendris *et al.*, 1999. Radiologic investigation of renal colic: Unenhanced helical CT compared with excretory urography. *Am. J. Roentgenology*, 172: 1491-1494.
- Van Der Molen, A.J., N.C. Cowan, U.G. Mueller-Lisse, C.C. Nolte-Ernsting and S. Takahashi *et al.*, 2008. CT urography: Definition, indications and techniques: A guideline for clinical practice. *Eur. Radiol.*, 18: 4-17.
- Zagoria, R.J., 2000. Imaging of small renal masses: A medical success story. *Am. J. Roentgenology*, 175: 945-955.
- Zalis, M.E., M.A. Barish, J.R. Choi, A.H. Dachman and H.M. Fenlon *et al.*, 2005. CT colonography reporting and data system: A consensus proposal. *Radiol*, 236: 3-9.