

## Blood Cellular and Biochemical Studies on Filariasis of Dogs

<sup>1</sup>Mohamed A. Hashem and <sup>2</sup>A.I.I. Badawy

<sup>1</sup>Department of Clinical Pathology, <sup>2</sup>Department of Parasitology,  
Faculty of Veterinary Medicine, University of Zagazig, Egypt

**Abstract:** The present research was done on 82 stray dogs to be investigated for filariasis, hematological and serum chemistry profiles of naturally infested dogs. Out of the examined dogs, 14 (17.1%) were infested with *Dipetalonema reconditum*, 12 (85.7%) of them were males and 2 dogs (14.3%) were females. Microfilariae appeared as a snake like with a rapidly, forward movement across the microscopic field in wet smear while in Giemsa stained smears showed a coiled or twisted appearance. Hematological studies revealed hemolytic anemia (macrocytic hypochromic type) associated with low erythrocyte counts, hemoglobin concentration and hematocrit value. A marked increase in erythrocyte sedimentation rate, reticulocyte, thrombocyte, total and differential leucocytic counts were encountered, in comparison with the control group. Biochemical analysis of sera from infested dogs showed a significant increase in serum alanine aminotransferase (ALT) and aspartate aminotransferase (AST) activities, serum bilirubin (total and indirect), total proteins, globulins, urea nitrogen, creatinine, inorganic phosphorus, potassium and a decrease in serum glucose, albumin, calcium and sodium values, with insignificant change in the magnesium level. It could be concluded that infestation of dogs with filariasis induced a hemolytic anemia, with disturbance in the liver and kidney functions.

**Key words:** Filariasis, hematology, serum enzymes, creatinine, dogs

### INTRODUCTION

Filariasis is one of the most important parasitic diseases caused by the filaroid nematodes with a world wide distribution and affects both man, animals and birds. In Egypt, while many previous studies on herbivorous animal filariasis were conducted both in Sharkia and other provinces throughout the country (El Seify *et al.*, 1990; Sakala, 2000; El Massry and Derbala, 2000; Arafa, 2002; Mahran, 2004; Bahmass, 2005) few studies dealt with filariasis of dogs (Bahmass, 2005; Fahmy, 1972; Ahmed *et al.*, 1986; Amer, 1986) and no records of filariasis in this animal species in Sharkia province were documented. On the other hand, local studies on hemoparasites in dogs with particular relation to hematological and biochemical dimensions are limited (Sharma and Pachauri, 1982).

From this point of view and since filariasis of dogs (dirofilariasis) represent a public health hazards to man (Gorezis *et al.*, 2006; Sathyan *et al.*, 2006), this study was conducted to investigate the dogs for filariasis and to study the blood cellular and biochemical changes in naturally filariasis infested dogs.

### MATERIALS AND METHODS

**Dogs and blood samples:** Blood samples were collected from 82 middle aged stray dogs and examined directly for filariasis. For haematological and biochemical analysis, blood samples were collected from 10 microfilaraemic dogs proved free from internal and external parasites through naked eye, blood and faecal examinations. As a control group, 5 dogs of a comparable age were treated with Praziquantel (5 mg kg<sup>-1</sup> body weight, orally) and Ivermectin (1 mL 50 kg<sup>-1</sup> body weight, subcutaneously) and proved to be free from internal and external parasites through repeatedly naked eye, faecal and blood examinations over a period of 3 months post treatment were used. Blood samples for haematological and biochemical analysis were divided into 2 portions as following: The 1st portion (5 mL) put in clean dry test tubes containing anticoagulants as sodium citrate 3.8% for determination of erythrocyte sedimentation rate, dipotassium salt of EDTA for studies of erythrogram and leucogram and ammonium oxalate 1% for platelet counts. The 2nd portion (6 mL) put in plain centrifuge tubes, left

undisturbed for clotting of the blood and the clear straw-coloured serum was carefully separated after centrifugation at 3000 rpm for 15 min and kept in the deep freezing at 20°C until subsequent biochemical analysis.

**Parasitological studies:** Wet smears, modified Knott technique (Newton and Wright, 1956) as well as Giemsa stained blood films were used to investigate dogs for microfilariae. The microfilariae were measured using a calibrated eye micrometer and photographed using Leitz microscope (Germany) and Canon digital photo camera (Japan). To study the microfilarial periodicity, blood samples were collected every 3 h from 3 microfilaraemic dogs and used to investigate the day periodicity of microfilariae using the technique of Ezzat and Tadros (1958). In brief, 0.5 mL of freshly collected blood was added to 1.5 mL of 2% glacial acetic acid in distilled water tinged with gentian violet. After thorough mixing, the tubes were left for 5 min then the number of microfilariae was counted in 0.1 mL of the mixture and multiplied by 40 to give the number of microfilariae in 1 mL blood.

**Hematological analysis:** The hematological parameters included erythrocyte sedimentation rate (ESR), red blood cell count (RBCs), hemoglobin concentration (Hb), packed cell volume (PCV), reticulocyte count (using Brilliant cresyl blue stained film), platelet count as well as total and differential leucocytic counts were performed using standard techniques as described by Feldman *et al.* (2000). The blood indices included mean corpuscular volume (MCV), mean corpuscular hemoglobin (MCH) and mean corpuscular hemoglobin concentration (MCHC) were calculated.

**Biochemical analysis:** Serum samples were colorimetrically analyzed for the activities of alanine aminotransferase (ALT), aspartate aminotransferase (AST), bilirubin (total, direct and indirect), glucose, total proteins, albumin, globulins (calculated as the difference between total proteins and albumin) as a biochemical indicators for liver function. Serum levels of urea nitrogen, creatinine, inorganic phosphorus, calcium, sodium, potassium and magnesium were used for evaluation of kidney function. All the biochemical analyses were measured using the determination methods according to manufacturer instructions (kits from Bio-merieux, France).

**Statistical analysis:** The obtained data in this study were computed and statistically analyzed using student's t-test according to Tamhane and Dunlop (2000).

## RESULTS

**Prevalence of filariasis of dogs:** Out of 82 examined dogs, 14 dogs (17.1%) were proved to be infested with *Dipetalonema reconditum* according to the microfilarial identification. Out of 14 infested dogs, 12 dogs (85.7%) were males and 2 dogs (14.3%) were females.

**Morphology of the microfilaria:** In wet blood smears, the microfilariae appeared as a snake like with a rapidly, forward movement across the microscopic field. Stained microfilariae appeared coiled or twisted to various degrees (Fig. 1a). The microfilarial length varied from about 250-260  $\mu\text{m}$  (aver.  $255 \pm 2.4 \mu\text{m}$ ), while the diameter varied from about 3.5-4.5  $\mu\text{m}$  (aver.  $4 \pm 0.24 \mu\text{m}$ ). The anterior end of the microfilariae devoid from nuclei to a distance about 7-8  $\mu\text{m}$  (aver.  $7 \pm 0.45 \mu\text{m}$ ), (Fig. 1b). The nerve ring and excretory pore located at about 28-32  $\mu\text{m}$  (aver.  $30 \pm 0.68 \mu\text{m}$ ) and 40-44  $\mu\text{m}$  (aver.  $42 \pm 0.84 \mu\text{m}$ ) from the anterior end,

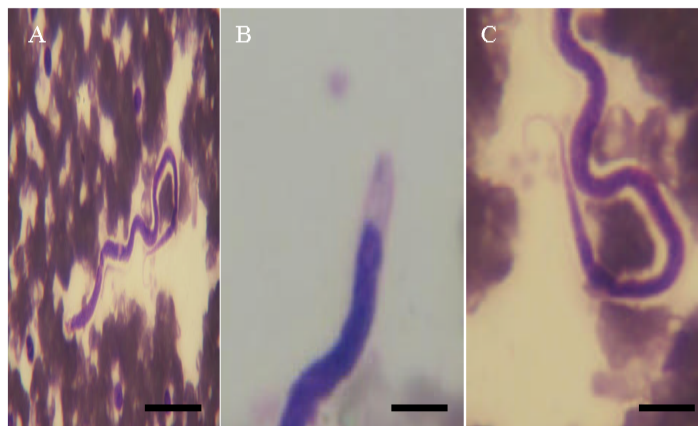


Fig. 1: The microfilaria of *Dipetalonema reconditum*, Giemsa stained. (A): The whole microfilaria (Bar = 30  $\mu\text{m}$ ), (B): The anterior end of the microfilaria with no nuclei (Bar = 7  $\mu\text{m}$ ), (C): The posterior end of the microfilaria showing a characteristic hooked tail (Bar = 10  $\mu\text{m}$ )

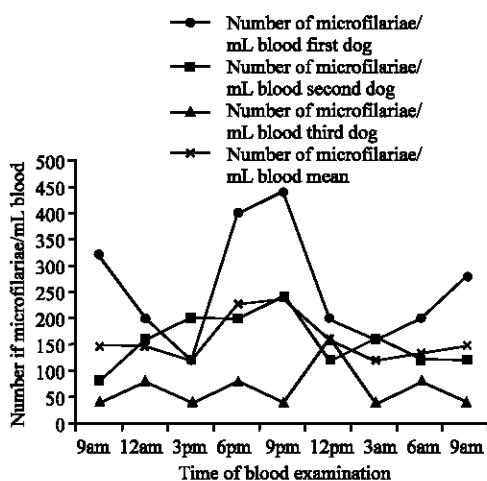


Fig. 2: *Dipetalonema reconditum*, a summer day microfilarial periodicity

Table 1: Blood cellular parameters in the control and infested dogs with *Dipetalonema reconditum* (Mean values±SD)

Parameters	Normal dogs	Infested dogs
Erythrocyte sedimentation rate (mm h <sup>-1</sup> )	2.45±0.12	3.73±0.16*
Red blood cell count (×10 <sup>6</sup> μL <sup>-1</sup> )	6.5±0.45	3.4±1.12**
Hemoglobin concentration (g dL <sup>-1</sup> )	16.0±1.12	9.5±1.12**
Packed cell volume (%)	40.0±2.42	28.0±1.12**
Mean corpuscular volume (fl)	61.53±5.6	82.35±1.12*
Mean corpuscular hemoglobin (Pg)	24.61±3.15	27.94±1.12*
Mean corpuscular hemoglobin concentration (%)	40.0±4.37	33.92±1.12*
Reticulocytes (%)	1.2±0.02	2.5±1.12**
Platelets (×10 <sup>3</sup> μL <sup>-1</sup> )	450±17.61	760±17.61**
Total leukocytic count (×10 <sup>3</sup> μL <sup>-1</sup> )	8.5±1.12	16.6±1.12**
Segmented Neutrophils (×10 <sup>3</sup> μL <sup>-1</sup> )	4.0±0.2	6.5±0.2*
Band neutrophils (×10 <sup>3</sup> μL <sup>-1</sup> )	0.1±0.001	0.4±0.01**
Lymphocytes (×10 <sup>3</sup> μL <sup>-1</sup> )	3.4±0.15	5.4±0.15*
Monocytes (×10 <sup>3</sup> μL <sup>-1</sup> )	0.7±0.05	2.5±1.35**
Eosinophils (×10 <sup>3</sup> μL <sup>-1</sup> )	0.3±0.01	1.8±1.25**

\*p≤0.05 \*\*p≤0.01

respectively. The anal pore located at about 60-70 μm (aver. 65±0.98 μm) from the tail end which showed mostly a hooked appearance (Fig. 1c).

**Microfilarial periodicity:** As shown in Fig. 2, the number of microfilariae increased significantly in the peripheral blood toward the evening (nocturnal periodicity) and peaked between 6-9 pm.

**Blood cellular findings:** Blood cellular analysis of *Dipetalonema reconditum* infested dogs revealed a significant reduction in RBCs counts, Hb content, PCV value and increase in reticulocyte count, MCV, MCH with a decrease in MCHC, indicating the presence of regenerative anemia of macrocytic hypochromic type. The values of ESR, reticulocyte, thrombocyte, total and differential leucocytic counts were significantly increased, in comparison with the control group (Table 1).

Table 2: Liver function tests in the control and infested dogs with *Dipetalonema reconditum* (Mean values±SD)

Parameters	Normal dog	Infested dog
Alanine aminotransferase (U L <sup>-1</sup> )	55.24±2.05	120.66±4.30**
Aspartate aminotransferase (U L <sup>-1</sup> )	80.0±1.4	150.0±5.33**
Total bilirubin (mg dL <sup>-1</sup> )	0.4±0.06	1.05±0.2**
Direct bilirubin (mg dL <sup>-1</sup> )	0.15±0.01	0.15±1.12
Indirect bilirubin (mg dL <sup>-1</sup> )	0.25±0.03	0.90±0.02**
Glucose (mg dL <sup>-1</sup> )	86.0±1.76	40.8±1.12*
Total protein (g dL <sup>-1</sup> )	7.00±0.75	8.95±0.16*
Albumin (g dL <sup>-1</sup> )	3.70±0.55	3.0±0.04*
Globulins (g dL <sup>-1</sup> )	3.30±0.61	5.95±0.32*

\*p≤0.05 \*\*p≤0.01

Table 3: Kidney function tests in the control and infested dogs with *Dipetalonema reconditum* (Mean values±SD)

Parameters	Normal dog	Infested dog
Urea nitrogen (mg dL <sup>-1</sup> )	25.0±1.77	73.92±2.04**
Creatinine (mg dL <sup>-1</sup> )	1.2±0.02	1.5±0.02*
Inorganic phosphorus (mg dL <sup>-1</sup> )	2.8±0.02	3.5±1.12*
Calcium (mg dL <sup>-1</sup> )	10.5±1.1	8.4±1.12*
Sodium (mEq L <sup>-1</sup> )	141.4±12.5	125.8±17.61*
Potassium (mEq L <sup>-1</sup> )	4.5±1.12	6.6±0.72*
Magnesium (mg dL <sup>-1</sup> )	1.9±0.2	2.0±0.2

\*p≤0.05 \*\*p≤0.01

**Biochemical findings:** Liver function tests of sera from infested dogs showed a significant (p≤0.01) increase in the serum activities of alanine aminotransferase (ALT) and aspartate aminotransferase (AST), serum bilirubin (total and indirect), total proteins, globulins and a decrease (p≤0.05) in the serum values of glucose and albumin, with insignificant change in the serum direct bilirubin, when compared with control (Table 2).

Kidney function tests in infested dogs revealed a significant increase in serum urea nitrogen (p≤0.01), creatinine, inorganic phosphorus, potassium and a decrease in the serum calcium and sodium levels (p≤0.05) while, the serum magnesium level showed insignificant change, comparatively with control (Table 3).

## DISCUSSION

In the present study, a survey was conducted to investigate the dogs for filariasis, as well as the blood cellular and biochemical changes in naturally infested dogs. Out of 82 examined dogs, 14 (17.1%) were infested with *Dipetalonema reconditum*. A nearly similar infestation rates of dogs with *Dipetalonema reconditum* were also reported, in which 22.6% of dogs were infested in Brazil (Reifur *et al.*, 2004) and 15.9% infestation rate was reported in dogs from South Italy (Cringoli *et al.*, 2001). While, lower infestation rates with *Dipetalonema reconditum* were also recorded in dogs in Egypt and other countries, where 0.063% of dogs from Abu Rawach, Giza, Egypt proved to be infested (Amer, 1986), 1.0% of dogs in Spain were infested (Ortega-Mora *et al.*, 1991), less than 0.5% infestation rate in the State of Washington (Thies *et al.*, 2001) and 6% in Western Sicily,

Italy (Giannetto *et al.*, 1997). Reasons for these differences in infestation rates in these studies may be attributed to the locality, distribution and prevalence of the arthropod vectors of this parasite such as fleas, lice and ticks, which in great part affected by the different climatic conditions in these regions as well as the methods of examination of dogs for filariasis. High infestation rate was recorded in male dogs (85.7%) than in females (14.3%). Similar results were stated by Falls and Platt (1982), Amer (1986). This is might be returned to hormonal effect on susceptibility of dogs to infestation.

Regarding the observed characteristic morphological features of *Dipetalonema reconditum* microfilariae in this study, there was no contradiction with the previous descriptions (Nelson, 1962; Kellay, 1973; Watson *et al.*, 1973; Soulsby, 1982). Concerning with the microfilarial periodicity of *Dipetalonema reconditum*, this study showed a nocturnal periodicity of the microfilariae and peaked between 6-9 pm. These results were to some extent in agreement with the results of Newton and Wright (1956) who reported a nocturnal periodicity of microfilariae of *Dipetalonema reconditum* with 2 peaks at 6.0 and 12 pm and Korkejian and Edeson (1978) who noticed nocturnal periodicity of microfilariae of *Dipetalonema reconditum*. Also, Amer (1986) observed increase the number microfilariae of this parasite in peripheral blood of infested dogs between 6.30-10.30 pm during the different seasons of the year.

Concerning the hematological results in the present research, a regenerative anemia of macrocytic hypochromic type associated with a reduction in the RBCs count, Hb concentration and PCV value were recorded, with an increase of ESR, reticulocyte, thrombocyte, total and differential leucocytic counts. The macrocytosis and hypochromasia were due to reticulocytosis that seen in the infested dogs with microfilariae. The present anemia may be attributed to the hemolysis of RBCs as a result of destructive motility of microfilaria as reported by Ishihara *et al.* (1978, 1981) and Kitagawa *et al.* (1989) who showed a severe intravascular hemolysis with a significant reduction of RBCs count and Hb concentration in dogs with dirofilariasis. Ziegler *et al.* (1991) found intravascular hemolytic anemia (macrocytic up to 80 days after infection, subsequently normocytic and hypochromic), accompanied by reticulocytosis in the rodent, *Mastomys natalensis*, infested with *Litomosoides carinii*. Similar findings were obtained by previous authors (Sharama and Pachauri, 1982; Kitagawa *et al.*, 1998; Nielsen *et al.*, 2006; Anuchai *et al.*, 2007). Moreover, Sharma and Joshi (2002) showed a decrease in the erythrogram of microfilariae

infested cattle. Reifur *et al.* (2004) reported a significant macrocytic anemia in dogs infested with 3 different microfilariae: *Dirofilaria immitis*, *D. reconditum* and the third (mf3) were not identified. The latter authors mentioned that *D. reconditum* was the species with the highest prevalence (22.6%), while *Dirofilaria immitis* was 5.47%. Our results disagree with Anuchai *et al.* (2006) who found moderate microcytic anemia and severe thrombocytopenia in 7 dogs infested with dirofilariasis, ehrlichiosis and babesiosis. The difference may be attributed to the complicated infestations in these dogs, while in our study; we found only *D. reconditum* microfilariae.

The higher ESR value in infested animals may be due to the anemia. It may also be due to auto-agglutination that is observed in this disease during infection. The increase in ESR has been observed in many other diseases where autoagglutination of red blood cells takes place as in malaria and tuberculosis (Hagan and Bruner, 1991). Similar results were obtained in canine with dirofilariasis (Sharma and Pachauri, 1982), in microfilariae-infested cattle (Sharma and Joshi, 2002), in haemoparasitized camels with *Trypanosoma evansi* and *Dipetalonema evansi* (Shafqaat *et al.*, 2004) and in an owl with microfilaraemia (Bedin *et al.*, 2007).

Thrombocytosis observed in hemoparasitized dogs could be related to the hemolytic anemia (Sharma and Pachauri, 1982; Makiya, 1997). On contrary, thrombocytopenia was obtained by Rawlings (1982) and Anuchai *et al.* (2007) in dogs infested with *Dirofilaria immitis*.

The leukogram revealed a marked leucocytosis with neutrophilia, eosinophilia, lymphocytosis and monocytosis. The higher blood neutrophil and monocyte counts were for the phagocytic removal of tissue breakdown products or microfilariae. Similarly, Paltrinieri *et al.* (1998) showed neutrophilic leucocytosis in dogs with dirofilariasis. The observed eosinophilia was due to sensitivity to the foreign protein of a parasite which may be a part of an immune phenomenon (Feldman *et al.*, 2000). The lymphocytosis which develops in dogs infested with blood parasite is presumably due to intense antigenic stimulations which increase the demands for lymphocytes to be transformed into plasma cells for antibodies production. Yamagata *et al.* (1995) found lymphocytosis with increases in IgE values in dogs experimentally co-infested with *Dirofilaria immitis* and *Ancylostoma caninum*. The authors mentioned that parasitic nematodes that undergo blood and tissue migrations increased IgE and IgG values. The results of the leukogram were in agreement with the findings of others (Sharma and Pachauri, 1982; Anuchai *et al.*, 2007; Sharma and Joshi, 2002; Rawlings, 1982; Gossett *et al.*, 1987).

Concerning the biochemical results, an increase in the serum enzyme activities (ALT and AST), serum bilirubin (total and indirect) and a decrease in the serum glucose level were observed in the dogs infested with *D. reconditum*, when compared with the non infested one. The increased serum enzymes and hypoglycemia demonstrated in microfilariaemic dogs suggested liver dysfunction secondary to circulatory disturbance. In addition, the hypoglycemia was attributed to glucose consumption by the *Dipetalonema viteae* and *B. pahangi* parasites (Court *et al.*, 1986). The hyperbilirubinemia (total and indirect) may be attributed to hemolytic anemia with resultant hemolytic jaundice. The obtained results were in harmony with earlier findings (Sharma and Pachuri, 1982; Ziegler *et al.*, 1991; Anuchai *et al.*, 2006, 2007; Shafqaat *et al.*, 2004; Kitagawa *et al.*, 1997).

Protein profile of serum samples showed an increase in the total protein and globulins concentration with a decrease in the albumin values in the infested dogs with microfilariae comparatively with non-infested one. The observed hyperproteinemia can be attributed on the one hand to an increase in the  $\gamma$ -globulin concentration in response to the parasitic antigens and on the other had to a release of hemoglobin from destructed erythrocytes (Moustafa *et al.*, 1991). The obtained hypoalbuminemia probably corresponds to the degenerative changes in the haemoparasitized organs (mainly liver). Similar results have been reported previously (Kitagawa *et al.*, 1998; Sharma and Joshi, 2002; Shafqaat *et al.*, 2004; Safwat and El-Abdin, 1982).

The significantly higher serum urea nitrogen, creatinine, inorganic phosphorus, potassium and lower serum calcium and sodium levels in infested dogs than in non infested one might result from more severe kidney dysfunction, metabolic acidosis, as well as intravascular hemolysis (Kitagawa *et al.*, 1989, 1998; Anuchai *et al.*, 2006).

### CONCLUSION

A hemolytic anemia with disturbance in the liver and kidney functions were the main results in canine filariasis, caused by *Dipetalonema reconditum*.

### ACKNOWLEDGMENT

We thank all the staff members of Clinical Pathology and parasitology Departments, Faculty of Veterinary Medicine, Zagazig University, for their valuable help and continuous facilities which made the work calmly achieved.

### REFERENCES

- Ahmed, B.A., O.H. Amer and S.A. Fayek, 1986. New record for *Dirofilaria repens* (Raillet and Henry, 1911). Adult worm and its pathogenesis in naturally infested dogs in Egypt. *Zagazig Vet. Med. J.*, 16 (1): 89-98.
- Amer, O.H., 1982. Some studies on filaria in dogs. Ph. D. Thesis, Faculty of Veterinary Medicine, Zagazig University, 1986. Sharma MC, Pachauri sp. Blood cellular and biochemical studies in canine dirofilariasis. *Vet. Res. Commun.*, 5 (3): 295-300.
- Anuchai, N., A. Sukullaya, T. Somporn, S. Siram and K. Morakot, 2007. Canine dirofilariasis and concurrent tick-borne transmitted diseases in Bangkok, Thailand. *J. Comp. Clin. Pathol.*, 15 (4): 249-253.
- Anuchai, N., K. Morakot, T. Sonthaya, T. Somporn and S.A. Siram, 2007. Retrospective study of the clinical hematology and the serum biochemistry tests made on canine dirofilariasis cases in an animal hospital population in Bangkok, Thailand. *Res. Vet. Sci.*, 82 (3): 364-369.
- Arafa, M.I., 2002. Studies on ecto and endoparasites of equines in Assiut Governorate. Ph.D Thesis. Faculty of Veterinary Medicine Assiut University.
- Bahnass, M.M., 2005. Studies on filariasis in some farm animals. M.Sc Thesis, Faculty of Veterinary Medicine, Zagazig University, 2005.
- Bedin, M., C. Petterino, E. Gallo, P. Selleri and M. Morgante, 2007. Clinical Pathological Findings in an Owl (*Athene noctua*) with Microfilaraemia in Italy. *J. Vet. Med. A. Physiol. Pathol. Clin. Med.*, 54 (3): 128-130.
- Court, J.P., M. Martin-Short and G.M. Lees, 1986. A comparison of the response of *Dipetalonema viteae* and *Brugia pahangi* adult worms to antifilarial agents. *Trop. Med. Parasitol.*, 37(4): 375-380.
- Cringoli, G., L. Rinaldi and G. Capelli, 2001. A prevalence survey and risk analysis of filariosis in dogs from the Mt. Vesuvius area of southern Italy. *Vet. Parasitol.*, 102 (3): 243-252.
- El Seify, M.A., M.A. El Askalany and S.M. Rashad, 1990. Biochemical changes in serum of buffaloes naturally infected with microfilariae in Beni-seuf Governorate. *Egypt J. Comp. Pathol. Clin. Pathol.*, 3 (1): 27-36.
- El-Massry, A.A. and A.A. Derbala, 2000. Evidence of *Onchocerca fasciata* (Filaroidea: Onchocercidae) in camels (*Camelus dromedaries*): Prevalence, nodular lesions appearance and parasite morphology. *Vet. Parasitol.*, 88 (3-4): 305-312.

- Ezzat, M.A.E. and G. Tadros, 1958. A simple method for counting microfilariae in blood of animals. *Agric. Res. Rev.*, 36 (4): 38-44.
- Fahmy, L.S., 1972. Some surgical problems caused by filariae in domesticated animals. M.Sc Thesis, Faculty of Veterinary Medicine, Cairo University.
- Falls, R.K. and T.R. Platt, 1982. Survey of heart worm, *Dirofilaria immitis* and *Dipetalonema reconditum* (Nematoda, Filarioidea) in dogs from Virginia and North Carolina. *Am. J. Vet. Res.*, 43 (4): 738-739.
- Feldman, B.F., J.G. Zinkl and N.C. Jain, 2000. *Schalm's Veterinary Hematology*. 5th Edn. Lippincott Williams and Wilkins. A Walters Company. Philadelphia, Baltimore, New York, London, Buenos Aires, Hong Kong, Sydney, Tokyo.
- Giannetto, S., S. Pampiglione, V. Santoro and A. Virga, 1997. Research of canine filariasis in Trapani province (western Sicily). Morphology on SEM of male *Dirofilaria repens*. *Parasitologia*, 39 (4): 403-405.
- Gorezis, S., M. Psilla and I. Asproudis *et al.*, 2006. Intravitreal dirofilariasis: A rare ocular infection. *Orbit*, 25 (1): 57-59.
- Gossett, K.A., C.R. Root, B. Cleghorn, G.E. Church and M.A. Turk, 1987. Effects of heartworm and intestinal parasitic infections on hematology and peripheral lymph node cytology in Louisiana dogs. *Vet. Clin. Pathol.*, 16 (4): 97-101.
- Hagan, W.A. and D.W. Bruner, 1991. *The Infectious Diseases of Domestic Animals*. Comstock Pub. Assoc., A divisional Cornell Univ. Press, Ithaca, New York, USA.
- Ishihara, K., H. Kitagawa, M. Ojima and Y. Suganuma, 1978. Clinicopathological studies on canine dirofilarial hemoglobinuria. *Nippon Juigaku Zasshi*, 40 (5): 525-537.
- Ishihara, K., H. Kitagawa, S. Yokoyama and H. Ohashi, 1981. Studies on hemolysis in canine dirofilarial hemoglobinuria. Lipid alterations in blood serum and red cell membrane. *Nippon Juigaku Zasshi*, 43 (1): 1-11.
- Kelly, J.D., 1973. Detection and differentiation of microfilariae in canine blood. *Aus. Vet. J.*, 49 (1): 23-27.
- Kitagawa, H., K. Kitoh and Y. Ohba *et al.*, 1998. Comparison of laboratory test results before and after surgical removal of heartworms in dogs with vena caval syndrome. *J. Am. Vet. Med. Assoc.*, 213 (8): 1134-1136.
- Kitagawa, H., K. Kitoh, T. Iwasaki and Y. Sasaki, 1997. Comparison of laboratory data in dogs with heartworm caval syndrome surviving and non surviving after surgical treatment. *J. Vet. Med. Sci.*, 59 (7): 609-611.
- Kitagawa, H., Y. Sasaki and K. Ishihara, 1989. Clinical studies on canine dirofilarial hemoglobinuria: Measured and calculated serum osmolalities and osmolar gap. *Nippon Juigaku Zasshi*, 51 (4): 703-710.
- Korkejian, A. and J.F. Edeson, 1978. Studies on naturally occurring filarial infections in dogs in Lebanon. I. *Dipetalonema reconditum*. *Ann. Trop. Med. Parasitol.*, 72 (1): 65-78.
- Mahran, O.N., 2004. Some studies on blood parasites in camels (*Camelus dromedaries*) at Shalatin city, Red Sea Governorate. *Assiut. Vet. Med. J.*, 50 (102): 172-184.
- Makiya, K., 1997. Recent increase of human infections with dog heartworm *Dirofilaria immitis* in Japan. *Parassitologia*, 39 (4): 387-388.
- Moustafa, A.M., B. Agag, M. Esmat and A.M. Selim, 1991. Studies on filariasis in Egyptian buffaloes. III. Clinical observations and electrophoretic patterns in sera of naturally infested buffaloes with microfilaria before and after treatment with stipophon. *Zagazig Vet. J.*, 19: 583-595.
- Nelson, G.S., 1962. *Dipetalonema reconditum* (Grassi, 1889) from the dog with a note on its development in the flea, *Ctenocephalides felis* and the louse, *Heterodoxus spiniger*. *J. Helminthol.*, 3: 297-308.
- Newton, W.I. and W.H. Wright, 1956. The occurrence of dog filariid other than *Dirofilaria immitis* in the United States. *J. Parasitol.*, 42: 246-248.
- Nielsen, N.O., P.E. Simonsen, P. Magnussen, S. Magesa and H. Friis, 2006. Cross-sectional relationship between HIV, lymphatic filariasis and other parasitic infections in adults in coastal northeastern Tanzania. *Trans. R. Soc. Trop. Med. Hyg.*, 100 (6): 543-550.
- Ortega-Mora, L.M., M. Gomez-Bautista, F. Rojo-Vazquez, A. Rodenas and J.A. Guerrero, 1991. Survey of the prevalence of canine filariasis in Spain. *Prev. Vet. Med.*, 11: 63-68.
- Paltrinieri, S., P. Sartorelli, B. De Vecchi and F. Agnes, 1998. Metabolic findings in the erythrocytes of cardiopathic and anaemic dogs. *J. Comp. Pathol.*, 118 (2): 123-133.
- Rawlings, C.A., 1982. Clinical laboratory evaluations of seven heartworm infested beagles: During disease development and following treatment. *Cornell Vet.*, 72 (1): 49-56.
- Reifur, L., V. Thomaz-Soccol and F. Montiani, 2004. Epidemiological aspects of filariosis in dogs on the coast of Parana state, Brazil: With emphasis on *Dirofilaria immitis*. *Vet. Parasitol.*, 122 (4): 273-286.
- Safwat, M.S. and Y.Z. El-Abdin, 1982. Some biochemical studies on the serum of infested and non-infested camels with *Dipetalonema evansi*. *Egyptian J. Vet. Sci.*, 19: 141-145.

- Sakla, A.A., 2000. Parasitological studies on filariasis in Assiut Governorate. *Assiut Med. J.*, 24 (1): 37-46.
- Sathyan, P., P. Manikandan and M. Bhaskar *et al.*, 2006. Subtenons infection by *Dirofilaria repens*. *Indian J. Med. Microbiol.*, 24 (1): 61-62.
- Shafqaat, A., A.A. Butt, G. Muhammad, M. Athar and M.Z. Khan, 2004. Haemato-biochemical studies on the haemoparasitized camels. *Int. J. Agric. Biol.*, 6 (2): 331-334.
- Sharma, M. and C. Joshi, 2002. Serum mineral and haemato-biochemical profile of microfilariae infested cattle in India: Its effects on production and therapy. *Asian Aus. J. Anim.*, 15 (3): 357-365.
- Sharma, M.C. and S.P. Pachauri, 1982. Blood cellular and biochemical studies in canine dirofilariasis. *Vet. Res. Commun.*, 5 (3): 295-300.
- Soulsby E.J.L. Helminthes, 1982. Arthropodes and Protozoa of Domesticated animals. 7th Edn. Bailliere Tindall, London.
- Tamhane, A.C. and D.D. Dunlop, 2000. Statistical and data analysis from elementary to intermediate. Upper Saddle River, USA.
- Theis, J., F. Stevens and M. Law, 2001. Distribution, prevalence and relative risk of filariasis in dogs from the State of Washington (1997-1999). *J. Am. Anim. Hosp. Assoc.*, 37 (4): 339-347.
- Watson, A.D., F.J. Testoni and W.L. Porges, 1973. A comparison of microfilariae isolated from canine blood by the modified Knott test and a filter method. *Aus. Vet. J.*, 49 (1): 28-30.
- Yamagata, G.R., L.J. Gershwin and M.M. Wong, 1995. Diethylcarbamazine-induced *Dirofilaria immitis* larval death, as indicated by immunoglobulin E concentration, in dogs with concurrent *Ancylostoma caninum* infection. *Am. J. Vet. Res.*, 56 (2): 174-178.
- Ziegler, C., I. Käufer-Weiss and H. Zahner, 1991. On the pathogenesis of anaemia and leukopenia in filarial (*Litomosoides carinii*) infection of *Mastomys natalensis*. *Zentralbl Veterinarmed B*, 38 (2): 123-134.