

## Case Report: Atresia of the Left Oviduct and Anomaly of the Caecum of a 12 Month Old Layer

<sup>1</sup>M.H. Sulaiman, <sup>2</sup>L. Saidu and <sup>3</sup>P.A. Abdu

<sup>1</sup>Department of Veterinary Anatomy, Faculty of Veterinary Medicine,  
Ahmadu Bello University, Zaria, Kaduna State, Nigeria

<sup>2</sup>Veterinary Teaching Hospital, Ahmadu Bello University, Zaria, Nigeria

<sup>3</sup>Department of Veterinary Surgery and Medicine, Faculty of Veterinary Medicine,  
Ahmadu Bello University, Zaria, Nigeria

---

**Abstract:** This study describe a rare case of congenital defects involving the atresia of the left oviduct with the accompanying abnormalities of ovaries and caecum observed in a 12 month old layer presented to the Avian Ambulatory Clinic of the Veterinary Teaching Hospital, Ahmadu Bello University, Zaria. At post mortem, a thin wall oviduct measuring 18 cm long which opens into the cloaca was noticed while the left oviduct was completely absent. In addition the right hypolastic oviduct had a large cyst with a morphometric measurement of 18 cm by 14 cm by 7 cm and containing 1.25 L of clear non proteinous fluid, weighing 1.01 kg. When the cystic fluid was cultured in blood agar at 37°C for 72 h, no bacteria colony growth was observed. However, biochemical analysis revealed a composition of electrolytes. The bird also had undeveloped ovaries, malformed illeocaecal junction cranially measuring 6.5 cm.

**Key words:** Atresia, left oviduct, ovaries, caecum, post mortem, non proteinous, fluid

---

### INTRODUCTION

**Case history and clinical findings:** A 12 month old layer was presented to the avian ambulatory clinic of the Veterinary Teaching Hospital, Ahmadu Bello University Zaria, Nigeria. The chief complaint is that of reluctance to move with disproportionate size when compared with other birds in the flock. Clinical examination revealed a distended abdomen, movement with discomfort and penguin-like posture. The chicken weight 7.2 kg was alert, nervous, responsive and generally in good body flesh.

### POSTMORTEM EXAMINATION AND FINDINGS

Routine post mortem examination was conducted on the presented chicken and on a representative from the flock and the following findings were recorded the beak, tongue, esophagus, crop (filled with ingested feed), gizzard, proventriculus, small intestines of the chickens were all in the normal anatomical position. However, underdeveloped Ovaries (O) and a thin-walled oviduct (V) approximately 18 cm in length which opens into the cloaca with the atresia of the left oviduct were observed as shown in (Fig. 1a). Normal Ovaries (NO) and Normal left

oviduct (NV) from an apparently healthy flock mate was observed as in (Fig. 1b). An abnormally deformed illeocaecal junction was noticed where a long segment (6.5 cm) of the ileum detached from the main ileum and runs parallel to terminate at the cloaca while the main ileum continues and terminate into two blind sacs, the caecal pouches.

These caecal pouches are underdeveloped and because of the absence of a normal anatomical illeocaecal junction, the content of the caecal pouches are voided back into the ileum distally (Fig. 2a) as compare to an anatomically normal junction and caecal pouches as in (Fig. 2b) from a flock mate.

A persistent hypoplastic right oviduct with a large cyst attached to it was also recorded and morphometrically measuring 18 cm by 14 cm by 7 cm and containing 1.25 L of clear non-proteinous fluid with a diameter of 12 cm and weighed 1.0 kg (Fig. 3). The cystic fluid was aspirated using a 5 mL sterile syringe and 18 gauge needle and cultured in blood agar (SIGMA, USA) for 72 h at 37°C. Following the period of incubation no growth of any bacterial colony was observed. However, chemical analysis of the cystic fluid revealed it content to be made up of electrolytes as in Table 1.

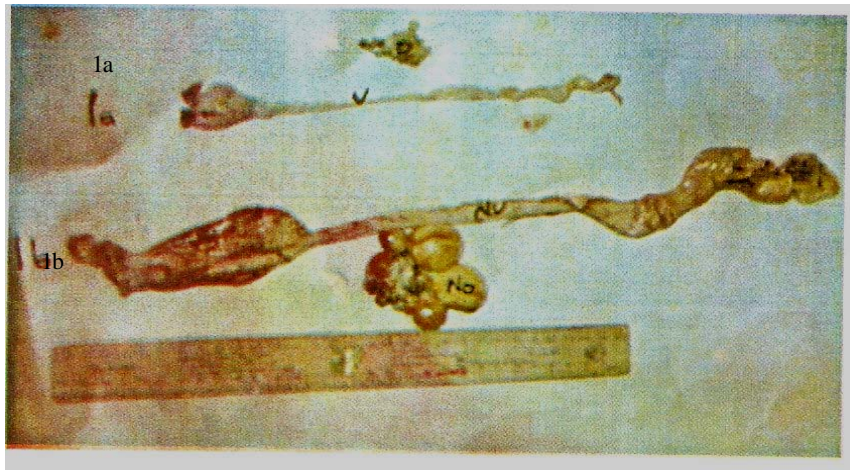


Fig. 1: (a, b) Underdeveloped ovaries; a thin-walled oviduct and normal ovaries and left oviduct, respectively



Fig. 2: (a, b) Abnormally deformed illeocaecal junction, caecal pouches and an anatomically normal illeocaecal junction and caecal pouches

The right oviduct develops as in the left oviduct from the Mullerian Ducts, until shortly after the end of the undifferentiating stage (end of the 6th day of incubation) when the left oviduct is longer than the right (Aitken and Johnson, 1963). In birds, the female embryo has a pair of undifferentiated gonads and the Mullerian ducts. However, during the course of differentiation of the female avian embryo, only the left ovary and the Mullerian duct develop whereas the right ovary and the Mullerian duct regress (Yonju *et al.*, 2004).

Usually this is the normal developmental sequence. However, It was noticed in this case report that the left oviduct was atretic while the right oviduct was hyperplastic and this has not been previously reported elsewhere. In the male embryo, the Mullerian duct undergoes regression and disappears by day 12 of incubation (Yonju *et al.*, 2004). Conversely in the female

embryo both the left and the right Mullerian duct engage in a linear rate of growth until day 12 of incubation (Teng, 1987). Subsequently, the right Mullerian duct undergoes a relative slow involution from the anterior to posterior thereafter and completely disappears at the time of hatching (Romanoff, 1960). The left Mullerian duct continues to grow and develops into the oviduct i.e., infundibulum, magnum, isthmus, shell gland and vagina (Yonju *et al.*, 2004).

The lumen of the right oviduct becomes lost in craniocaudal direction starting from the 8th day of incubation. Regression of the right oviduct is normally completed within this period with its total disappearance except for a short stump which remains attached to the cloaca (Grunewal, 1942). However, if this regression of the right oviduct is not complete, partial development will

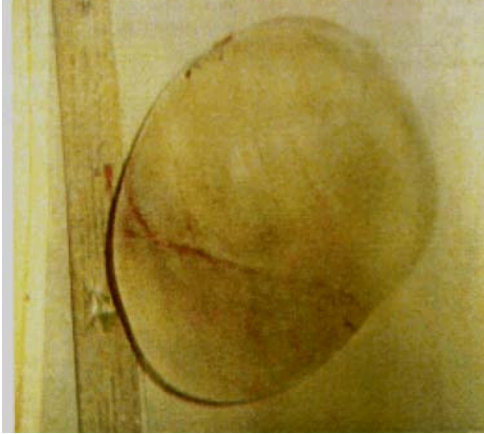


Fig. 3: Hypoplastic right oviduct with a large cyst

Table 1: Chemical analysis of the cystic fluid

Fluid content	Observed values	Normal values (serum)
Protein	0	2.3-10 g dL <sup>-1</sup>
Specific gravity	1.001	1.005-1.020
Urea	0.8 Mmol L <sup>-1</sup>	2.5-6.5 Mmol L <sup>-1</sup>
Sodium	150 Mmol L <sup>-1</sup>	136-145 Mmol L <sup>-1</sup>
Potassium	4.5 Mmol L <sup>-1</sup>	3.6-5.2 Mmol L <sup>-1</sup>
Chloride	110 Mmol L <sup>-1</sup>	94-108 Mmol L <sup>-1</sup>
Bicarbonate	23 Mmol L <sup>-1</sup>	24-32 Mmol L <sup>-1</sup>

result in a cystic right oviduct (Riddell, 1997). This was the cause of the hypoplastic right oviduct with a large fluid filled cysts seen in this case. The regression of the Mullerian duct is caused by Anti-Mullerian Hormone (AMH), a member of the transforming growth factor- $\beta$  family (Hutson *et al.*, 1981; Teng, 1987). Reports have also suggested that estrogen protects the left Mullerian duct from regression.

For example, exposure to estrogen during egg incubation prevents the right Mullerian duct from regression in the female chicken embryos (Doi and Hutsen, 1988; Hamilton, 1961; Hutson *et al.*, 1982). This may be responsible for the persistent right oviduct observed in this case report. Hlozankova and Zelenka (1978) in their study of the right Mullerian duct during postnatal ontogenesis observed a thread structure of several millimeters in length in 1 day old females develops in chicks into a long, thin-walled ampulla filled with clear fluid.

The cysts seen in this case was also filled with clear non-proteinous fluid. Stoll and Faucounau (1987) reported that norethindrone produces two effects on the Mullerian ducts of females chicks embryo. It induces the loss of the lower end of both ducts as a result of a stop in their development before 8 days. Interestingly after 12 days, norethindrone causes regression of the upper part of the Mullerian duct particularly of the oviduct.

Wakamatsu *et al.* (2000) attributed the existence of persistent right oviduct in their study to the slow regression of right Mullerian duct during the embryonic stage and left-right asymmetry in female genital system which was intrinsic. The mutant trait is thought to be controlled by two pairs of autosomal recessive genes with major effects and numerous loci that have minor effects (Wakamatsu *et al.*, 2000). Therefore the expression of this trait is due to the interaction of major loci and the background genotype.

Cystic right oviducts vary in size from a small 2 cm diameter, elongated cysts to a large fluid-filled sac up to 10 cm or more in diameter (Riddell, 1997). Here, researchers report that the diameter of the sac is 12 cm. Large cysts compress the abdominal viscera and can result in a bird with a pendulous abdomen (Riddell, 1997). These may be responsible for the disproportional large abdomen seen in this case. The low levels of the urea from the chemical analysis of the cystic fluid may be attributed to the corresponding absence of protein in the cystic fluid analysis.

## CONCLUSION

To the knowledge, this is the first case study of congenital abnormalities of the atresia of the left oviduct, malformed caecum and hypoplastic right oviduct in ISA-Brown layer bird in Nigeria.

## REFERENCES

- Aitken, R.N.C. and H.S. Johnson, 1963. Observations in the fine structure of the infundibulum of the oviduct. *J. Anat.*, 97: 87-99.
- Doi, O. and J.M. Hutsen, 1988. Pretreatment of chick embryos with estrogen in ovo prevents Mullerian duct regression in organ culture. *Endocrinology*, 122: 2888-2891.
- Grunewal, P., 1942. Asymmetry of the growing mullerian ducts in the duct embryo. *J. Morphol.*, 11: 299-305.
- Hamilton, T.H., 1961. Studies on the physiology of urogenital differentiation of Mullerian ducts. *J. Exp. Zool.*, 146: 265-274.
- Hlozankova, E. and J. Zelenka, 1978. Right Mullerian duct in the domestic fowl during postnatal ontogenesis. *Anat. Anz.*, 144: 208-213.
- Hutson, J.M., H. Ikama and P.K. Donahoe, 1982. Estrogen inhibition of Mullerian inhibiting substance in the chick embryo. *J. Pediatr. Surg.*, 17: 953-959.
- Hutson, J.M., J.H. Ikawa and P.K. Donahoe, 1981. The ontogeny of Mullerian inhibiting substance in the gonads of the chicken. *J. Pediatr. Surg.*, 16: 822-827.

- Riddell, C., 1997. Developmental, Metabolic and other Non-infectious Diseases. In: Diseases of Poultry, Calnek, B.W., H.J. Barnes, C.W. Beard, L.R.R. McDougald and Y.M. Saif (Eds.). 10th Edn., Iowa State University Press, Ames, IA., USA., pp: 913-950.
- Romanoff, A.L., 1960. The Avian Embryo. MacMillian, New York.
- Stoll, R. and N. Faucounau, 1987. Deficiencies of the Mullerian ducts induced by norethindrone in the female chick embryo. C R. Seances. Soc. Biol. Fil., 181: 300-306.
- Teng, C.S., 1987. Quantification of Mullerian inhibiting substance in developing chick gonads by a competitive enzyme-linked immunosorbent assay. Dev. Biol., 123: 255-263.
- Wakamatsu, M., T. Yamagata, T. Namikawa and M. Mizutani, 2000. Hereditary persistent right oviduct in the chicken PNP/DO line. Poult. Sci., 79: 1075-1081.
- Yonju, H., T. Akira, S. Noboru and S. Kiyoshi, 2004. Changes in mRNA expression of the MMP-2 in the Mullerian duct of the chicken embryo. Gen. Comp. Endocrinol., 139: 131-136.