

Association of *Pseudomonas stutzeri* with An Infected Ruptured Pulmonary Hydatid Cyst in A Young Patient

¹Mohamed E. Ahmed and ²Imadeldin E. Aradaib

¹Department of Surgery, Faculty of Medicine, Alnilain University,
P. O. Box 12702 Khartoum , Sudan

²Molecular Biology Laboratory (MBL), Faculty of Veterinary Medicine,
University of Khartoum. P. O. Box 32, Khartoum North, Sudan

Abstract: A child was admitted to Elshab Medical Teaching Hospital, Khartoum, Sudan. The patient had a history of cough, chest pain for 2 months and breathlessness for 3 weeks. X-ray, Computed Tomography (CT) scan and Magnetic Resonance Image (MRI) revealed the presence of a large rounded homogenous well circumscribed nodular opacity in the right lung and hydrothorax in the left side of the chest. On thoracotomy, a ruptured hydatid cyst was found invaded by secondary bacterial infection leading to empyema of the left side of the chest. The infected ruptured hydatid cyst was removed and empyema was taken care of by enucleation of the cyst and decortication of the pleura and removal of the puss. The surgically removed cyst was submitted to the diagnostic laboratory for parasitological and microbiological examinations. Parasitological examination revealed the presence of a few number of protoscolices associated with the inner wall of the hydatid cyst. Conventional bacterial isolation and characterization revealed the presence of gram negative bacteria, which was further identified as *Pseudomonas stutzeri*. The antibiotic sensitivity test showed inhibitory zones of bacterial growth around a number of antibiotic discs with highest sensitivity being against tetracycline. To our knowledge, this is the first report on thoracic empyema caused by this organism in childhood in the Sudan.

Key words: *Pseudomonas stutzeri*, infected ruptured, Pulmonary Hydatid Cyst

INTRODUCTION

Hydatid disease or cystic echinococcosis caused by *Echinococcus granulosus* is a disease which affects man and animals and hence the disease is of public health importance^[1-3]. However, surgical interference is recommended when the cyst is interacting with the normal physiological function of the affected organ^[4]. Hydatid lung disease in the African continent is usually caused by *E. granulosus*^[5, 6]. Slowly enlarging *Echinococcus* cysts usually remain asymptomatic until their expanding size or their space occupying effect elicits symptoms^[4]. The cysts may be discovered as an incidental finding on a routine X-ray chest. Pulmonary hydatid cyst may rupture into pleural cavity, pericardium or the bronchial tree leading to cough, chest pain and haemoptysis. Hydatid disease is caused by the tapeworm *E. granulosus* and *E. multilocularis* but the later is not yet reported in Africa. Dogs are the usual primary host and different animal species including humans may serve as intermediate hosts. In the intestine of the intermediate host, the eggs hatch and the embryos cross the intestinal mucosa, enters into blood vessel and lymphatic system. Liver and lungs

together filters the majority of the embryos. Wherever the embryo settles, it forms a hydatid cyst. The cyst wall consists of two layers, the outer ectocyst and the inner endocyst. The endocyst is the vital layer of the cyst which is responsible for formation of brood capsule, protoscolices and the fluid inside the cyst. A granular deposit found to settle at the bottom of fluid is called hydatid sand, which is composed of brood capsules, free protoscolices and loose hook lets^[7]. In certain circumstances pulmonary hydatid cyst may rupture spontaneously or mechanically and became invaded by secondary bacterial infection leading to chest empyema. In the present report, we present an unusual case of an infected ruptured hydatid cyst localized at the lower lobe of the left lung of a child. The surgically removed cyst was submitted to the laboratory for further diagnostic investigation. The infection was reported to be due to *Pseudomonas stutzeri* as secondary bacterial invaders to the infected hydatid cyst.

CASE REPORT

A fourteen years old female presented with cough, chest pain and breathlessness was presented to

our surgical unit at Elshab Medical teaching Hospital, Khartoum, Sudan. She was treated with several antibiotics before she was referred to our hospital. On clinical examination, there was no cardiac or neurological deficit. There was no history of swelling of both lower limbs. X-ray, Computed Tomography (CT) scan and Magnetic Resonance Image (MRI) were recommended for the patient. Chest radiograph revealed the presence of a large rounded homogenous well circumscribed nodular opacity in the right lung and thoracic effusion in the left side of the chest. With these findings a tentative diagnosis of pulmonary hydatid cyst with metastatic pulmonary echinococcosis was diagnosed. She was planned for surgical removal of the cyst from the left side of the lower lobe of the lung.

MATERIALS AND METHODS

Infected material: The infected ruptured hydatid cyst was removed by surgical operation via thoracotomy. The infected cyst was transferred to a clean sterile vacutainer and submitted to the diagnostic laboratory for parasitological and microbiological examination.

Conventional isolation and identification: Microscopic examination of the pleural fluid showed polymorphonuclear leukocytes, but no organisms were detected with Gram stain. Culture of the pleural fluid revealed oxidase-positive and catalase-negative organism. Final identification of the microorganism was *P. stutzeri* by crystal system (Becton Dickinson, USA). *P. stutzeri* was susceptible to a number of antibiotics by disc diffusion method. The plates were incubated at 37 °C for three days and examined daily for inhibition of growth around antibiotic disc to determine the antibiotic with highest sensitivity for *P. stutzeri*.

RESULTS AND DISCUSSION

Parasitological examination revealed the presence of hydatid cyst. Confirmation of hydatid cyst was made possible by demonstration of a few protoscolices under the microscope. Conventional isolation and characterization revealed the presence of gram negative rods, which were further identified as *Pseudomonas stutzeri*. The antibiotic sensitivity test showed inhibitory zones of bacterial growth around a number of antibiotic discs with highest sensitivity being against tetracycline. In general, the treatment for hydatid cysts includes either chemotherapy or surgery. However, in certain circumstances both chemotherapy and surgery are recommended^[8]. Recently, World Health Organisation (WHO) has published guidelines for the treatment of hydatid cysts^[9]. Surgery remains the first choice for treatment for most cases, although chemotherapy with

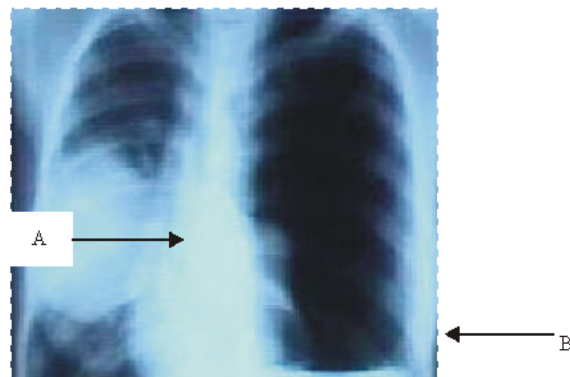


Fig. 1: Chest X-ray revealed the presence of (A) a large rounded homogenous well circumscribed nodular opacity in the right lung and (B) pleural effusion (infected chest fluid) in the left side of the chest resulting from infected ruptured hydatid cyst and empyema of the chest

benzimidazole compounds (albendazole or mebendazole) could also be recommended. In case of pulmonary hydatid cysts, the treatment should consist of excision of the cyst with maximum preservation of the pulmonary parenchyma. However, radical surgery may be required in transdiaphragmatic extension of hepatic hydatid cysts as they may rupture or result in destruction or infection of the adjacent tissue including the diaphragm and the chest^[10]. Albendazole (10-15 mg/kg/day in two divided doses) given at least four days before surgery softens the cysts and reduces intracystic pressure and thus facilitates removal of the hydatid cyst. In most cases, treatment is continued for one month post-operatively^[11].

Diagnosis becomes difficult once the pulmonary hydatid cyst ruptures spontaneously or following trauma and gets secondarily infected. In the present case, the hydatid cyst, located at the lower left lobe of the lung was ruptured mechanically by introduction of intercostals tube. The ruptured hydatid cyst became invaded by secondary bacterial infection that developed in thoracic empyema, which mandates surgery to remove the cyst and to take care of chest empyema (Fig. 1). A more common cause of empyema is the infection of pleural fluid as reported in our case. The infection could be due to introduction of contaminated intercostals tube. Rupture of hydatid cyst was reported in several studies^[12-14].

Infection of a ruptured cyst by secondary bacterial infection was also reported^[7]. In the present case, it is probably that *P. stutzeri* is normally found as a natural inhabitance of the upper respiratory tract^[15-17]. Under certain circumstances such as immns suppression, the bacteria could become associated with the lungs thus resulting in an opportunistic infection with subsequent

development of empyema^[18-21]. It is well documented that younger patients particularly, children are more susceptible to develop complications from ruptured hydatid cysts. This could be attributed to the fact that children develop very large cysts due to greater elasticity of the lung tissue. Thus, spontaneous cyst rupture is likely to occur in younger patients rather than in older ones. It is worth mentioning that, this case demonstrated the importance of an early diagnosis of cystic hydatidosis in children. Contact with dogs in patients who develop respiratory complaints spontaneously or following mechanical trauma to chest should be considered. Such patients should be investigated on the lines of pulmonary hydatid cyst so as to avoid unnecessary delay in the diagnosis. An early diagnosis should facilitate the avoidance of mechanical or spontaneous rupture which leads to chest empyema. Albendazole at a dose rate of 7.5 mg Kg⁻¹ body weight twice daily, as an anticestodal drug, was prescribed for the patient postoperatively to prevent formation of daughter hydatid cysts. The treatment course was prescribed for a period of one month. According to antibiotic sensitivity test, oral tetracycline hydrochloride at a dose rate of 500 mg was prescribed three times a day for one week to treat the chest empyema caused by invasion of *P. stutzeri* to the ruptured hydatid cyst.

The patient showed dramatic improvement for normal respiration following surgical operation via thoracotomy and medicinal treatment with tetracycline and albendazole compound. To the best of our knowledge, this is the first report of parasitic pneumonia and chest empyema caused by *P. stutzeri* in a child in Sudan.

REFERENCES

1. Andre, L. L., H.C. Brain and J. G. Cameron, 1993. Giant hydatid lung cysts in the Canadian Northwest: Outcome of conservative treatment in three children. *J.Pediatrics Surgery*, 28: 1140-1143.
2. Dogan, R. and M. Yuksel, C. Guven, 1989. Surgical treatment of hydatid cysts of the lung. Report of 1055 patients. *Thorax.*, 44: 192-99.
3. Mohammed, A.A. and Khitma H.ElMalik, 2000. The Epidemiology of Cystic Echinococcosis in Nyala, Southern Darfur State, Sudan, *The Sudan J. Vet. Res.*, 16: 49-53.
4. Novick, R.J., C.I. Tchervenkov and J.A. Wilson, *et al.*, 1987. Surgery for thoracic hydatid disease. North American experience. *Ann Thorax. Surg.*, 43: 681-86.
5. Saad, M.B. and M. Magzoub, 1986. Echinococcus granulosus infection in dogs in Tamboul, Sudan, *J. Helminthol.*, 60: 299-300.
6. Saad M.B. and M. Magzoub 1988. Experimental transmission of hydatid infection from camels and cattle to dogs, *Ann Trop Med Parasitol.*, 82: 363-365.
7. Mohapatra, M., Sahoo, S.C Pattnaik, S. Sahoo, M.R. Pattnaik and S. Beheraz, 2003. Imaging Of Ruptured Cardiac Hydatid Cyst Located On The Interventricular Septum With Pulmonary Embolism, A Case Report. *Ind. J. Radiol. Imag.*, 13:2:203-205
8. Zhongxi, Q., 1988. Thoracic hydatid cysts. A report of 842 cases treated over a thirty year period. *Thorac. Surg.*, 46: 342-346.
9. WHO, 1996. Informal Working Group on Echinococcosis. Guidelines for treatment of cystic and alveolar echinococcosis in humans. *Bull World Health Org.*, 74: 231-242.
10. Von Sinner, W., 1997. Advanced medical imaging and treatment of human cystic echinococcosis. *Semin Roentgenol.*, 32: 276-290.
11. Yalcinkaya, C., M. Er, B. Ozbay and S. Ugrae, 1999. Surgical treatment of hydatid cyst of the lung : Review of 30 cases. *Eur. Respir. J.*, 13: 441-444.
12. Von Sinner, W.N., L. Strak, D. Clark and H. Sharif, 1991. MR finding in hydatid disease. *AJR.*, 157: 741-745.
13. Borrie, J. and J.H.F. Shaw, 1981. Hepatobronchial fistula caused by hydatid disease. *Thorax.*, 36: 25-28.
14. Von Sinner, W.N. 1991. New diagnostic signs in hydatid disease, radiography, ultrasound, CT and MRI correlated to pathology. *Eur. J. Radiol.*, 12: 150-159.
15. Gilardi, G.L., 1972. Infrequently encountered Pseudomonas species causing infection in humans. *Ann. Intl. Med.*, 77: 211-215.
16. Noble, R.C. and S.B. Overman, 1994. Pseudomonas stutzeri infection. A review of hospital isolates and a review of the literature. *Diagn. Microbiol. Infect. Dis.*, 19: 51-56.
17. Rowley, A.H., L.D. Dias, E.G. Chadwick and S.T. Shulman, 1987. Pseudomonas stutzeri: an unusual cause of calcaneal Pseudomonas osteomyelitis. *Pediatr. Infect. Dis. J.*, 6: 296-297.
18. Potvliege, C., J. Jonckheer, C. Lenclud and W. Hansen, 1987. Pseudomonas stutzeri pneumonia and septicemia in a patient with multiple myeloma. *J. Clin. Microbiol.*, 25: 458-459.
19. Carratala, J., A. Salazar, J. Mascaro and M. Santin, 1992. Communityacquired pneumonia due to Pseudomonas stutzeri. *Clin. Infect. Dis.*, 14: 792.
20. Campos-Herrero M.I., A. Bordes, H. Rodriguez, A. Perera, B. Gonzalez and A. Conde, 1997. Pseudomonas stutzeri community-acquired pneumonia associated with empyema: case report and review. *Clin. Infect. Dis.*, 25: 325-326.